

TITLE: DO PULMONARY ARTERY CATHETERS CAUSE INTERNAL JUGULAR VEIN THROMBOSIS?

AUTHORS: J. H. Elinger, M.D., R. F. Bedford, M.D., A. J. Buschi, M.D.

AFFILIATION: Departments of Anesthesiology and Radiology, University of Virginia Medical Center, Charlottesville, VA 22908

Introduction. The internal jugular route has become the preferred technique for intraoperative central venous catheterization because of its ease and apparent safety. However, a recent report has suggested that as many as 66% of patients with Swan-Ganz pulmonary artery catheters (PAC's) placed via the internal jugular route will develop venous thrombosis.¹ While jugular venous thrombosis could potentially lead to complications such as pulmonary embolus, septic phlebitis and superior vena cava syndrome, clinical reports of complications associated with PAC's are rare.² This study was performed to: 1) reassess the frequency of internal jugular vein thrombosis associated with PAC's, 2) obtain an estimate of the size of these thrombi, and 3) quantify the size of the vessel lumen relative to the catheters.

Methods. Twenty patients with No. 7 French pulmonary artery catheters placed for monitoring during cardiovascular surgery were studied after obtaining their consent. The ipsilateral and contralateral internal jugular veins were evaluated postoperatively in the ICU by ultrasound imaging while the PAC was in place. The examination was repeated between 8 hrs and 3 days after PAC removal. During each examination the largest diameter of the internal jugular vein was measured, and the lumen was evaluated for the presence of thrombus. If thrombus was found, an attempt was made to qualitatively assess the degree of venous obstruction caused by the clot.

Results. In the 20 patients studied, there were no definite thrombi seen, either while the catheter was in place or after its removal. In 3 of the patients, sonograms performed after removal of the PAC were possibly consistent with a small clot or valve. No similar lesion was found in the contralateral vessels. In no case did this lesion occupy a significant portion of the vessel lumen, and there were no clinically detected complications referable to PAC's.

Studies performed while PAC's were *in situ* revealed all internal jugular veins to be widely patent (Figure 1). The right internal jugular diameter was found to be 15 ± 5 mm.

Discussion. Consistent with our clinical impression that thrombotic complications associated with PAC's are extremely rare, this study did not find any definite instance of internal vein thrombosis, nor does the PAC itself appear to compromise flow through the vein. Obstruction of the internal jugular vein such as by a thrombus or catheter could potentially increase intracranial pressure in patients with decreased intracranial compliance, and jugular venous thrombosis has been implicated as a cause of communicating hydrocephalus in neonates.³

The diameter of a No. 7 French PAC is 3.0 mm. Compared to the diameter of the right internal jugular vein, the PAC occupies a very small proportion of the venous lumen. Hence, the catheter itself does not cause significant obstruction of venous blood flow.

This study found no instance of obvious thrombus formation. While this finding is compatible with the low incidence of clinical complications associated with PAC's, it is markedly different from the results recently reported.¹ Whether this difference is due to a difference in technique of placement or due to differences in detection technique remains to be determined. The results of this study indicate that the risk of venous obstruction either by thrombosis or by PAC's appears to be very low. Confirmatory studies need to be performed and are currently underway.

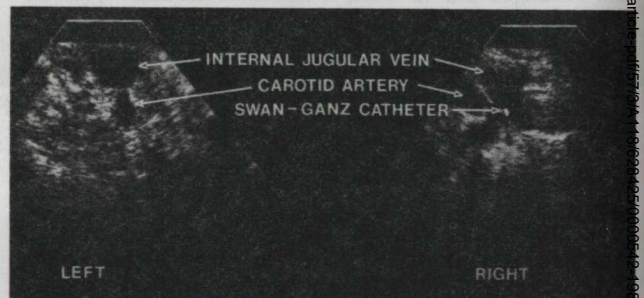


Figure 1. Ultrasound images of the right internal jugular vein cannulated with a PAC and the contralateral non-cannulated internal jugular vein.

References.

1. Chastre J, Cornud F, Bouchama A, Viau F, Benacerraf R, Gibert C: Thrombosis as a complication of pulmonary artery catheterization via the internal jugular vein. *New Engl J Med* 306:278-281, 1982
2. Sise MJ, Hollingsworth P, Brimm JE, Peters RM, Virgilio RW, Shackford SR: Complications of the flow-directed pulmonary artery catheter. *Crit Care Med* 9:315-318, 1981
3. Steward D, Johnson D, Myers G: Hydrocephalus as a complication of jugular catheterization during total parenteral nutrition. *J Ped Surg* 10:771-777, 1975