

Title: HEPATIC INJURY IN RATS DUE TO SUB-ACUTE HALOTHANE EXPOSURE

Authors: J.L. Plummer, PhD, P. de la M. Hall, FRCPA, F.N. Bastin, BSc(Hons), A.H. Ilsley, PhD, and M.J. Cousins, MD.

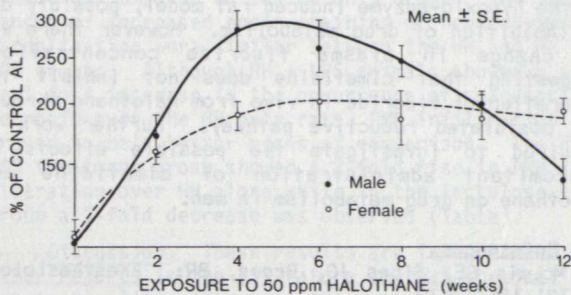
Affiliation: Departments of Anaesthesia and Intensive Care, and Histopathology, Flinders Medical Centre, and The Flinders University of South Australia, Adelaide 5042, Australia.

Introduction: Although several cases of hepatitis have been reported in individuals occupationally exposed to low levels of halothane in operating theatres, laboratories or during the manufacture of halothane^{1,2,3,4}, studies in rats have not demonstrated pathological changes characteristic of severe toxic liver injury. The present study was designed to assess hepatic effects of sub-acute exposure of Fischer 344 rats to halothane. Because there is a sex difference in hepatotoxic effects of halothane in humans¹, animals of both sexes were included in this study.

Methods: Six male and six female 6-7 week old Fischer 344 rats were acclimatised in each of 2 glass chambers (volume 2m³) for 12 days, after which halothane vapor was delivered to one chamber at a rate sufficient to keep the concentration in the chamber at 50 ppm. Rats were weighed and blood samples taken at 2 week intervals. One female rat in the halothane-exposed group died of causes unrelated to halothane exposure. After 12 weeks of essentially continuous (164 hr/week) exposure, animals were killed, the liver was weighed and liver tissue was fixed in formalin for histological assessment. Logarithms of serum alanine aminotransferase (ALT) activities, and weight gains over each 2 week period, were analysed in a 3 factor (sex, treatment, duration of exposure) design with repeated measures. Differences in response of the sexes to halothane were assessed by testing the significance of the sex X treatment interaction, or of the simple sex X treatment interactions if the three way interaction was significant.

Results: Over the 12 week exposure, halothane concentration averaged 50.1 ± 3.0 ppm (mean ± S.D.). **Body Weight Changes:** Halothane exposure depressed weight gain in both male and female rats (p < 0.001). The response of the sexes in this respect did not differ significantly. **Serum ALT Activity:** Serum ALT activities of both male and female rats were elevated by halothane exposure (p < 0.001).

Trend analysis of serum ALT elevation (defined as log (ALT halothane group)-log (ALT control group)) over weeks 2-12 showed a significant (p < 0.001) quadratic trend for male rats, indicating that elevation of ALT activity reached a maximum (at weeks 4-6) and then declined. Female rat ALT activity showed no such trend (p > 0.25), reaching maximal elevation after 2 weeks of exposure, and not changing significantly over the next 10 weeks (Figure).



Changes in serum ALT during halothane exposure. % of control values are plotted on a log scale.

Liver Weight: Liver/body weight ratio was significantly increased from control by halothane in both males and females (p < 0.001). Absolute liver weight was increased in males (p < 0.01) but not in females (p > 0.1) (Table).

Sex		Liver Weight	
		(g)*	% of body weight*
Female	Control (n=6)	6.28 ± 0.63	3.08 ± 0.18
	Halothane (n=5)	6.82 ± 0.27	4.05 ± 0.19†
Male	Control (n=6)	10.72 ± 0.89	3.25 ± 0.22
	Halothane (n=6)	12.15 ± 0.70†	3.99 ± 0.19†

* Mean ± SD † Significantly different from controls p < 0.05

Liver Pathology: There was no evidence of hepatocyte damage or regeneration in any of the liver sections from control animals of either sex. Liver sections from all halothane-exposed animal showed evidence of hepatocellular damage. Cells showing acidophilic necrosis were seen close to the central veins and scattered throughout the liver lobules. Fatty change was present in all region of the liver but was most marked in the mid-regions of the lobules (Zone 2). There were frequent mitoses throughout the lobules and considerable lobular disarray, in keeping with recent liver cell necrosis and regeneration. Foci of lymphocytes were present next to many central veins and also scattered throughout the liver lobules. There was no apparent difference in severity of liver damage between the sexes.

Discussion: Earlier studies in rats have reported liver changes resulting from sub-anaesthetic halothane exposure but it is not clear whether hepatocyte necrosis occurred. The high incidence of damage described here may be due to the greater susceptibility of the strain of rat used⁵.

This study was supported by grants from the National Health and Medical Research Council of Australia and The Faculty of Anaesthetists, Royal Australasian College of Surgeons.

References:

1. Touloukian J, and Kaplowitz N. Halothane-induced hepatic disease. *Seminars in Liver Disease*, 1: 134-142, 1981.
2. Klatskin G, and Kimberg DV. Recurrent hepatitis attributable to halothane sensitization in an anaesthetist. *New Engl J Med*, 280: 515-522, 1969.
3. Johnston CI, and Mendelsohn F. Halothane hepatitis in a laboratory technician. *Aust NZ J Med*, 2: 171-173, 1971.
4. Neuberger J, Vergani D, Mieli-Vergani G, Davis M, and Williams, R. Hepatic damage after exposure to halothane in medical personnel. *Br J Anaesth*, 53: 1173-1177, 1981.
5. Gourlay GK, Adams JF, Cousins MJ, and Hall P. Genetic differences in reductive metabolism and hepatotoxicity of halothane in three rat strains. *Anesthesiology*, 55: 96-103, 1981.