

Anesthesiology
57:323-324, 1982

Endotracheal Balloon Cuff Dilatation of Tracheostomal Stenosis

PHILIP W. LEBOWITZ, M.D.,* ERAN GELLER, M.D.,† STEVEN K. ANDEWEG, M.D.‡

The obligatory creation of a permanent end-tracheostomy following total laryngectomy interferes with normal mechanisms of humidifying, heating, and filtering inhaled gases, but does provide anesthesiologists with easy access to the airway. Despite this accessibility, placement of an adequately sized endotracheal tube or tracheostomy tube may be limited by stenosis of the tracheostoma. We used a novel method of tracheostomal dilatation which allowed the use of a Robertshaw double-lumen endotracheal tube to provide one-lung anesthesia for a pulmonary resection.

REPORT OF A CASE

Two months previously, a 54-year-old, 52-kg man had undergone total laryngectomy and right radical neck dissection for squamous cell carcinoma of the epiglottis, aryepiglottic folds, right pyriform sinus, and both valleculae. He had subsequently received approximately 4,000 rads of radiation therapy to the region (the last treatment two weeks previously) and two cycles of cis-platinum, vincristine, and bleomycin. Although a chronic smoker, he had no breathing difficulty, except on marked exertion. Measured FEV₁ was 1.97 l and forced vital capacity was 2.46 l; at a FI_{O₂} of 0.21, PaO₂ was 94 mmHg, PaCO₂ 42 mmHg, and pH_a 7.41. The only exceptional findings on physical examination were an encrusted 6 mm × 7 mm end-tracheostomy stoma with an inferior lip, surrounded by reddened, thickened, edematous skin. Chest roentgenography revealed a left upper lobe mass for which bronchoscopy and left upper lobectomy were proposed.

After 5 mg morphine, im, and 0.2 mg scopolamine im, 100 µg fentanyl, iv, was given followed by lidocaine 5% ointment applied topically to the tracheostoma (removing encrustations in the process) and lidocaine 4% solution sprayed into the trachea. Attempted placement of a #38 F Tovell (silicone rubber, spiral wire-reinforced) endotracheal tube encountered firm resistance and was abandoned in favor of progressively smaller diameter tubes. A lidocaine ointment-lubricated #28 F Tovell tube was eventually insinuated into the trachea, the balloon cuff placed at the cutaneous level of the tracheostoma. At this point, anesthesia was induced with 275 mg thiopental, iv, and maintained with halothane one per cent inspired through the endotracheal tube.

The balloon cuff was then inflated with 5 ml of air, thereby concentrically dilating the stoma (see fig. 1). A lubricated #30 F Tovell tube was substituted under yielding pressure and the cuff again inflated.

The procedure was repeated successively using #32 F, #34 F, #36 F, and #38 F Tovell endotracheal tubes, as the patient continued to inhale halothane and O₂. Following fiberoptic bronchoscopy through the #38 F tube, a lubricated right medium Robertshaw double-lumen endotracheal tube (approximately #39 F) was easily introduced in a similar fashion and positioned properly. No bleeding, fissuring, or tracheal injury occurred at any time. The remainder of the anesthetic management for the left upper lobectomy was uneventful. The trachea was extubated at the end of surgery without difficulty. Subsequent otorhinolaryngologic consultation advised humidification of inspired gases, placement of a tracheostomy appliance to prevent further stomal narrowing, and possible surgical correction at a later date.

DISCUSSION

Various explanations have been proposed to account for the development of tracheostomal stenosis following laryngectomy.¹⁻³ In addition to excessive scar formation (usually as a result of local infection), technical errors such as allowing excessive fat and skin to remain around

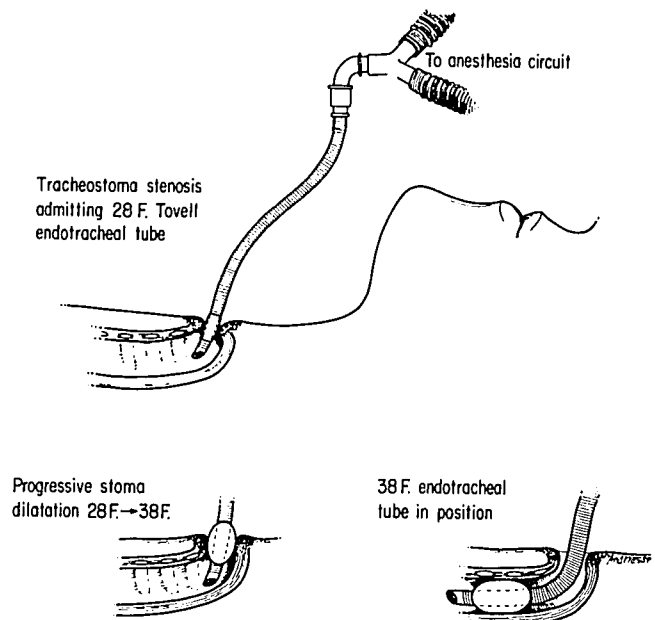


FIG. 1. Progressive dilatation of a stenotic tracheostoma by introduction of a small-caliber Tovell endotracheal tube, coaxial expansion of its balloon cuff, and subsequent insertion of a larger-diameter Tovell tube, successively repeating the process. The effectiveness of the maneuver is demonstrated by the eventual intubation of the trachea with a 38 F Tovell tube. Although not illustrated, dilatation proceeded to allow the insertion and proper positioning of a medium Robertshaw endotracheal tube.

* Assistant Professor of Anaesthesia.

† Instructor in Anaesthesia.

‡ Clinical Fellow in Anaesthesia.

Received from the Anesthesia Services of the Massachusetts General Hospital, and the Department of Anaesthesia, Harvard Medical School, Boston, Massachusetts. Accepted for publication April 6, 1982.

Address reprint requests to Dr. Lebowitz: Department of Anesthesia, Massachusetts General Hospital, Boston, Massachusetts 02114.

Key words: Surgery: tracheostomy. Complications: tracheostomal stenosis; dilatation. Equipment: tubes; tracheostomy.

the stoma, using too large a tracheostomy tube initially, keeping the tracheostomy tube in place longer than one week, insufficient anchoring of the trachea to the skin (so that raw areas between the skin and the tracheal mucosa retract downward and scar subcutaneously), as well as the presence of defective or absent tracheal rings, recurrent tumor, and perhaps radiation therapy, may all contribute to stomal narrowing. Inadequate humidification and poor stomal care allow crusting to develop, which further impinges upon the opening. Three types of tracheostomal stenoses have been described: vertical slit, concentric, and inferior shelf.^{2,4} Specific methods of surgical correction have been devised for each, with local anesthesia usually suggested.

Temporary improvement may be accomplished by dilating a stenotic tracheostoma with Teflon® bougies.³ The use of successively larger diameter endotracheal tubes serves the same function, but offers two advantages. First, the capacity of the endotracheal tube cuff balloon to expand (and dilate coaxially) beyond the external dimension of the endotracheal tube itself allows a degree of dilatation, which a non-expansile dilator of the same initial diameter could not match. As a result, this new method should produce its desired effect with little tissue trauma, much in the manner of balloon angioplasty for non-surgical correction of certain arterial stenoses.⁵ Second, the use of endotracheal tubes to accomplish the dilatation enables the patient to be given inhalational anesthesia and oxygen during the procedure. The pre-

vention of arterial hypoxemia may, in fact, be the most important reason for choosing this technique. In this particular case, enlarging the stoma was required in order to place a Robertshaw endotracheal tube via the tracheostomy, which usually can be performed without difficulty.^{6,7}

Clearly, temporary enlargement of a narrowed tracheostoma by compression remodeling of the skin and subcutaneous tissues may be accomplished with endotracheal tube balloon dilatation. That this maneuver will prove successful in treating tracheostomal stenosis without eventually resorting to surgical correction should not necessarily be assumed.

REFERENCES

1. Converse JM: An operation for relief of stenosis of the stoma following total laryngectomy. *Arch Otolaryngol* 52:950-951, 1950
2. Montgomery WW: Stenosis of tracheostoma. *Arch Otolaryngol* 75:62-65, 1962
3. Harpman JA: Post-tracheostomy tracheal stenosis. *The Eye, Ear, Nose and Throat Monthly* 50:161-164, 1971
4. Montgomery WW: *Surgery of the Upper Respiratory System*. Philadelphia, Lea and Febiger, 1973, pp 359-368
5. Dotter CT: *Transluminal angioplasty, Angiography*. Edited by Abrams HL. Boston, Little, Brown and Company, 1971, pp 1287-1297
6. Simpson PM: Tracheal intubation with a Robertshaw tube via a tracheostomy. *Br J Anaesth* 48:373-375, 1976
7. Seed RF, Wedley JR: Letter: Tracheal intubation with a Robertshaw tube via a tracheostomy. *Br J Anaesth* 49:639, 1977