

of general anesthesia is a mechanical failure on the low pressure side of the machine which causes delivery of an uncontrolled, hypoxic or unknown mixture to the patient. Implicated in the past in this potential catastrophe have been damaged needle valves,² cracked flow columns,³ dirty or poorly maintained flow columns causing sticking of the floating indicators,⁴ and incorrect substitution of flow columns.⁵

Manufacturers specification on the M.D.M. indicate that at normal gas delivery pressures of greater than 40 lbs per square inch for oxygen and nitrous oxide, the total flow control delivers flows of up to 20 l/min accurately. With the knob stopped down clockwise (reference point is facing the anesthesia machine), the nut seen in figure 2 is backed away from the diaphragm as far as possible and is in fact engaging at most two threads on the shaft. This is the point of minimum spring tension and the diaphragm position allows no gas flow. As the knob is rotated counterclockwise, the nut which can move in and out but not rotate in the housing surrounding it, rides down the shaft increasing spring tension. This in turn pushes on the diaphragm and increase in gas flow is proportional to this tension. Difficulty with this system can occur if the knob, in turning off flow, is forced beyond its natural stopping point, placing great stress on the last threads of the nut and the shaft. The original nut is brass and the shaft threads are stainless steel. Over time, the weaker nut thread breaks down under the constant spring tension. When it does so, this functionally disconnects the shaft from the nut, which is pushed off the shaft by

the spring. Once the nut is pushed off the shaft by the spring, the spring is in its most relaxed position, the diaphragm is unpressurized and flow ceases. Turning the knob will not now cause any gas to flow. The solution to the problem, which repaired the machine and a second similar one which had not yet failed, was the fabrication and placement of a German Silver nut to replace the brass nut. Both machines have since been in use for hundreds of hours without any problems in the low-pressure circuits.

In summary a case is presented in which a mechanical breakdown in an unusual gas flow control, the M.D.M. of the Fraser-Sweatman Company, malfunctioned in such a manner as to stop all fresh gas flow during a general anesthetic. A description is given of the cause of the malfunction as well as the change necessary to prevent a recurrence of the same incident.

REFERENCES

1. Hamelberg W, Maffey JS, Bond WE: Nitrous oxide impurities. *Anesth Analg (Cleve)* 40:408-411, 1961
2. Kopriva CJ, Lowenstein E: An anesthetic accident: Cardiovascular collapse from liquid halothane delivery. *ANESTHESIOLOGY* 30:246-247, 1969
3. Bishop C, Levick CH, Hodgson C: A design fault in the Boyle apparatus. *Br J Anaesth* 39:908, 1967
4. Mazzia VDB, Mark LC, Brinder LS, Crawford EJ, Gade H, Henry EL, Marx GF, Schrier RI: Oxygen and the anesthesia machine. *NY State J Med* 62:2845-2846, 1962
5. Dorsch JA, Dorsch SE: *Understanding Anesthesia Equipment*. Baltimore, The William and Wilke Company, 1975, pp 44-46

Anesthesiology
57:330-332, 1982

A Simple Device for the Identification of the Epidural Space

KAMIL MUSTAFA, M.D., F.F.A.R.C.S.,* AND RALPH A. MILLIKEN, M.D., M.B.A.†

Epidural block is a useful technique which is associated with the hazard of an inadvertent dural puncture that may result in unpleasant and possibly serious complications.¹

We describe an indicator which, in our experience,

has proven reliable when attempting to identify the epidural space. This indicator has the additional advantage of being readily available in the operating room in a sterile and disposable form. No special preparation, sterilization or supply problems are involved.

MATERIALS AND METHODS

The indicator is simply a segment of the standard clear plastic intravenous extension tubing. The extension tubing is cut at a distance of approximately six inches from the male leur end. The cut segment is filled with about one ml of the epidural anesthetic solution. The indicator

* Assistant Professor.

† Adjunct Associate Professor.

Received from the Department of Anesthesiology, New York Medical College, 234 East 149th Street, Bronx, New York 10451. Accepted for publication April 20, 1982.

Address reprint requests to Dr. Mustafa.

Key words: Anesthetic techniques: epidural.

is gently shaken to dissolve the solution column into droplets, interspersed with air bubbles (fig. 1). The male adaptor is then connected to the hub of the epidural needle after the tip of the needle is already placed in the interspinous ligament. The needle is then advanced toward the ligamentum flavum. The entry of the needle point into the epidural interval is signalled by abrupt movement of the air bubbles and droplets towards the hub of the needle. In addition, the entire column of liquid and air will then begin to show fine oscillations, which are synchronized with the patient's heart beat. These oscillations constitute an important confirmatory sign of accurate identification of the epidural space. In the conventional hanging drop technique, the presence of cardiac pulsations transmitted to the drop is regarded as an ancillary sign of true identification of epidural space.² Sometimes, movement of greater amplitude coincident with respiratory activity are seen.

Once the epidural space is entered, the indicator is disconnected. A 5-ml, air-filled glass syringe is attached to elicit the loss of resistance sign to further establish the correct placement of the needle point. Before the administration of the anesthetic solution, aspiration is performed to rule out any possibility of inadvertent puncture of the dura or a vein. Successful entry into the epidural space is determined clinically by the ease of injection of the anesthetic solution through the needle and catheter, and subsequent onset of satisfactory surgical analgesia.

We have used this indicator successfully in 500 cases during a period of 36 months, for the performance of lumbar epidural block. The procedures were carried out both by the attending staff and residents in training, under the supervision of attending anesthesiologists.

RESULTS

Our patients ranged in age from 19 to 95 years (mean 57.9 ± 19.56 years), and their body weights from 50 to 170 kg (mean 71.95 ± 17.37 kg). Epidural puncture was accomplished at first attempt in 487 patients. In 13 cases, a second attempt was made at the adjacent interspinous space in the lumbar region with successful outcome. There was no incident of dural puncture in this series.

DISCUSSION

Janzen³ accidentally discovered the presence of negative pressure in the epidural space in 1926, while taking manometric measurements of cerebrospinal fluid pressure. Since then, numerous theories have been advanced to explain the phenomenon.⁴ Lack of agreement regarding the genesis of the negative pressure in the epidural space probably centers around the varied techniques used to study this phenomenon.

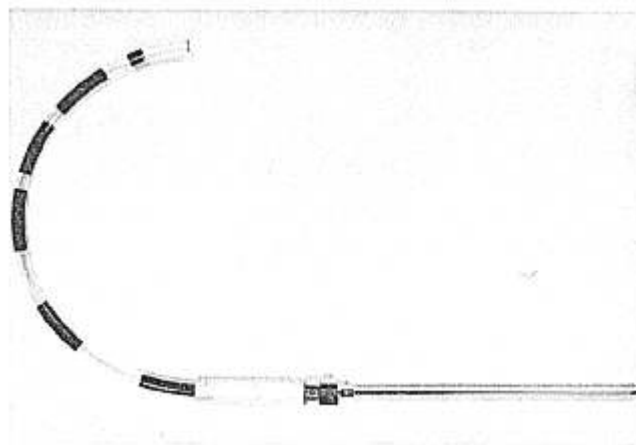


FIG. 1. Epidural space indicator consisting of a six-inch long segment of intravenous extension tubing attached to the epidural needle. (Dye has been added to the solution for pictorial contrast purpose only.)

Most anesthesiologists probably rely on the "Hanging-Drop Sign" of Gutierrez,⁵ and the "Loss of Resistance" test of Dogliotti.⁶ However, both of these approaches have their own limitations. A positive hanging-drop sign may not be an infallible index of correct extradural location, as it may arise falsely. In fact, a spurious negative pressure sign is relatively frequent.² This negative sign may be due to muscular movements associated with inspiration or with the rotation of the spine; the advancing needle sometimes enters a fascial plane where a small pocket of negative pressure appears briefly as the muscle groups slide one upon the other. One difficulty we have encountered with the hanging drop sign is that the drop precariously hanging from the hub restricts a thorough grasp of the hub, and thus makes advancement difficult.

The problem with the loss-of-resistance test is that in elderly patients with practically ossified ligaments, the onward movement of the needle may not be checked in time. Consequently, the rate of dural puncture is doubled in elderly patients as compared to younger patients.¹ Further, a freely moving plunger is essential to this maneuver. If the syringe is sticky, the loss of resistance in the tissues will be masked by the intrinsic resistance of the syringe and a dural puncture will be more likely. Finally, if the needle deviates from the midline and enters the lumbar muscles, a false loss of resistance will be obtained and the solution will be deposited outside the epidural space.⁷

The incidence of dural puncture reported in one series of 3,637 cases was 2.2 per cent.⁸ In another report based on the scrutiny of the world literature,¹ inadvertent dural puncture occurred in 2.9 per cent in 30,088 cases, where loss of resistance technique was followed; with the use of a visual indicator, however, the incidence fell to 1.6

per cent in 13,062 cases. In a series of 4,000 blocks compiled by Dawkins over a period of 25 years,⁹ the dural puncture occurred in 7.5 per cent in 210 cases in which loss of resistance method for the identification of epidural space was used.

We conclude that this new device for the identification of epidural space is simple, dependable, inexpensive, and readily available in the operating room in a sterile, disposable form. We have been able to achieve accurate location of the epidural space in 500 cases; on the first attempt in 487 cases and on the second attempt in the adjacent lumbar interspinous space in 13 cases. There has been no incident of inadvertent dural puncture. The "end-point" of entry of the needle in the epidural space is unmistakably evident both in the form of movement of the dispersed bubbles and droplets and the oscillations of the column.

Anesthesiology
57:332-334, 1982

Visual Disturbances: An Unusual Symptom of Transurethral Prostatic Resection Reaction

ANDRANIK OVASSAPIAN, M.D.,* C. W. JOSHI, M.B.B.S.,† EDWARD A. BRUNNER, M.D., PH.D.‡

Visual disturbances such as blurred vision,¹⁻³ transient blindness,²⁻⁵ and pupillary dilatation^{3,6} have been reported with the transurethral resection reaction syndrome. These visual disturbances have been attributed to cerebral edema^{2,4} and atropine injection during the operation.³

We describe our experience in five patients who developed visual complication during transurethral resection of prostate (TURP) and propose that glycine from the surgical irrigating fluid was the cause.

* Associate Professor of Clinical Anesthesia, Northwestern University School of Medicine, and Chief, Anesthesia Service, V.A. Lakeside Medical Center.

† Assistant Professor of Clinical Anesthesia, Northwestern University School of Medicine, and Medical Director, Respiratory Therapy Section, Anesthesia Service, V.A. Lakeside Medical Center.

‡ Professor and Chairman, Department of Anesthesia Northwestern University School of Medicine.

Received from the Department of Anesthesia, Northwestern University School of Medicine, and the Anesthesia Service, V.A. Lakeside Medical Center, Chicago, Illinois. Accepted for publication May 3, 1982.

Address reprint requests to Dr. Ovassapian: V.A. Lakeside Medical Center, Anesthesia Service, 333 E. Huron Street, Chicago, Illinois 60611.

Key words: Eyes: visual disturbances. Surgery: urologic. Anesthetic technique: spinal.

REFERENCES

1. Dawkins CJM: The identification of epidural space: a critical analysis of various methods employed. *Anaesthesia* 18:66-77, 1963
2. Bromage PR: *Epidural Analgesia*. Philadelphia, WB Saunders Co., 1978, pp 188-189
3. Janzen E: Der negative vorschlag bei lumbalpunktion. *Deutsche Zeitschrift für Nervenheilkund* 94:280-293, 1926
4. Lund PC: *Peridural Analgesia and Anesthesia*. Springfield, Charles C. Thomas, 1966, pp 22-27
5. Gutierrez A: *Anesthesia Metamerica Epidural*. *Rev Cir Buenos Aires* 11:665-685, 1932
6. Dogliotti AM: *Anesthesia, Narcosis, Local, Regional, Spinal*. Chicago, SB Debour, 1933, pp 521-566
7. Wylie WD, Churchill-Davidson HC: *A Practice of Anaesthesia*. Chicago, Year Book Medical Publishers, Inc., 1978, p 1167
8. Bonica JJ, Backup PH, Anderson CE, Hadfield D, Crepps WF, Monk BF: *Peridural block: analysis of 3,637 cases and a review*. *ANESTHESIOLOGY* 18:723-784, 1957
9. Dawkins CJM: An analysis of complications of extradural and caudal block. *Anaesthesia* 24:554-563, 1969

REPORT OF FIVE CASES

Clinical data on each case are summarized in table 1. All resections of the prostate were conducted under spinal anesthesia using 1.5 per cent glycine as irrigating fluid.

Patient 1. A 56-year-old man in good health and with normal laboratory findings had a decrease in heart rate of 100/min to 65/min and developed blurred vision 90 min after the beginning of the TURP. Shortly thereafter he complained of visual halos and blue visual hue. Prostatic resection was complicated by both arterial and venous bleeding, with estimated blood loss of 700 ml. In the recovery room he was awake and oriented but complained of inability to see anything, and had a headache, nausea, tingling, and numbness of both upper extremities. His vision was limited to light perception only, and both pupils were dilated with no reaction to light stimuli. Intravenous crystalloid administration was restricted and 20 mg furosemide was administered iv. A neurologist's evaluation at this time revealed no abnormalities except for the visual changes described above. There was no papilledema. Two and a half hours after admission to the recovery room, he still had tingling and numbness of both hands but vision had improved. Eye examination by an ophthalmologist at this time revealed 20/100 vision, intraocular tension of 15 mm, and dilated pupils that were nonreactive to light. Extraocular muscle movement and fundus examination of the eyes were normal. No definite diagnosis could be established by either the neurologist or ophthalmologist. Thirteen hours after completion of surgery, numbness and tingling of upper extremities had stopped. His vision returned to 20/20, 48 hours later.

Patient 2. An 86-year-old man with treated glaucoma and visual acuity of OD 20/60, OS finger count at two feet, had uneventful TURP until he complained that all he could see was a little light when the room lights were turned on at the end of surgery. He was alert and oriented but could not see objects and stared ahead. Examination by