

12. Doctor NH, Hussian Z: Bilateral pneumothorax associated with laparoscopy. *Anaesthesia* 28:75-81, 1973
13. Seed RF, Shakespeare TF, Muldoon MJ: Carbon dioxide homeostasis during anesthesia for laparoscopy. *Anaesthesia* 25:223-231, 1970
14. McKenzie R: Laparoscopy. *NZ Med J* 74:87-91, 1971
15. Kleppinger RK: One thousand laparoscopies of a community hospital. *J Reprod Med* 13:13-20, 1974
16. Graff TD, Arbogast NR, Phillips OC, Harris LC, Frazier TM: Gas embolism: A comparative study of air and carbon dioxide as embolic agents in the systemic venous system. *Am J Obstet Gynecol* 78:259-265, 1959
17. Smith I, Benzie RJ, Gordon NLM, Kelman GR, Swapp GH: Cardiovascular effects of peritoneal insufflation of carbon dioxide for laparoscopy. *Br Med J* 3:410-411, 1971
18. Wadhwa RK, McKenzie SR, Wadhwa DL, Katz DL, Byers JF: Gas embolism during laparoscopy. *ANESTHESIOLOGY* 48:74-76, 1978

Anesthesiology  
57:535-538, 1982

## New Methods for the Performance of Unilateral Lung Lavage

ROGER G. SPRAGG, M.D.,\* JONATHAN L. BENUMOF, M.D.,† DAVID D. ALFERY, M.D.‡

Massive bronchopulmonary lavage using a double-lumen endotracheal tube has become an accepted modality for the treatment of pulmonary alveolar proteinosis.<sup>1-5</sup>

During single-lung ventilation, the non-ventilated lung is lavaged with tidal volumes of saline until return of sediment is minimal; the procedure is then terminated.

Massive bronchopulmonary lavage is not without hazard. During the initial lavage of a patient, complete gas exchange must be accomplished by a single severely compromised lung. Periods of tidal drainage are accompanied by reperfusion of the non-ventilated lung<sup>6</sup> and potentially dangerous levels of hypoxemia. Drowning is prevented only by proper positioning of the endotracheal tube and adequate cuff inflation.

Recognizing these hazards, we have modified the published techniques of massive bronchopulmonary lavage to: (1) ensure correct placement of the double-lumen tube, and (2) investigate maneuvers to maximize gas exchange during unilateral lavage. Experience was gained during eight lavages performed on three patients with biopsy-proven alveolar proteinosis.

### METHODS

Patient evaluations included history, physical examination, arterial blood-gas analysis, and pulmonary function testing. In addition, preoperative ventilation-perfusion scanning was performed with the patient in the supine position ( $F_{I_{O_2}} = 0.21$  to 0.30) using standard techniques.<sup>7</sup>

With the patient in the supine position having received 5-10 min of preoxygenation, anesthesia was induced by the administration of 3-4 mg/kg sodium thiopental, iv, in divided doses, and inhalation of 0.5-2.0% halothane or 0.5-3.0% enflurane (patient 3) via mask. Following the onset of surgical anesthesia, the patients were paralyzed with pancuronium (0.15 mg/kg, iv).

For all lavages we used the National Catheter Corporation left lung, double-lumen tube. With one exception, we used the largest size tube that could be passed atraumatically through the glottis. The correct position of the double-lumen tube was confirmed by passing a fiberoptic bronchoscope (Machida FBS 4T bronchoscope) down both lumens of the tube. Via the left lumen, the subcarina separating the upper and lower lobes was clearly visible. The volume of air in the left endobronchial cuff was adjusted until the left endobronchial lumen just began to invaginate due to the external cuff pressure. Via the right lumen, a clear view of the carina was observed as well as the upper surface of the left endobronchial balloon.

The tracheal cuff was inflated until slight to moderate tension was palpated in the pilot balloon. We confirmed complete separation of the two lungs by clamping the tube connected to one lung proximal to the open suction port. A length of tubing was attached to the suction port, and the free end of this tube was submerged under water. When the ventilated lung was inflated statically to +50 cm H<sub>2</sub>O, endobronchial cuff inflation was ad-

\* Assistant Professor of Medicine, University of California at San Diego.

† Associate Professor of Anesthesia, University of California at San Diego.

‡ Staff Anesthesiologist, St. Thomas Hospital, Nashville, Tennessee. Received from the Departments of Medicine and Anesthesia, the University of California at San Diego, and the Department of Anesthesiology, St. Thomas Hospital, Nashville, Tennessee. Accepted for publication June 21, 1982.

Address reprint requests to Dr. Spragg: Division of Pulmonary and Critical Care Medicine, University Hospital, University of California, 225 Dickinson Street, San Diego, California 92103.

Key words: Lung; alveolar proteinosis; lavage.

AIR BUBBLE METHOD FOR CUFF SEAL

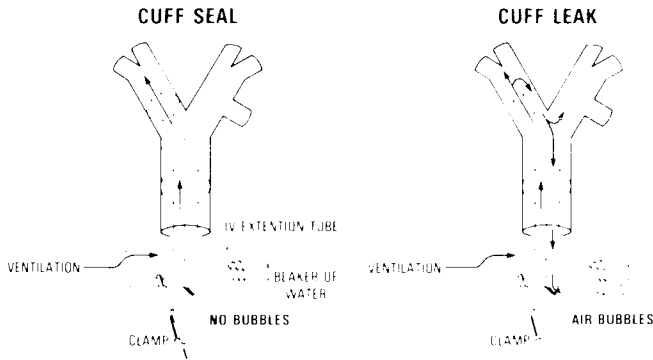


FIG. 1. Tubing assembly used to check for incomplete seal of the bronchial cuff. One lung is statically inflated to +50 cm H<sub>2</sub>O while leak is detected by observing air bubbles.

justed, if necessary, until no bubbles were observed passing through the water (fig. 1). To test for complete separation with the pressure gradient across the endobronchial balloon reversed, the opposite lung was inflated, with the air-leak detector moved to the non-inflated lung. Only when no air leak was seen with inflation of either lung to +50 cm H<sub>2</sub>O was complete separation assured. Luminal patency then was reconfirmed bronchoscopically.

The lung to be lavaged was filled with warm saline (35°C) at an infusion pressure of +30 cm H<sub>2</sub>O until flow ceased. The lung was then drained tidally and filled at pressures of -20 and +30 cm H<sub>2</sub>O, respectively.

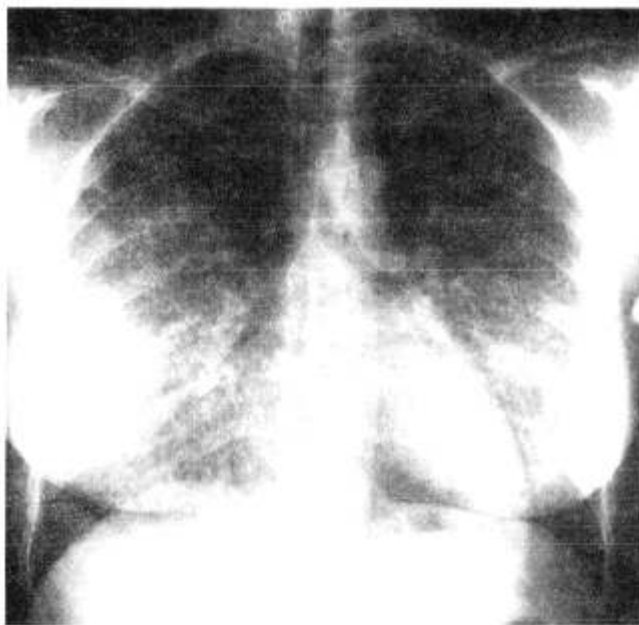


FIG. 2. Chest roentgenogram of patient 2 prior to lavage. A cryptococcoma is visible on the pleural surface of the right upper lobe.

TABLE 1. Arterial Blood Gases (FI<sub>O</sub><sub>2</sub> = 0.21) before and after Lavage of Both Lungs

Patient	Before Both Lung Lavages			After Both Lung Lavages		
	P <sub>a</sub> O <sub>2</sub> (mmHg)	P <sub>a</sub> CO <sub>2</sub> (mmHg)	pH	P <sub>a</sub> O <sub>2</sub> (mmHg)	P <sub>a</sub> CO <sub>2</sub> (mmHg)	pH
1	47	32	7.45	79	32	7.39
2	39	31	7.44	88	31	7.44
3						
1st	51	32	7.44	58	31	7.46
2nd	55	32	7.46	67	35	7.45

Position of a pulmonary artery catheter balloon in the right main pulmonary artery was verified radiologically at the time of three right lung lavage procedures. Following two different tidal lung drainages during each of these right lung lavage procedures, arterial blood gases were drawn before and five minutes after inflation of the pulmonary artery catheter balloon.

RESULTS

All patients were severely dyspneic; two had low-grade fevers; all had been forced to stop working. The chest radiographs showed diffuse alveolar filling (fig. 2). Arterial blood-gas values are shown in table 1.

Lavage of each lung resulted in dramatic and sustained improvement, functionally, physiologically (table 1), and radiographically (fig. 3) in two patients. Following an initially unsatisfactory result in patient 3, his chronic airway obstruction was treated with theophyllin,

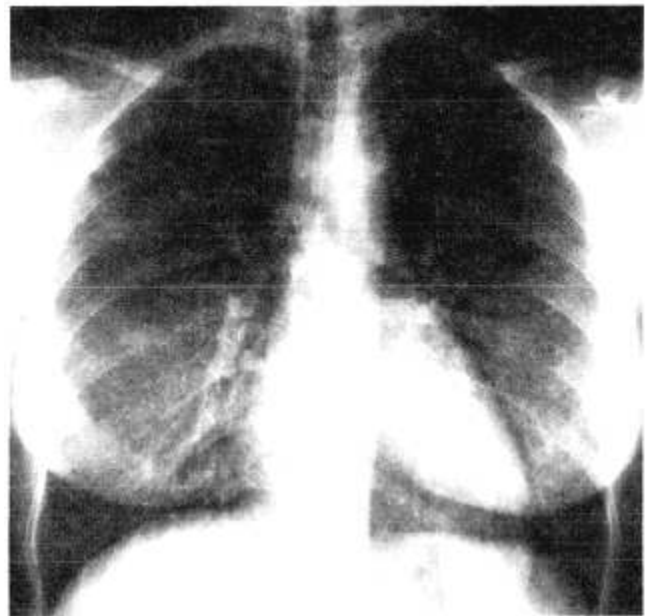

FIG. 3. Chest roentgenogram of patient 2, 25 days following lavage of right lung and 18 days following lavage of left lung. Almost complete clearing of the diffuse bilateral infiltrates has occurred.

prednisone, and metaproterenol. Airflow improvement occurred, and subsequent lavages resulted in a satisfactory result. One lavage in patient 3, however, was terminated after inadvertent outward traction at the mouth on the endotracheal tube caused it to become partially dislodged. In this instance, loss of complete separation of the two lungs was signalled sequentially by: (1) appearance of bubbles in lavage fluid draining from the lavaged lung, (2) rales and rhonchi in the ventilated lung, (3) failure to recover all fluid put into the lung at the next drainage, and (4) fall in arterial oxygen saturation.

Preoperative evaluation with ventilation/perfusion scanning demonstrated, in patient 1, an unexpected, uneven distribution of blood flow, with 70% perfusing the right lung and 30% the left. Ventilation was partitioned similarly. The right lung was then used for gas exchange during the initial unilateral lavage. Systemic oxygenation was well-maintained during the initial lavage in all patients.

Because of the hazard of intraoperative drowning, considerable attention was devoted to endotracheal tube placement and functional division of the two lungs. Several potentially harmful circumstances were remedied easily during bronchoscopic verification of tube placement. We observed that over-distension of the endobronchial cuff, particularly in smaller tubes, may cause severe narrowing of the bronchial tube lumen. This was easily avoided by inflating the cuff just to that point where luminal encroachment appeared. When an inappropriately undersized tube is used, however, this degree of bronchial cuff inflation tends to force the entire tube cephalad, making a functional bronchial seal difficult. In addition, over-distension of the endobronchial cuff may cause the cuff to herniate over the carina, or may shift the carina rightward. Both cuff herniation and rightward carinal deviation were capable of causing obstruction of the right mainstem bronchus orifice.

Testing lung separation by monitoring for gas leak while statically inflating first one lung and then the other was easily accomplished. In the absence of air leak, compression of the non-ventilated lung by the ventilated lung caused some bubbling in the detection system, which ceased within a few seconds. Repetitive inflations of the ventilated lung gave successively less compression-related bubbling, and none was seen following six inflations.

In all patients, following right lung drainage, inflation of the pulmonary artery catheter balloon caused a significant increase in PaO<sub>2</sub> (table 2).

#### DISCUSSION

Our clinical results are consistent with prior reports of the efficacy of massive lung lavage in the treatment

TABLE 2. PaO<sub>2</sub> (mmHg) before and after Inflation of Right Pulmonary Artery Catheter Balloon Following Tidal Drainage of the Right Lung

Patients	Before Inflation	After Inflation
1	67	80
	81	103
2	51	68
	49	69
3	62	65
	56	67
Mean ± SE	61 ± 5	75 ± 6*

\* *P* = 0.004 (paired *t* test).

of alveolar proteinosis.<sup>3,4</sup> In this report we wish to emphasize methods which may increase the safety of unilateral lung lavage.

During a patient's first lavage, gas exchange must be totally supported by a single diseased lung. To optimize gas exchange during that lavage, we have used ventilation-perfusion scanning to define which lung contributes the greater share of gas exchange. In one of the patients lavaged, preoperative scans demonstrated the majority of ventilation and perfusion to be distributed to the right lung. Initial lavage was, therefore, of the left lung.

We have described several ways in which over-inflation of the left endobronchial cuff may cause airway obstruction. Fiberoptic bronchoscopy readily identifies problems both with double-lumen tube misplacement and with left endobronchial cuff inflation.

Although we never observed an arterial hemoglobin saturation less than 85%, one might well expect that during the first lavage of a patient with extensive disease, profound hypoxemia might occur. This would be likely during periods of tidal drainage, with perfusion of the non-ventilated lung. One method of supporting gas exchange in this circumstance is to use extracorporeal gas exchange.<sup>8,9</sup> We believe an alternative might be to reduce perfusion of the lavaged lung during the initial lavage. During tidal filling, "Zone 1" conditions prevail.<sup>10</sup> However, during tidal drainage, unilateral pulmonary artery balloon occlusion might be used to divert blood flow.

While none of our patients had profound arterial desaturation during lavage, we were able to show that PaO<sub>2</sub> could be increased by inflation of the pulmonary artery balloon catheter. Pre-lavage evaluation with one-lung ventilation and contralateral pulmonary artery occlusion might allow one to predict whether lavage could be performed safely without need for cardiopulmonary bypass.

In summary, we have reported several methods that may facilitate the performance of unilateral lung lavage.

These methods include: (1) use of ventilation-perfusion scanning to guide in the choice of initial lavage site, (2) use of the fiberoptic bronchoscope and an airway leak detector to effect precise separation of the two lungs, and (3) use of temporary unilateral pulmonary artery balloon occlusion to improve oxygenation.

## REFERENCES

1. Kylstra JA, Rausch DC, Hall KD, Spock A: Volume controlled lung lavage in the treatment of asthma, bronchiectasis and mucoviscidosis. *Am Rev Respir Dis* 103:651-662, 1971
2. Ramirez-RJ, Kieffer RF Jr, Ball WC Jr: Bronchopulmonary lavage in man. *Ann Intern Med* 63:819-828, 1965
3. Selecky PA, Wasserman K, Benfield JR, Lippman M: The clinical and physiological effect of whole lung lavage in pulmonary alveolar proteinosis: A ten year experience. *Ann Thorac Surg* 24:451-461, 1977
4. Rogers RM, Tantam KR: Bronchopulmonary lavage: A "new" approach to old problems. *Med Clin North Am* 54:755-771, 1977
5. Kao D, Wasserman K, Costley D, Benfield J: Advances in the treatment of pulmonary alveolar proteinosis. *Am Rev Respir Dis* 111:361-363, 1975
6. Smith JD, Miller JE, Safer P, Robin ED: Intrathoracic pressure, pulmonary vascular pressures and gas exchange during pulmonary lavage. *ANESTHESIOLOGY* 33:401-405, 1970
7. Tisi GM, Landis GA, Miale A Jr, Moser KM: Quantitation of regional pulmonary blood flow: Validity and potential sources of error. *Am Rev Respir Dis* 97:843-850, 1968
8. Altose MD, Hicks RE, Edwards MW Jr: Extracorporeal membrane oxygenation during bronchopulmonary lavage. *Arch Surg* 111:1148-1153, 1976
9. Cooper JD, Duffin J, Glynn MF, et al: Combination of membrane oxygenator support and pulmonary lavage for acute respiratory failure. *J Thorac Cardiovasc Surg* 71:304-308, 1976
10. West JB: *Ventilation/Blood Flow and Gas Exchange*. Oxford, Blackwell Scientific Publications, 1970, p 25

Anesthesiology  
57:538-539, 1982

## Slowing of Heart Rate during Cardiac Output Measurement by Thermodilution

TOSHIKI NISHIKAWA, M.D.,\* AND SHUJI DOHI, M.D.†

With measurements of cardiac output and pulmonary hemodynamics using the flow-directed balloon-tipped (Swan-Ganz®) catheter, several complications<sup>1</sup> have been described which usually are related to the insertion of the catheter, but not to the measurement of cardiac output by thermodilution *per se*. However, Weisel *et al.*<sup>2</sup> observed a transient arrhythmia following the injection of cold injectate. We recently observed a case in which bradycardia developed abruptly following the injection of the cold tracer during measurements of cardiac output.

### REPORT OF A CASE

A 52-year-old, 40 kg woman underwent a craniotomy for removal of a brain tumor. Her past history included pulmonary tuberculosis 30 years ago, and previous surgery for a brain tumor four years ago. ECG and other laboratory data revealed no abnormality.

One hour before anesthesia, 0.4 mg atropine was administered im. Anesthesia was induced with 250 mg thiamylal, iv, and the trachea intubated after administration of 50 mg succinylcholine, iv. During

anesthesia with halothane, nitrous oxide, and controlled ventilation, a 7F thermistor-tipped, flow-directed (Swan-Ganz®) catheter was inserted percutaneously through the right internal jugular vein to monitor the cardiopulmonary status (the *in vivo* catheter length was 40 cm). A computer (9520, Edwards Laboratory) was used to determine cardiac output by the thermodilution technique. A second catheter was inserted into the left radial artery for monitoring of arterial blood pressure and blood sampling for blood-gas analysis.

Cardiac output determined two hours after the induction of anesthesia, was 3.34 l/min. At this time, heart rate was 72 beats/min, arterial blood pressure 100/60 mmHg, pulmonary arterial pressure 23/10 mmHg, right atrial pressure 9.0 cm H<sub>2</sub>O, pulmonary capillary wedge pressure 8.0 mmHg. The *pH<sub>a</sub>* was 7.41, PaCO<sub>2</sub> 37 mmHg, PaO<sub>2</sub> 163 mmHg, and BE 0.7 mEq/l. The rectal temperature was 36.9° C.

One hour later, however, when 10 ml of cold 5% dextrose solution were injected into the central venous port of the catheter, the heart rate, which was calculated electronically, decreased suddenly from 68 to 60 beats/min and then shortly returned to its previous level (fig. 1A). Two sequential determinations of cardiac output produced similar changes (fig. 1B and C). On these occasions, the values of cardiac output measured were 4.38, 4.32, 4.08 l/min, respectively. Arterial and pulmonary arterial pressure showed little change (fig. 1A, B, C) and the ECG did not change with the exception of transient slowing of normal sinus rhythm.

Thereafter, 10 ml of 5% dextrose in water (2° C) were injected into the distal port of the catheter. No change as appeared above occurred, however. Although 10 ml of 5% dextrose solution (37° C) were again injected into the central venous port of the catheter, no change in heart rate occurred. In one of the last series of measurements, decreases in both the radial artery and pulmonary artery pressure as well as a decrease in heart rate occurred at the time of the injection of the cold tracer (fig. 1D). The value of cardiac output was 2.74 l/min. The catheter was then retracted about 3 cm. The above episode did not occur again.

\* Instructor.

† Associate Professor of Anesthesiology, Institute of Clinical Medicine, The University of Tsukuba, Sakuramura, Ibaraki, 305.

Received from the Department of Anesthesiology, Sapporo Medical College and Hospital, Chuoku, Sapporo, Hokkaido 060, Japan. Accepted for publication June 22, 1982.

Address reprint requests to Dr. Dohi.

Key words: Equipment: catheters, flow-directed. Complications: bradycardia.