

efforts, a pulse of 30, and a systolic blood pressure of 60 mmHg detectable only with palpation. The paramedics were able to place a 6-mm oral endotracheal tube with some difficulty. The patient was given 50 mEq of sodium bicarbonate and transported to the emergency room while being ventilated with 100% oxygen. An initial blood gas analysis in the emergency room showed a pH of 7.23 with a P_{CO_2} of 32, and a P_{aO_2} of 354. The patient was taken to the operating room where direct laryngoscopy revealed a swollen epiglottis but normal and relatively easily visualized vocal folds.

This patient is unusual in that she survived an episode of respiratory obstruction secondary to epiglottitis. It is noteworthy that the epiglottis, while significantly edematous, did not appear large enough to have caused a physical obstruction to ventilation. This suggests that the mechanism of obstruction may be either a reflex obstruction or an inability to handle secretions, and further supports the need for early intervention in these patients even when epiglottic swelling is not severe. We

also found that direct laryngoscopy, while more difficult than in the normal patient, was not so difficult as to make the risk of the procedure weigh heavily against its performance. This case reinforces our prejudice for an artificial airway as soon as possible after diagnosis in this disease.

MICHAEL J. BISHOP, M.D.

Assistant Professor of Anesthesiology

Adjunct Assistant Professor of Medicine

ERNEST A. WEYMULLER, JR., M.D.

Associate Professor and Otolaryngologist-in-Chief

Harborview Medical Center

University of Washington School of Medicine

Seattle, Washington 98195

REFERENCES

1. Bishop MJ: Epiglottitis in the adult. *ANESTHESIOLOGY* 55:701-702, 1981

(Accepted for publication June 4, 1982.)

Anesthesiology
57:546-547, 1982

An Aid to Identifying the External Jugular Vein

To the Editor:—The external jugular vein (EJV) frequently is used for access to the central circulation or in patients whose peripheral veins are difficult to cannulate.¹ At times it is difficult to maintain the EJV in a distended condition without either an assistant man-

ually occluding it or an extreme head down position (the latter of which may not be well-tolerated). We report an easy to perform maneuver which distends the EJV even in sitting patients without the need for an assistant.

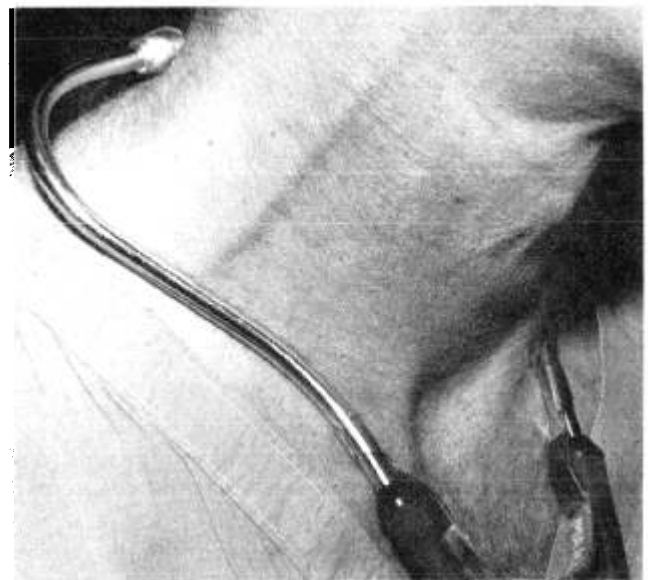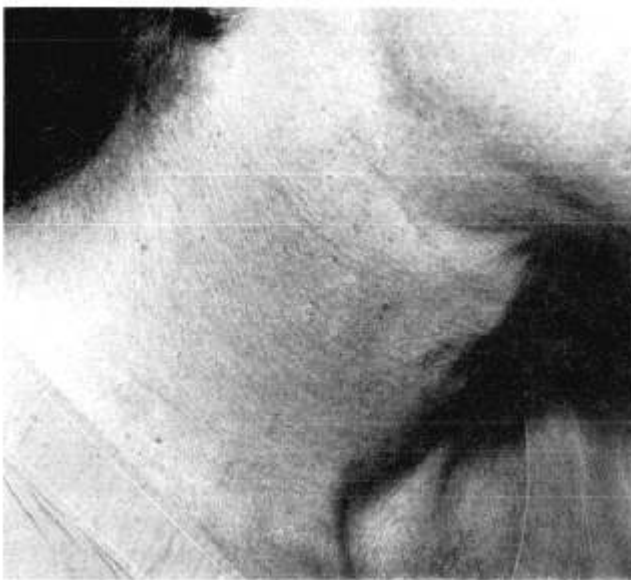


FIG. 1. External jugular vein before (1A, left) and after (1B, right) distension by stethoscope applied to a sitting individual.

A suitably "springy" stethoscope placed about the base of the neck distends the EJV of most patients (figs. 1A and 1B). Repositioning of the stethoscope may be required to "pop up" the vein. The stethoscope is left on the patient's neck during cannulation and then removed to prevent back bleeding and to relieve venous obstruction. Patient acceptance is good, the equipment is readily available, and complications are absent. It is now a routine part of the preoperative exam in patients in whom the possibility of EJV cannulation is raised.

MARK S. SCHELLER, M.D.
Resident in Anesthesiology

Anesthesiology
57:547, 1982

LAWRENCE J. SAIDMAN, M.D.
*Professor and Chairman
Department of Anesthesiology
University of California, San Diego
San Diego, California 92103-9981*

REFERENCES

1. Blitt CD, Wright WA, Petty WC, Webster TA: Central venous catheterization via the external jugular vein. A technique employing the J-wire. *JAMA* 229:817, 1974

(Accepted for publication June 10, 1982.)

Responsibility for Equipment Failure: Consumer vs. Manufacturer

To the Editor:—One should take exception with the spirit of the Anderson and Rendell-Baker letter,¹ which would appear to be "let us make George take of it!!"

After looking at the photograph which accompanied the letter, one notices that the two instruments on the shelf of the anesthesia gas machine are not anchored properly by means of bolts, screws, or "T" or "B" bars; one also notices that provisions have not been made for all cables, to and from the instruments, to be equipped with an appropriate strain release chain (this is a device tightly anchored to the cable at one end and to the supporting frame at the other end in such a manner that any pull on the cable is both transmitted and absorbed by the frame and does not dislodge the instrument).

Since it would appear that the photograph was taken after the accident, the inference would have to be that not much was learned from the accident.

I would submit that the real issue is not the damage

Anesthesiology
57:547-548, 1982

to the O₂ flush knob, which occurred this time, but rather, the fact that any piece of equipment sitting *unsecured* on a shelf is a general hazard (the next time a patient's head might be injured or a fire may be started).

Before blaming the manufacturer for any mishap, and thereby forcing new standards and regulations as well as costly modifications one should take a much closer and harsher look at the real culprit which is "us, the users."

ANTONIO BOBA, M.D.
*85 Albany Post Road
P.O. Box 631
Hyde Park, New York 12538*

REFERENCE

1. Anderson CE, Rendell-Baker L: Exposed O₂ flush hazard. *ANESTHESIOLOGY* 56:328, 1982

(Accepted for publication June 10, 1982.)

Thiopental Anesthesia for Cesarean Section

To the Editor:—We were astounded to read the recent recommendation regarding intermittent thiopental injections as the sole anesthetic for cesarean section.¹ This method may have been acceptable in 1974, but it is no longer appropriate in 1982 when mother and father, obstetrician and neonatologist demand newborn conditions that facilitate parent-infant interaction.

Based on umbilical vein and artery blood thiopental concentrations, the authors concluded that, with their method, "thiopental levels in the fetus and newborn . . . are not excessive." However, umbilical cord blood values are indicative only of the condition at birth. A study of thiopental pharmacokinetics in cesarean section has revealed a neonatal elimination half-life from 11 to