

observations suggest that the presence of muscular dystrophy does not in itself make the contracture response abnormal, and that an abnormal contracture response can be used to indicate MH susceptibility even in patients with muscular dystrophy.

There is a widespread impression, supported by Richard's report¹⁵ of 61 uncomplicated general anesthetics in 43 patients with DMD, that general anesthesia in DMD, is normally uneventful. Our case report proves that MH may complicate general anesthesia in this group of patients. While this is the first report of MH in DMD proven by contracture studies, there are two other published reports of probable MH in patients with DMD,² but neither patient had the diagnosis confirmed by contracture studies. We believe that MH must now be recognized as a possible complication of general anesthesia in DMD patients.

REFERENCES

1. Rowland LP, Layzer RB: Muscular dystrophies, atrophies and related diseases, *Clinical Neurology*. Edited by Baker AB, Baker LH. Philadelphia, Harper and Row, 1981, pp 22-24
2. Seay AR, Ziter FA, Thompson JA: Cardiac arrest during induction of anesthesia in Duchenne muscular dystrophy. *J Pediatr* 93:1, 88-90, 1978
3. Miller ED, Sanders DB, Rowlingson JC, Berry FA, Sussman MD, Epstein RM: Anesthesia-induced rhabdomyolysis in a patient with Duchenne's muscular dystrophy. *ANESTHESIOLOGY* 48:146-148, 1978
4. Boltshauser E, Steinmann B, Meyer A, Jerusalem F: Anesthesia induced rhabdomyolysis in Duchenne muscular dystrophy. *Br J Anaesth* 52:559, 1980
5. Rowland LP: Biochemistry of muscle membranes in Duchenne muscular dystrophy. *Muscle Nerve* 3:3-20, 1980
6. Rosenberg H: Malignant hyperpyrexia. *Muscle Nerve* 3:443, 1980
7. Willner JH, Wood DS, Cerri C, Britt B: Increased myophosphorylase in malignant hyperthermia. *N Engl J Med* 303:138-140, 1980
8. Kalow W, Britt BA, Richter A: The caffeine test of isolated human muscle in relation to malignant hyperthermia. *Can Anaesth Soc J* 24:678-694, 1977
9. Dubowitz V, Brooke MH: *Muscle Biopsy: A Modern Approach*. London, WB Saunders, 1973, pp 20-33
10. Britt BA, Endrenyi L, Scott E, Frodis W: Effect of temperature, time and fascicle size on the caffeine contracture test. *Can Anaesth Soc J* 27:1-11, 1980
11. Dubowitz V, Brooke MH: *Muscle Biopsy: A Modern Approach*. London, WB Saunders, 1973, pp 169-178
12. Moulds RFW, Denborough MA: Identification of susceptibility to malignant hyperpyrexia. *Br Med J* 4:245-247, 1974
13. Britt BA: Preanesthetic diagnosis of malignant hyperthermia, *International Anesthesiology Clinics*. Edited by Britt BA. Boston, Little, Brown and Company, 1979, pp 63-96
14. Moulds RFW, Denborough MA: Myopathies and malignant hyperpyrexia. *Br Med J* 3:520, 1974
15. Richards WC: Anesthesia and serum creatine phosphokinase levels in patients with Duchenne's pseudohypertrophic muscular dystrophy. *Anesth Intensive Care* 1:150-153, 1972

Anesthesiology
58:182-184, 1983

Hypertension after Intraoperative Autotransfusion in Bilateral Adrenalectomy for Pheochromocytoma

DEAN F. SMITH, M.D.,* FRED G. MIHM, M.D.,† IVAN MEFFORD, PH.D.‡

Management of patients with pheochromocytoma includes preoperative alpha-adrenergic receptor blockade, intraoperative blood pressure control, and intravascular volume expansion with crystalloid solutions and

blood.¹ We describe a patient with bilateral pheochromocytomas who was also a Jehovah's Witness,² but who consented to intraoperative use of autotransfusion. Concomitant with the transfusion of autologous packed erythrocytes, a dramatic increase in systemic arterial pressure was observed.

REPORT OF A CASE

A 31-year-old woman with the syndrome of multiple endocrine neoplasias, type II, including bilateral pheochromocytoma was admitted for bilateral adrenalectomy. She had previously undergone bilateral radical dissection for thyroid medullary carcinoma. The patient was a Jehovah's Witness and would not accept transfusion of any banked blood products. However, she did consent to the intraoperative use of autotransfusion using a Cell-Saver® (Haemonetics Cell

* Chief Resident in Anesthesia.

† Assistant Professor of Anesthesia.

‡ Research Associate in Psychiatry.

Received from the Departments of Anesthesia and Psychiatry, Stanford University School of Medicine, Stanford, California. Accepted for publication August 6, 1982.

Address reprint requests to Dr. Mihm: Department of Anesthesia, Stanford University School of Medicine, Stanford, California 94305.

Key words: Organizations: Jehovah's Witnesses. Surgery: pheochromocytoma. Complications: hypertension. Transfusion: autotransfusion.

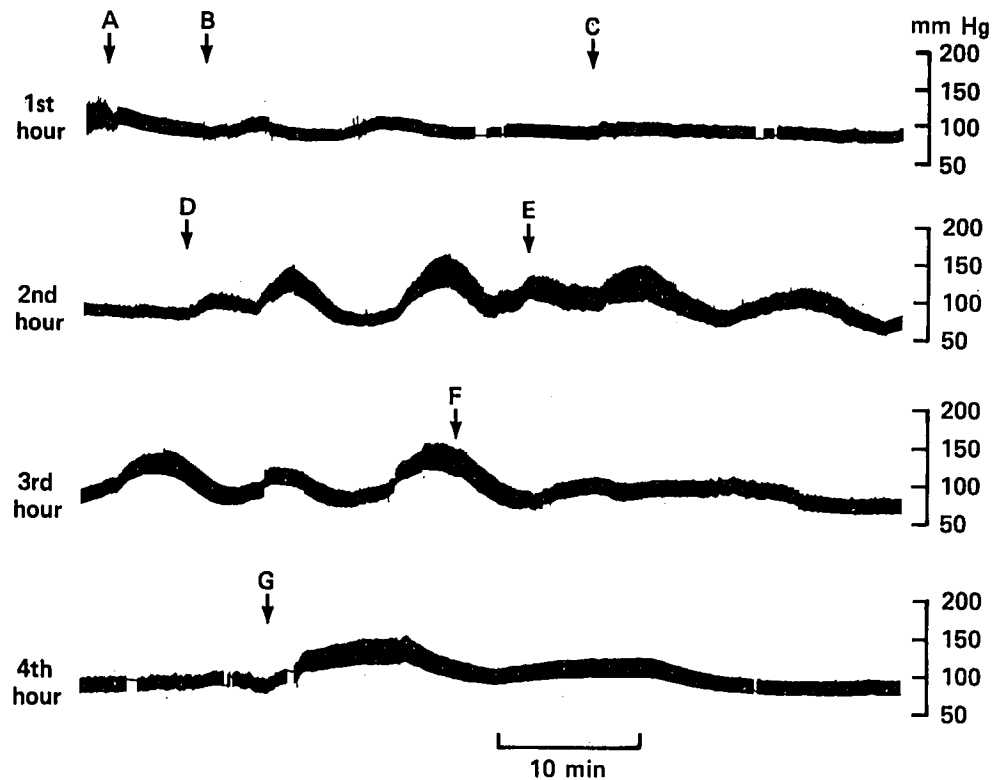


FIG. 1. This figure shows the arterial pressure recording during the entire four-hour operation. The letter keys describe the following events: A. induction of anesthesia; B. intubation; C. Incision; D. manipulation of tumors; E. left tumor excised; F. right tumor excised; and G. autotransfusion.

Saver III, Haemonetics Corporation). Seventeen months before admission, she began experiencing intermittent headaches and palpitations; however, measured urinary catecholamines were normal until two months prior to surgery. An abdominal aortogram identified large bilateral adrenal tumors. Preoperative hypertension was never documented, nor was there evidence of congestive heart failure or catecholamine-induced cardiomyopathy. One month prior to surgery, 40 mg/day phenoxybenzamine, and one week later, 40 mg/day propranolol was started. Her symptoms resolved and both drugs were continued up to the time of surgery. On the preoperative examination, arterial blood pressure was 95/60 mmHg without orthostatic changes. Her heart rate was 70 beats/min and regular, and her respiratory rate was 20 breaths/min. Physical examination was normal, except for evidence of previous thyroid surgery. The electrocardiogram was normal, the hematocrit was 39.6%, and routine coagulation tests were normal. The patient was premedicated with 10 mg diazepam orally and 2 mg hydromorphone, im. Radial artery and pulmonary artery catheters were inserted. Anesthesia was induced with 200 mg thiopental, iv, nitrous oxide, enflurane, and 5 mg pancuronium, iv. Ten minutes later, the trachea was intubated. Both the intubation and skin incision were well-tolerated, but with surgical manipulation of the adrenal tumors, profound increases in mean arterial pressure were observed (fig. 1). A continuous infusion of $1-2.5 \mu\text{g} \cdot \text{kg}^{-1} \cdot \text{min}^{-1}$ sodium nitroprusside was initiated. The first tumor (35 g) was resected 70 min after skin incision, and the second (186 g) was removed 45 minutes later. An anticipated fall in blood pressure occurred after removal of the second adrenal tumor. At this time, the inspired enflurane concentration was 0.5% and the nitroprusside infusion had been stopped for ten min. A hematocrit was 30%. A total of 600 ml of blood was collected from the surgical field and processed in the Cell-Saver[®], which yielded 200 ml of washed and centrifuged erythrocytes which were infused while the peritoneal cavity was explored manually. A precipitous increase in blood pressure from a mean of 60 to 120 mmHg

occurred at this time, approximately 30 min after removal of the second adrenal tumor (fig. 1). The event lasted 15 min, and was followed by another fall in mean arterial pressure which responded to aggressive iv crystalloid administration (5,500 ml for the entire operation) and levarterenol infusion ($5 \mu\text{g}/\text{min}$) to maintain a mean arterial pressure of approximately 80 mmHg. Estimated blood loss was 700 ml. No additional tumors were discovered, and a repeat exploration of the abdomen was not associated with a change in blood pressure. The patient was taken to the surgical intensive care unit where the levarterenol infusion was maintained for three hours. Her trachea was extubated on the day following surgery, and she was discharged from the intensive care unit on the sixth postoperative day.

A sample of blood from the Cell-Saver[®] collection chamber was analyzed for catecholamines by high pressure liquid chromatography with electrochemical detection. This assay is linear from 5 pg/ml to 250 ng/ml.³ The values obtained were an epinephrine level of 1.5×10^6 pg/ml (normal < 50 pg/ml), a norepinephrine level of 10.3×10^6 pg/ml (normal < 500 pg/ml), and a dopamine level of 3.0×10^4 pg/ml (normal < 30 pg/ml).

DISCUSSION

Despite proper preoperative preparation and anesthetic management, hypertension will still occur during surgical resection of pheochromocytoma, particularly during tumor manipulation. After the known tumor(s) have been removed, additional tumor sites are sought by simple monitoring for a hypertensive response during manual exploration of the abdomen.^{4,5} When the hypertensive episode occurred in this case, the possibility of additional tumors was considered unlikely and

none was found. In addition a second manual exploration did not produce hypertension. Because this period of hypertension correlated well with the autotransfusion, we suspected that this blood contained catecholamines, and were able to document their presence in extremely high levels (>10,000 times normal). The patient received a smaller amount of catecholamines than would be suggested by this assay because blood from the collection chamber was centrifuged, washed with saline, and centrifuged again before administration.

In summary, we suggest that catecholamine transfusion is a potential complication of autotransfusion during surgery for pheochromocytoma. Additional wash cycles before erythrocyte transfusion should decrease the catecholamine concentration. Hypertension should be anticipated with the use of autotransfusion

in these individuals and could confuse the search for additional tumors.

REFERENCES

1. Ram CVS, Engelman K: Pheochromocytoma—recognition and management. *Curr Probl Cardiol* 4:1-38, 1979
2. Watchtower Bible and Tract Society: *Jehovah's Witnesses and the Questions of Blood*. New York, Watchtower Bible and Tract Society of New York, 1977
3. Mefford IN, Ward MM, Laughton M, et al: Determination of plasma catecholamines and free 3,4-Dihydroxyphenylacetic acid in continuously collected human plasma by high performance liquid chromatography with electrochemical detection. *Life Sci* 28:477-483, 1981
4. Ross EJ, Prichard BNC, Kaufman L, Robertson AIG, Harries BJ: Preoperative and operative management of patients with pheochromocytoma. *Br Med J* 1:191-198, 1967
5. Sjoerdsma A, Engleman K, Waldmann TA, Cooperman LH, Hammond WG: Pheochromocytoma: Current concepts of diagnosis and treatment. *Ann Intern Med* 65:1302-1326, 1966

Anesthesiology
58:184-187, 1983

Spread of Epidural Analgesia in Early Pregnancy

LENNART FAGRAEUS, M.D., PH.D.,* BRUNO J. URBAN, M.D.,†
PHILIP R. BROMAGE, M.B., B.S. (LONDON), FFARCS, FRCP(C)†‡

The mechanism for the facilitated spread of epidural analgesia in pregnant women at term¹⁻³ has not been elucidated. Elevated intraabdominal pressure and inferior vena cava compression from the pregnant uterus have been proposed as likely causes during labor.^{1,2} Both factors may redirect part of the venous return via the vertebral system of veins leading to changes in epidural volume and pressure.³ In addition, the exaggerated lumbar lordosis of pregnancy may contribute to the increased cephalad spread of the anesthetic solution.⁴ We have observed a facilitated epidural spread in pregnant women even during the first trimester, at

a time when mechanical factors are unlikely to play a significant role.⁵ The purpose of this study was to further document these findings.

MATERIALS AND METHODS

The study was approved by the Duke University Clinical Investigations Committee. Levels of epidural analgesia were studied in 37 women: 12 non-pregnant controls, and 23 patients pregnant in their first trimester (range 8-12 weeks). All patients were ASA physical status 1 and scheduled to undergo elective abortion or other gynecologic procedures. Each patient had requested epidural analgesia for the operation, was free of neurologic disease, local infection, sepsis, and bleeding abnormalities, and was not receiving heparin prophylaxis. No sedation was given. A standardized epidural technique was used in all cases. The epidural puncture was performed with an 18-gauge Tuohy needle at the second lumbar interspace with the patient in the lateral position. The epidural space was identified by the loss-of-resistance technique with an air-filled syringe. A 2% lidocaine solution premixed with epinephrine 1/200,000 was injected in two doses; a 2-ml test dose was followed after 1 to 2 min by 18 ml of the

* Associate Professor.

† Professor.

‡ Professor and Chairman, Department of Anesthesiology, University of Colorado Health Science Center, Denver, Colorado.

Received from the Department of Anesthesiology, Duke University Medical Center, Durham, North Carolina. Accepted for publication August 6, 1982.

Presented in part at the annual meeting of the American Society of Anesthesiologists, San Francisco, California, October 1979.

Address reprint requests to Dr. Fagraeus: Department of Anesthesiology, 800 North East 13th Street, Post Office Box 26901, Oklahoma City, Oklahoma 73190.

Key words: Anesthetic technique: epidural; lumbar. Anesthesia: obstetric.