

based on spread of analgesic solution via the prevertebral fascial space which lies immediately anterior to the brachial plexus and its sheath. If punctures had been made in the fascia by the repeated repositioning of the needle, a fairly large volume might have been injected into this fascial plane. Spread in this plane to the opposite side of the neck is possible if the patient has inadequately developed midline septa.

Although a finger can be passed from one side of the neck to the other in this plane, we have not been able to demonstrate spread of dye across the midline in cadavers. The volume needed to cause paresis by this means would be expected to be much greater than that used. The fact that the patient was thin might, however, have allowed easier spread of the analgesic in this fascial plane.

Another possibility is a hysterical reaction. This is unlikely because the patient was calm, quiet, and rational at all times during the block. Furthermore, the block wore off on the side opposite to where the needle had been inserted before it did on the ipsilateral side. Motor paresis also disappeared before sensory paresis as would be expected in a truly blocked limb.

None of the above explain both the bilateral block and the paraesthesiae which the patient experienced in the contralateral arm on insertion of the needle. Thus, we have no explanation for our case of bilateral brachial plexus block following use of the interscalene technique.

No other case with complete motor paralysis of the opposite limb lasting for more than one hour has been documented. Furthermore, there was no depression of respiration or the cardiovascular system.

REFERENCES

1. Winnie AP: Interscalene brachial plexus block. *Anesth Analg (Cleve)* 49:455-466, 1970
2. Barutell C, Vidal F, Raich M, Montero A: A neurological complication following interscalene brachial plexus block. *Anaesthesia* 35:365-367, 1980
3. Ross S, Scarborough CD: Total spinal anesthesia following brachial plexus block. *ANESTHESIOLOGY* 39:458, 1973
4. Scammell SJ: Inadvertent epidural anaesthesia as a complication of interscalene brachial plexus block. *Anaesth Intens Care* 7:56-57, 1979
5. Kumar A, Battit GE, Froese AB, Long MC: Bilateral cervical and thoracic epidural blockade complicating interscalene brachial plexus block. Report of two cases. *ANESTHESIOLOGY* 35:650-652, 1971
6. Edde RR, Deutsch S: Cardiac arrest after interscalene brachial plexus block. *Anesth Analg (Cleve)* 56:446-447, 1977
7. Seltzer JL: Hoarseness and Horner's syndrome after interscalene brachial plexus block. *Anesth Analg (Cleve)* 56:585-586, 1977
8. Siler JN, Lief PL, Davis JF: A new complication of interscalene brachial plexus block. *ANESTHESIOLOGY* 38:590-591, 1973
9. Ward ME: The Interscalene approach to the brachial plexus. *Anaesthesia* 29:147-157, 1974
10. Hood J, Knoblanche G: Respiratory failure following brachial plexus block. *Anaesth Intens Care* 7:285-286, 1979
11. Cobcroft MD: Bilateral spread of analgesia with interscalene brachial plexus block. *Anaesth Intens Care* 4:73, 1976

Anesthesiology
58:473-475, 1983

Massive Occult Retroperitoneal Hemorrhage during Hip Surgery

ROMUALDAS V. BRIZGYS, M.D., CPT, MC,* AND HENRY C. HICKS, M.D., MAJ, MC†

Major vascular injury is a rare but important complication of hip surgery.¹⁻³ The most common signs of vascular injury are penetration or disruption of iliac or femoral vessels with subsequent signs of hemorrhage,

ischemia, and pseudoaneurysmal formation.²⁻⁴ Many of these injuries occur in the postoperative period in patients who were previously hemodynamically stable.²⁻⁴ We describe an unusual vascular complication in a patient undergoing hip surgery which underscores the potentially catastrophic result that can occur.

* Chief Resident, Anesthesiology.

† Attending Anesthesiologist.

Received from the Anesthesia/Operative Service, Department of Surgery, Letterman Army Medical Center, Presidio of San Francisco, California. Accepted for publication November 17, 1982.

The opinions or assertions contained herein are the private views of the authors and are not to be construed as official or as reflecting the views of the Department of the Army or the Department of Defense.

Address reprint requests to Technical Publications Editor: Letterman Army Medical Center, Presidio of San Francisco, California 94129.

Key words: Blood:loss. Hemorrhage. Shock. Surgery: orthopedic; total hip arthroplasty.

REPORT OF A CASE

An 80-year-old, ASA II man was admitted with a right subcapital hip fracture and was scheduled for a right hemiarthroplasty. Preoperative radiologic examination showed a fracture of the right femoral neck with intracapsular swelling suggesting a hematoma. His medical history was unremarkable except for prostatic adenocarcinoma that had been treated with diethylstilbesterol plus radiation therapy (2400 rads) to metastatic lesions of the right sacroiliac joint. Arterial blood pressure was 120/60 mmHg and heart rate was 84 beats per minute. The preoperative hemoglobin was 10.6 g/dl. All other laboratory data including electrolytes, electrocardiogram (ECG), chest roentgenograph, urinalysis, prothrombin time, and partial thromboplastin times

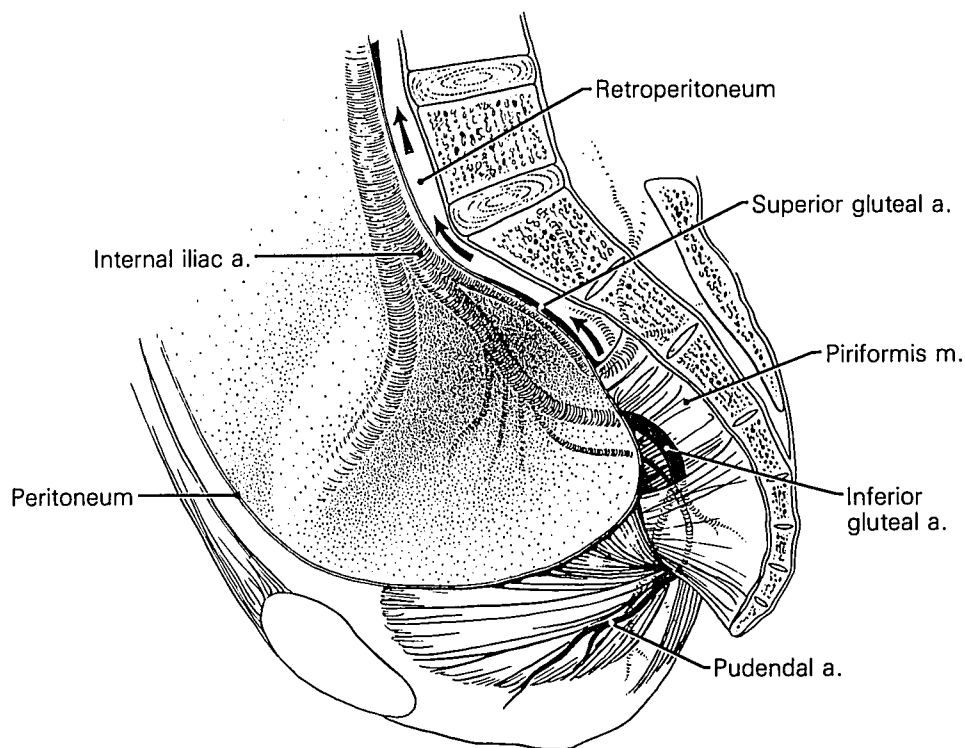


FIG. 1. The relationship of gluteal artery branches and retroperitoneum as viewed from within the pelvis is illustrated. Arrows denote the plane of retroperitoneal dissection.

were within normal limits. An intravenous infusion of 5% dextrose and 0.45% saline was begun on the day of admission.

Premedication was 5 mg diazepam orally. A left radial arterial line, right external jugular central venous line, and 16-gauge peripheral intravenous line were inserted, as is our standard procedure. Anesthesia was induced by an isobaric bupivacaine subarachnoid block. An indwelling Foley catheter was inserted into the bladder. A T6 sensory level to pinprick was obtained. An episode of transient hypotension to a systolic pressure of 78 mmHg occurred which was treated successfully with 15 mg ephedrine and crystalloids iv. The patient was placed in the left lateral decubitus position and the surgery performed through a southern approach to the hip utilizing a gluteal splitting incision. Systolic blood pressures ranged from 95 to 105 mmHg during the first 75 min of the procedure. Total iv fluid requirements to maintain this blood pressure consisted of 4.0 l crystalloids and packed erythrocytes, one unit. Concomitantly, the central venous pressure rose from an initial value of 1 mmHg to 4 mmHg. Observable blood loss was estimated at 250 ml.

Prior to insertion of methylmethacrylate cement into the femoral canal, arterial blood pressure decreased abruptly to a systolic of 68 mmHg requiring ephedrine and neosynephrine iv in addition to crystalloids and a second unit of packed erythrocytes. The patient complained only of nausea and dyspnea. Analysis of arterial blood gases revealed a pH_a 7.36, Pa_{O_2} 105 mmHg, Pa_{CO_2} 27 mmHg with a FI_{O_2} of 0.24. Estimated observable blood loss was 350 ml. The onset of emesis and continued hemodynamic instability necessitated oral endotracheal intubation, which was accomplished after preoxygenation, cricoid pressure, and facilitated with administration of *d*-tubocurarine and succinylcholine iv. Arterial blood pressure was maintained with neosynephrine infusion to a systolic pressure of 100 mmHg. The surgeons were unable to identify any sources of hemorrhage. Analysis of arterial blood gases then showed pH 7.44, Pa_{O_2} 430 mmHg, and Pa_{CO_2} 29 mmHg with an FI_{O_2} of 1.0. An ECG showed sinus tachycardia of $118 \cdot \text{min}^{-1}$ without evidence of injury or ischemia. The CVP remained at 1–2 mmHg despite massive colloid and crystalloid administration consisting of four units packed erythrocytes, 9 liters of crystalloid, and 250 ml of plasma protein fraction.

Upon arrival in the recovery room, a flow-directed pulmonary artery catheter was inserted to assess myocardial function and intravascular volume status. The initial pulmonary artery occlusion pressure was 10 mmHg, falling progressively within minutes to values of 4–5 mmHg. At this time, marked abdominal distension was observed and the vascular surgeons were notified. We immediately returned the patient to the operating room where abdominal exploration revealed hemorrhage within all four abdominal quadrants and a large retroperitoneal hematoma extending from the pelvis to the liver with dissection into the small bowel mesentery. The aorta was cross-clamped and the iliac vessels were traced distally from the aortic bifurcation to the ileoinguinal ligament without evidence of vascular disruption. No gross intraperitoneal hemorrhage was apparent upon release of the cross clamp. Inspection of the large and small bowels failed to reveal any site of bleeding. Nine additional units packed erythrocytes, four units fresh frozen plasma, 500 ml plasma protein fraction, 6.0 liters crystalloid and vasopressors were infused to maintain arterial blood pressure. In the recovery room, hypotension persisted despite administration of crystalloids, packed erythrocytes, and vasopressor infusions. Since a bleeding source was not identified during the emergency laparotomy, undiagnosed hemorrhage into the retroperitoneum continued and the patient died in the recovery room having intractable ventricular arrhythmias and hypotension. At autopsy, the right internal iliac artery was surrounded by extensive hematoma with approximately 2,000 ml of blood extending into the retroperitoneum. Although no gross tears could be observed in the internal iliac artery or its branches, a leak in the area of the branching of the gluteal vessels could be clearly demonstrated when the vessel was cannulated and injected with water.

DISCUSSION

Hypotension, as defined by a greater than 25% decrease from the patient's "normal" systolic blood pressure, is not uncommon during hip surgery, and may approach an incidence as high as 45%.⁵ The differential

diagnosis includes hypovolemia, myocardial dysfunction, pulmonary venous or fat emboli, absorption of methylmethacrylate monomer, and a high level of sympathetic block following regional anesthesia. Arterial hypoxemia and hypocarbia generally accompany hemodynamically significant pulmonary embolism. Although our patient was spontaneously hyperventilating prior to endotracheal intubation, he was not hypoxemic, nor were the other etiologic factors listed above likely, except for hypovolemia.

Coventry *et al.*,⁶ in more than 2,000 total hip arthroplasties, noted no case of traumatic perioperative vascular injury. Documented vascular complications have been related to retractor injury, thermal injury from methylmethacrylate polymer, bone fragment laceration, and penetration from acetabular curettage.^{1-4,7} In all of these cases, however, either the injury was apparent at the operative site, or a delayed diagnosis was made on the basis of hematoma or pseudoaneurysmal formation. In our patient, the extent of hemorrhage was not manifested until massive retroperitoneal dissection (fig. 1) produced abdominal signs, and the site of hemorrhage remained unidentified until autopsy. Because of the acute onset of hypotension, we believe the gluteal artery sustained mechanical injury intraoperatively. A less likely possibility is that the gluteal artery was injured when the patient fell, and that subsequent manipulation of the hip during surgery aggravated the injury. Radiation to the right sacroiliac joint two years prior to surgery may have predisposed these vessels to injury. Sheline and Phillips⁸ state that the late effects of radiation therapy to vasculature may appear months to years after cessation of treatment and may consist of prevention of endothelial cell proliferation, endarteritis, obliteration of capillary lumina, atrophy, fibrosis, or ulceration. Examination of our patient's iliac vessels showed fibrosis of periadventitial connective tissue, which is consistent with predicted radiologic changes.

In summary, earlier diagnosis of the site of vascular disruption might have altered the outcome of this case. Knowledge that occult vascular injury of the gluteal vessels can occur during hip surgery would have benefited the attempted vascular surgical intervention. With this information, emergency laparotomy and a more definitive vascular surgical approach to include internal iliac artery ligation may have commenced earlier. Occult retroperitoneal hemorrhage from gluteal artery injury during hip surgery under subarachnoid block has not been reported previously. We document the need to include this entity in the differential diagnosis of intraoperative hypotension during hip surgery. We believe early diagnosis is crucial in directing immediate and appropriate emergency therapy.

The authors acknowledge Stephanie McCann for her excellent illustration and Nina Sanders for her help in preparing the manuscript.

REFERENCES

1. Green DL: Complications of total hip replacement. *South Med J* 69:1559-1564, 1976
2. Anst JC, Bredenberg CE, Murray DG: Mechanisms of arterial injuries associated with total hip replacement. *Arch Surg* 116:345-349, 1981
3. Whithill R, Wang G, Edwards JR, Stamp WG: Late injuries to femoral vessels after fracture of the hip. *J Bone Joint Surg* 60:541-542, 1978
4. Oppenheim WL, Harley JD, Lippert FG: Arteriographic management of postoperative bleeding following major hip surgery. *J Bone Joint Surg* 57:127-128, 1975
5. Stehling, LC: Anesthetic considerations for the patient with a fractured hip, *Anesthesia for Orthopedic Surgery*. Edited by Zauder HL. Philadelphia; FA Davis Co, 1980, p 57
6. Coventry MB, Beckenbaugh RD, Nolan DR, Ilstrup MS: 2,012 Total hip arthroplasties: A study of postoperative course and early complications. *J Bone Joint Surg* 56-A:273-284, 1974
7. Horton RE: Arterial injuries complicating orthopaedic surgery. *J Bone Joint Surg* 54:323-327, 1972
8. Fu KK, Sheline GE, Phillips TL: Radiation therapy: Basic principles and clinical applications, *Current Surgical Diagnosis and Treatment*. Edited by Dunphy JE, Way LW. Los Altos, CA, Lange Medical Publications, 1979, p 79