

Anesthesiology
58:565-566, 1983

Pacemaker Malfunction Associated with Positive-pressure Ventilation

SOMASUNDARAM THIAGARAJAH, M.D., F.F.A.R.C.S.* ISAAC AZAR, M.D.,†
MILDRED AGRES, M.D.,‡ ERWIN LEAR, M.D.§

Pacemaker malfunction because of an electrode catheter displacement may be caused by muscular exertion,^{1,2} to-and-fro motion as in an automobile accident,³ and by blunt trauma to the chest.⁴ Pacemaker malfunction as a result of positive-pressure ventilation is described below.

REPORT OF A CASE

A 70-year-old man, with peripheral vascular disease secondary to long-standing diabetes mellitus, was scheduled for left popliteal-tibial bypass surgery. The patient had sustained myocardial infarction four years earlier, but recovered without sequelae. On his current admission, he was found to have atrial flutter, with a 4:1 block and apical heart rate of 50 bpm. Because of his 3+ pedal edema, digoxin, 0.125 mg, po, was started, but following the second dose the heart rate decreased to 40 bpm. A temporary pacemaker then was inserted preoperatively.

The demand pacemaker was set for a rate of 50 bpm, output of 7 milliamperes (mA), and threshold of 0.3 mA. Chest roentgenogram, taken following the insertion of the electrode catheter, confirmed the proper placement of its tip in the right ventricle, and the ECG showed satisfactory function of the pacemaker.

Surgery was started with spinal anesthesia and the patient tolerated the procedure well. After 3.5 hours of surgery, the spinal block dissipated and general anesthesia was induced. Thiopental, 250 mg, iv, and 50% nitrous oxide with 1.5% enflurane was delivered via a face mask. As the patient reacted to inserting an oral airway, succinylcholine, 30 mg (after 10 mg self-taming dose), was administered iv and positive-pressure ventilation established. Coincident with the beginning of positive-pressure ventilation, the pacemaker failed to capture, the peripheral pulse disappeared, and the heart sounds were not audible. The nitrous oxide and enflurane were discontinued, pacemaker output was increased to the maximum. When the face mask was removed to intubate the trachea, the ECG monitor showed pacemaker captured ventricular complexes and the pulse amplitude reappeared. No attempt was made to intubate the trachea because the surgery was concluding and positive-pressure ventilation was recommenced with the face mask. Similar short episodes of pacemaker failure occurred

each time positive-pressure ventilation was attempted (fig. 1). Atropine, 0.8 mg, and ephedrine, 10 mg, given iv produced supraventricular tachycardia of 110 bpm. Analysis of arterial blood gases determined immediately following the incident were pH_a 7.49, Pa_{CO_2} 34 mmHg, Pa_{O_2} 160 mmHg, and serum potassium was 4.15 mEq/l. Thirty minutes later, with the patient breathing spontaneously, the pacemaker functioned properly.

At the conclusion of surgery the heart rate and arterial blood pressure were stable and recovery from anesthesia was uneventful.

DISCUSSION

This case demonstrates another possible mechanism of pacemaker malfunction. The three most common causes for pacemaker failure are battery failure, increased threshold, and displacement of the electrode catheter.⁵ When the battery fails, the ECG shows a decrease in amplitude and frequency of the spikes.⁵ In our case, neither occurred with no resultant need to replace the battery in order to reestablish the normal function of the pacemaker. An increase in the threshold induced by anesthetic drugs is unlikely since an increase in the pacemaker output to maximum did not restore normal function. Changes in the thresholds resulting from hypoxemia or abnormal serum potassium levels were ruled out by analysis of arterial blood gases and serum potassium determinations.

The association of the pacemaker failure with positive-pressure ventilation was temporally related and reproducible. Although postoperative chest roentgenogram showed no change in the position of the top of the electrode catheter, positive-pressure ventilation may have caused transient displacement of the catheter.

The exact mechanism of catheter displacement by positive-pressure ventilation is not clear. Positive-pressure ventilation causes changes in volume of both ventricles and septal deviation.⁶ Thus, the positive-pressure ventilation in our case may have caused abrupt volume changes in the heart and cardiac septal deviation that in turn displaced the tip of the electrode catheter and resulted in pacemaker failure.

We recommend that patients with pacemakers should have a trial of positive-pressure ventilation before they are paralyzed with a muscle relaxant. If the pacemaker stops capturing, the exact etiologic factor should be identified and treated. But if there is a delay, isopro-

* Assistant Professor of Clinical Anesthesiology.

† Associate Professor of Clinical Anesthesiology and Associate Director.

‡ Resident.

§ Professor and Director.

Received from the Department of Anesthesiology, Beth Israel Medical Center and Mount Sinai School of Medicine (CUNY), Nathan D. Perlman Place, New York, New York 10003. Accepted for publication December 1, 1982.

Address reprint requests to Dr. Thiagarajah.

Key words: Heart: pacemakers; artificial. Ventilation: controlled.

POSITIVE PRESSURE VENTILATION

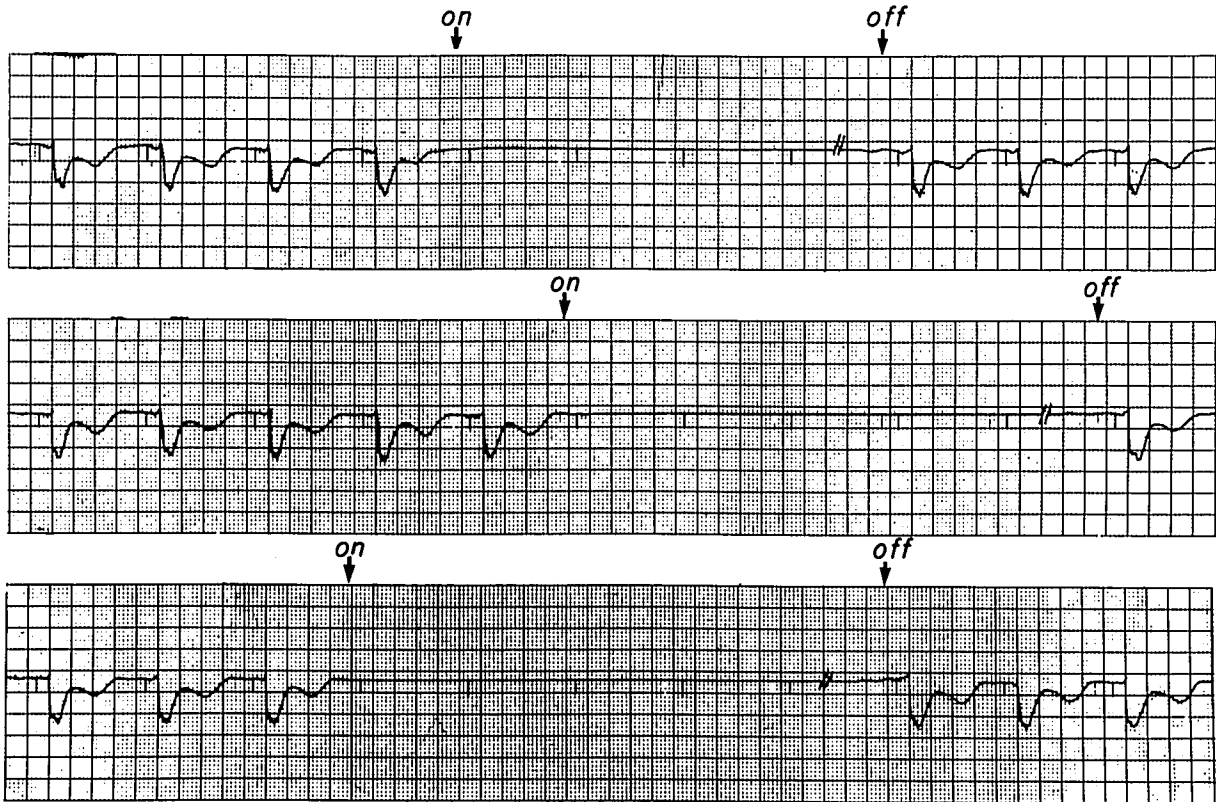


FIG. 1. Pacemaker failure coinciding with positive-pressure ventilation.

terenol infusion at 1–3 $\mu\text{g}/\text{min}$ should be commenced until the pacemaker is replaced.

REFERENCES

1. Ohm OJ: Replacement and fracture of pacemaker electrode during physical exertion. Report on three cases. *Acta Med Scand* 192:33–35, 1972
2. Seremetis MG, DeGuzman VC, Lyons WS, Peabody JW: Cardiac pacemakers. Clinical experience with 289 patients. *Am Heart J* 85:739–748, 1973
3. Lasky II: Pacemaker failure from automobile accident. *JAMA* 211:1700, 1970
4. McCann WJ: Pacemaker malfunction. *NY State J Med* 78:645, 1978
5. Goldberg E: *Treatment of Cardiac Emergencies*. St. Louis, CV Mosby, 1977, pp 245–246
6. Jardin F, Farcot JC, Boisante L, Curren N, Margairaz A, Bourdarias JP: Influence of positive end-expiratory pressure on left ventricular performance. *N Engl J Med* 304:387–392, 1981