

### Dinamap® Adaptation for Neonatal Blood Pressure Determination

*To the Editor:*—By a simple modification of the Dinamap®, blood pressure monitoring in neonates can now be performed easily by fitting a Sherwood Medical Industries large Argyle “Y” connector (8888-272005) to the distal ends of the Dinamap® blood pressure tubing and connecting it to the proximal end of a newborn’s blood pressure cuff; as shown in figure 1. We have found this method useful for neonatal blood pressure measurements, provided periodic inspection of the arm is made to insure against excessive venostasis.<sup>1</sup>

WALTER P. ZMYSLOWSKI, M.D.  
*Assistant Clinical Professor of Anesthesiology  
Boston University School of Medicine  
Staff Anesthesiologist  
Boston City Hospital  
818 Harrison Avenue  
Boston, Massachusetts 02118*

DOROTHY M. LENA, C.R.N.A.  
*Chief Nurse Anesthetist  
Boston City Hospital  
818 Harrison Avenue  
Boston, Massachusetts 02118*

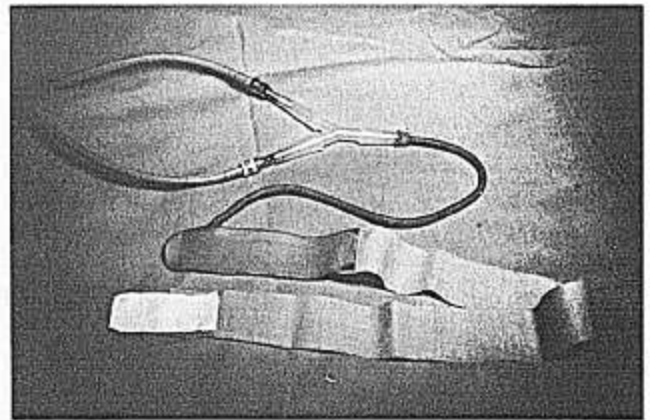


FIG. 1. Dinamap® Neonatal Blood Pressure Adaptation.

#### REFERENCE

1. Showman A, Betts EK: Hazard of automatic non-invasive blood pressure monitoring. *ANESTHESIOLOGY* 55:717-718, 1981

(Accepted for publication November 11, 1982.)

### Permanent Paralysis of the Accessory Nerve after Cannulation of the Internal Jugular Vein

*To the Editor:*—A 40-year-old woman underwent a successful aorto-femoral endarterectomy, during which her internal jugular vein was easily cannulated to monitor the central venous pressure. The cannula was removed in the immediate postoperative period. Two weeks later, she complained of a weak shoulder. Electromyography revealed a paralyzed trapezius muscle. After two years, the paralysis persists along with a winged scapula and constant pain. The scar from the puncture in her neck overlies the spinal accessory nerve as it courses downward and backward across the posterior triangle of the neck to disappear beneath the trapezius muscle.

The lesion has never been described, except as a complication of surgery in the neck. The area is rich in nerves, and it is surprising to me that damage to nerves is not more common following cannulation of the internal jugular vein. As the procedure is used more often,

damage to nerves in the neck may emerge as an important risk. Recently, for example, Frassetto and Belda observed permanent damage to the C5 branch of the brachial plexus caused by this procedure.<sup>1</sup>

The tragic nature of accessory nerve paralysis is stressed by Valtonen *et al.*<sup>2</sup> who examined 14 cases nine years after surgery of the neck. The patients were severely disabled with considerable limitation of movement, and, in almost every case, had constant pain, which was presumed to be caused by stretching of the brachial plexus by the paralyzed shoulder.

There are a variety of approaches to cannulation of the internal jugular vein; most have been described and critically evaluated by Defalque.<sup>3</sup> They are named according to the relationship of the needle to the sternomastoid as the skin is entered: anterior, intermediate, and posterior approaches. The posterior approach was used in the case reported here.

As these techniques receive wider currency, damage to the important spinal accessory nerve may place constraints on the use of the posterior approach to the internal jugular vein.

JOSEPH C. HOFFMAN, M.D.  
Department of Anesthesiology  
St. Joseph Hospital  
Stockton, California 95204

Anesthesiology  
58:584-585, 1983

## REFERENCES

1. Frasquet FJ, Belda FJ: Permanent paralysis of C5 after cannulation of the internal jugular vein. *ANESTHESIOLOGY* 54:528, 1981
2. Valtonen EJ, Lilius GH: Late sequelae of iatrogenic spinal accessory nerve injury. *Acta Chir Scand* 140:452-455, 1974
3. Defalque FJ: Percutaneous catheterization of the internal jugular vein. *Anesth Analg (Cleve)* 53:116-121, 1974

(Accepted for publication November 17, 1982.)

## Potentially Fatal Machine Fault

*To the Editor:*—The Ohio DM5000 Kinet-O-Meter® anesthesia machine with heated vaporizer system is in wide clinical use. Recently, a design-related malfunction occurred with the machine which might easily have resulted in a fatality.

A 2-day-old infant with cyanotic congenital heart disease was brought to the operating room for emergency

cardiac surgery. Anesthesia was induced with ketamine (1 mg/kg) and muscle relaxation provided with pancuronium (0.1 mg/kg). Oxygen flow was set at 5 l/min with mask ventilation and a Jackson-Rees modification of the Ayre's T-piece. Repeated use of the oxygen flush-valve was necessary to maintain a full reservoir bag. A poor-fitting face mask was thought responsible. Follow-

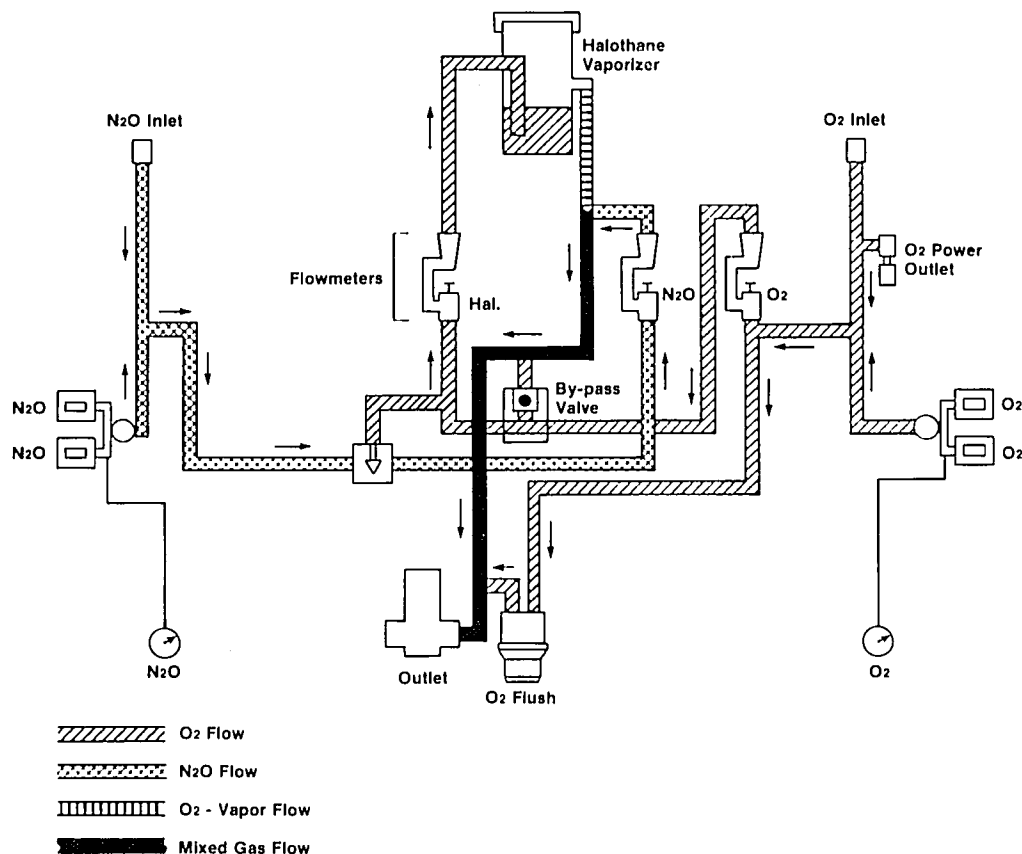


FIG. 1. The Ohio DM5000 machine.