

14. Nisikawa T, Dohi S: Slowing of heart rate during cardiac output measurement by thermodilution. *ANESTHESIOLOGY* 57:538-539, 1982
15. Berne RM, Levy MN: *Cardiovascular Physiology*, St. Louis, CV Mosby, 1981, pp 5-22
16. Surawicz B: The pathogenesis and clinical significance of primary T wave abnormalities, *Advances in Electrocardiography*. Edited by Schlant RD, Hurst JW. New York, Grune and Stratton, 1972, pp 377-421
17. Boyan CP, Howland WS: Cardiac arrest and temperature of bank blood. *JAMA* 183:58-60, 1961
18. Goldberger AL: *Myocardial Infarction: Electrocardiographic Differential Diagnosis*. St. Louis, CV Mosby, 1979, pp 186-194

Anesthesiology  
59:467-469, 1983

## Transient Large Upright T-Wave on the Electrocardiogram during Multiple Monitored Electroconvulsive Therapy

GWENDOLYN GRAYBAR, M.D.,\* JOHN GOETHE, M.D.,† THOMAS LEVY, M.D.,‡ JOHN PHILLIPS, M.D.,§ JOHN YOUNGBERG, M.D.,\* DONALD SMITH, M.D.¶

Large T-waves on the electrocardiogram (ECG) frequently are associated with hyperkalemia and can be a manifestation of intracranial injury.<sup>1</sup> Although many ECG alterations accompany electroconvulsive therapy (ECT),<sup>2-4</sup> large upright T-waves have not been reported.

### REPORT OF A CASE

A 42-year-old woman was admitted with the diagnosis of unipolar affective disorder (major depressive illness). Her weight had decreased from 73 kg to 31 kg. An extensive medical and neuropsychiatric workup revealed no organic basis for her depression or weight loss. She had been hospitalized for a similar episode 4 months prior to the present admission. Initial 12-lead ECGs were interpreted as within normal limits. An ECG taken prior to the fifth ECT session revealed a new finding of mild T doming, suggesting hyperventilation and/or drug effect.

Multiple Monitored Electroconvulsive Therapy (MMECT) is a procedure for administering electroconvulsive therapy, which allows multiple treatments to be given in a single therapy session. The voltage is varied automatically to provide a constant current of 800 milliamps through a bipolar square wave pulse. Typically, the maximum energy administered during MMECT is 69 joules; the average energy is 17.5 joules, compared with an average of 50-100 joules in standard ECT.

During each session, anesthesia was induced with thiopental 150-350 mg and *d*-tubocurarine 3 mg, followed by succinylcholine 100-120 mg iv to facilitate endotracheal intubation. Nitrous oxide 60% and succinylcholine 0.2% as a continuous iv infusion were given for maintenance of anesthesia. A peripheral nerve stimulator was utilized to insure maximal relaxation prior to each stimulus. Hyperventilation

was instituted a minute prior to each stimulus. Large, upright T-waves were noticed first during the fifth session. Simultaneous ECG and EEG tracings returned rapidly to normal after the seizure and were not associated with apparent hemodynamic compromise (fig. 1). Therefore we elected to follow her next treatment session with a twelve lead ECG, as well as serial potassium and CPK levels (fig. 2).

### DISCUSSION

ECG findings in patients with neurologic problems are similar to those described in this report. Burch and Phillips<sup>1</sup> reported a series of 55 patients with a variety of central nervous system conditions including tumors, subarachnoid hemorrhages, and intracerebral hemorrhages, with ECG changes believed to be secondary to their CNS lesions. Seventeen of the 55 patients showed the more classic ECG findings of prolonged QT and large inverted T-waves. Thirty-eight had prominent upright T-waves, prolonged QT, prominent U-waves and TU fusion. The QRS complex was unchanged. Greenspahn's group<sup>5</sup> reported a patient with deep T-wave inversions simulating acute nontransmural myocardial infarction following cerebral concussion alone. The EEG, CT scan, enzymes, echocardiogram, and technetium pyrophosphate scan in their patient revealed neither CNS nor cardiac pathology.

An imbalance in sympathetic tone to the heart is believed to be the mediating mechanism in ECG findings with CNS lesions.<sup>6</sup> Yanowitz *et al.*<sup>7</sup> found in dogs that right stellate ganglionectomy or left stellate stimulation would produce prolonged QT intervals and increased amplitude of T-waves. Left stellate ganglionectomy or right stellate stimulation produced increased T-wave negativity without measurable change in the QT interval. In contrast, Rogers' *et al.*<sup>8</sup> showed in cats right or left stellate ganglion block resulted in diphasic T-waves of lower amplitude. Stimulation of the right stellate ganglion in the cat increased the amplitude of the T-waves, while stimulation of the left stellate produced deeply inverted

\* Associate Professor, Department of Anesthesiology.

† Associate Professor, Department of Psychiatry.

‡ Assistant Professor, Department of Medicine.

§ Professor, Department of Medicine.

¶ Assistant Professor, Department of Anesthesiology.

Received from the Departments of Anesthesiology, Psychiatry, and Medicine, Tulane University School of Medicine, New Orleans, Louisiana, Accepted for publication April 15, 1983.

Address reprint requests to Dr. Graybar: Department of Anesthesiology, Tulane Medical Center, 1430 Tulane Avenue, New Orleans, Louisiana 70112.

Key words: Anesthesia: electroshock. Heart: enlarged T-waves.

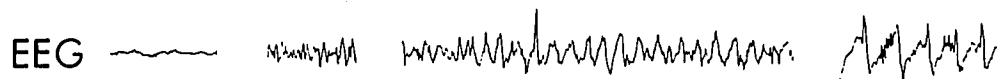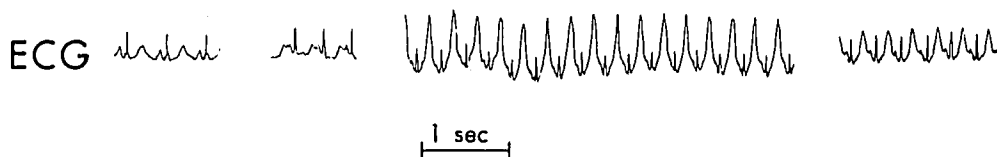


FIG. 1: Simultaneous ECG and EEG tracings taken during seizure 15 of 5th from MECTA apparatus.

Baseline      3seconds      15 seconds      1 minute

T waves. In the human, Rogers *et al.*<sup>9</sup> found that right stellate ganglion block decreased the heart rate, whereas left stellate ganglion block did not change the heart rate. Hugenholtz<sup>10</sup> described a patient with deeply inverted T-waves following right stellate ganglionectomy after radical neck dissection. The changes and clinical course were more consistent with the CNS pattern.

Electroconvulsive therapy is accompanied by both ECG changes and sympathetic stimulation. Troup *et al.*<sup>2</sup> followed their patients with Holter monitoring 24 h prior to and 24 h after ECT. Following single ECT, the mean heart rate increased from 106 to 142 beats/min. The PR interval decreased, while the QT interval increased. Tachycardia generally is associated with a decrease in the QT interval. Troup *et al.*<sup>2</sup> attributed the prolonged QT

interval during ECT to an imbalance of sympathetic discharge. They did not mention any changes in the T-waves or an increase in either ventricular or atrial ectopic beats. McKenna *et al.*<sup>3</sup> correlated the incidence of ventricular ectopic beats during ECT with respiratory acidosis and recommended hyperventilation prior to ECT.

Methohexital with ECT apparently is associated with fewer ECG abnormalities than thiopental.<sup>4</sup> In the Woodruff *et al.* series,<sup>11</sup> methohexital for induction of anesthesia resulted in one-fourth the incidence of PVCs than did thiopental, as well as one-fourth the incidence of ST depression.

Valentin *et al.*<sup>12</sup> found that thiopental and succinylcholine followed by ECT resulted in an average rise in plasma potassium of about 0.25 mEq/l. In their control

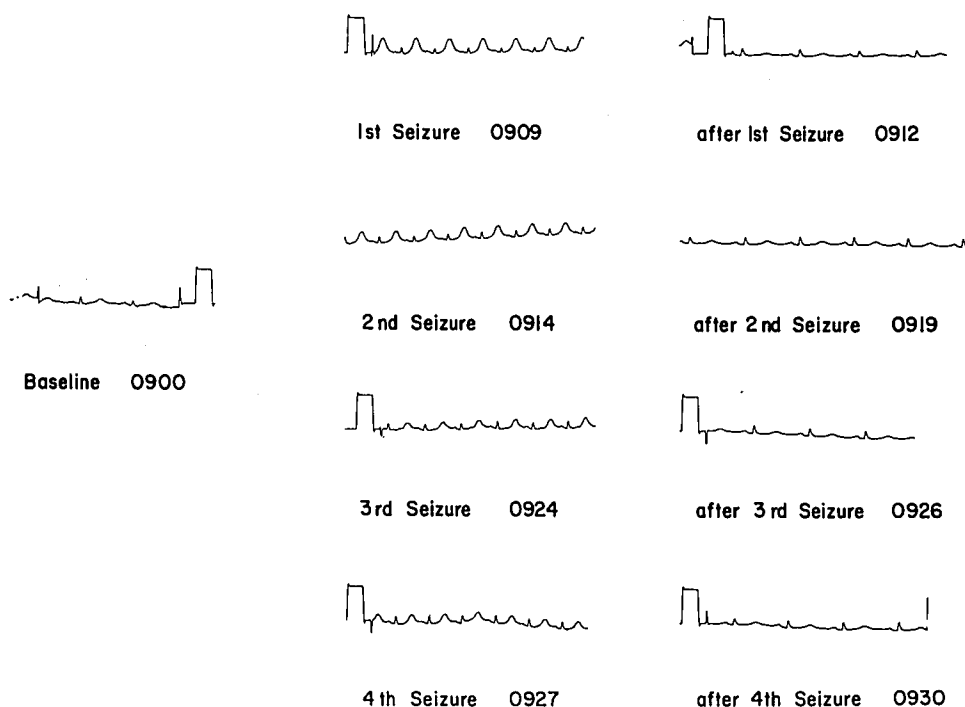


FIG. 2: Lead I of 12-lead ECGs taken during the fifth session. Large, upright T-waves occurred during each of the four seizures and returned rapidly to baseline.

patients scheduled for orthopedic and plastic surgery, the rise was 0.1 mEq/l. Pretreatment with *d*-tubocurarine did not alter the increase in potassium. Our patient's potassium increased from 4.5 to 5.3 mEq/l, nearly three times that reported by Valentin *et al.*<sup>12</sup> However, during the first induced seizure, the T-wave changes were just as prominent during the latter three seizures as during the first, although the potassium had fallen to 4.7, 4.5, and 4.6 mEq/l, respectively.

When succinylcholine is administered to burned patients or those with muscle trauma, denervation, paraplegia, or immobilization, a marked hyperkalemia severe enough to cause cardiac arrest may result. Gronert and Theye<sup>13</sup> reported that starvation potentiated the hyperkalemic response to succinylcholine. Our patient's state of inanition may have made her more susceptible to hyperkalemia secondary to the administration of succinylcholine. Her normal CPK did not change during treatment; no MB bands were done because the initial values were so low.

An increase in the amplitude of the T-wave occurs as the potassium approaches 7 mEq/l<sup>14</sup> and T-waves are described typically as narrow and tent shaped. Our patient's ECG more closely approximated that of the intracranial pattern described by Burch and Phillips<sup>1</sup> than hyperkalemia. The T-waves were wide rather than narrow, and there was no change in the QRS, despite marked increased height of the T-waves; also U-waves were noted on the ECG at the time of the therapy. Additionally, the QT interval was prolonged, consistent with the intracranial pattern.

The transiency of the T-wave changes in our patient is interesting. However, Burch and Phillips<sup>1</sup> did note regression in the ECG changes in their patients following surgical removal of their intracranial lesions. Perhaps electrically induced seizures cause transient intracranial damage.

In summary, acute and transient T-wave changes similar to those described by Burch and Phillips<sup>1</sup> in patients with CNS lesions occurred during ECT. They subsided

immediately with the cessation of the seizure. They were not associated with hyperkalemia and cannot be explained readily on the basis of respiratory acidosis, other drugs, or the anesthetic technique.

#### REFERENCES

1. Burch GE, Phillips JH: The large upright T wave as an electrocardiographic manifestation of intracranial disease. *South Med J* 61:331-336, 1968
2. Troup PJ, Small JG, Milstein V, Small IF, Zipes DP: Effect of electroconvulsive therapy on cardiac rhythm, conduction and repolarization. *Pacing and Electrophysiology* 1:172-177, 1978
3. McKenna G, Engle RP, Brooks H, Dalen J: Cardiac arrhythmias during electroshock therapy: significance, prevention, and treatment. *Am J Psychiatr* 127:530-533, 1970
4. Pitts FN Jr, Desmaris GM, Steward W, Schabey R: Induction of anesthesia with methohexital and thiopental in electroconvulsive therapy. *N Engl J Med* 273:353, 1975
5. Greenspahn BR, Barzilai BS, Denes P: Electrocardiographic changes in concussion. *Chest* 74:468-469, 1978
6. Abildskov JA, Millar K, Burgess MJ, Vincent W: The electrocardiogram and the central nervous system. *Prog Cardiovasc Dis* 13:210-216, 1970
7. Yanowitz F, Preston JB, Abildskov JA: Functional distribution of right and left stellate innervation to the ventricles: Production of neurogenic electrocardiographic changes by unilateral alteration of sympathetic tone. *Circ Res* 18:416-428, 1966
8. Rogers MC, Abildskov JA, Preston JB: Cardiac effects of stimulation and block of the stellate ganglion. *ANESTHESIOLOGY* 39:525-533, 1973
9. Rogers MC, Battit G, McPeck B, Todd D: Lateralization of sympathetic control of the human sinus node: ECG changes of stellate ganglion block. *ANESTHESIOLOGY* 48:139-141, 1978
10. Hugenholtz PG: Electrocardiographic changes typical for central nervous system disease after right radical neck dissection. *Am Heart J* 74:438-441, 1967
11. Woodruff RA, Pitts FN, McClure JN: The drug modification of ECT, I. Methohexital, thiopental, and preoxygenation. *Arch Gen Psychiatr* 18:605-611, 1968
12. Valentin N, Skovsted P, Danielsen B: Plasma potassium following suxamethonium and electroconvulsive therapy. *Acta Anaesth Scand* 17:197-202, 1973
13. Gronert GA, Theye RA: Pathophysiology of hyperkalemia induced by succinylcholine. *ANESTHESIOLOGY* 43:89-99, 1975
14. Herndon EG, Wenger NK: The effects of endocrine dysfunction and metabolic disorders on the heart, *The Heart*. Edited by Hurst JW, Logue RB. New York, McGraw-Hill, 1966, p 1081