

# CLINICAL REPORTS

Ronald D. Miller, M.D., Editor

Anesthesiology  
60:144-147, 1984

## The Anesthetic Management of the Patient with an Anterior Mediastinal Mass

GEORGE G. NEUMAN, M.D.,\* ALEXANDER E. WEINGARTEN, M.D.,† ROY M. ABRAMOWITZ, M.D.,‡  
LAWRENCE G. KUSHINS, M.D.,‡ ALAN L. ABRAMSON, M.D.,§ WILLIAM LADNER, M.D.‡

Severe respiratory and cardiovascular complications have been described in patients with an anterior mediastinal mass. Obstruction of major airways,<sup>1-3</sup> superior vena caval obstruction,<sup>4</sup> and cardiac compression<sup>1</sup> are potential problems to be anticipated during general anesthesia. Three such cases are presented and the anesthetic approach to these patients is discussed.

### REPORTS OF THREE CASES

*Case 1.* A 13-year-old 50-kg boy was scheduled to undergo cervical node biopsy under general anesthesia. He had a 4-week history of a dry cough. One week prior to admission he had mild facial swelling, one pillow orthopnea, and shortness of breath while playing football. On physical examination he had mild facial edema, bilateral paracervical and left supraclavicular adenopathy, tubular but equal breath sounds bilaterally. Chest roentgenogram demonstrated a large anterior mediastinal mass with no tracheal deviation noted. Anesthesia was induced with 200 mg of thiamylal iv. Ventilation was controlled easily, and 40 mg of succinylcholine was administered iv followed by endotracheal intubation with a 7-mm cuffed tube. Following intubation, ventilation was impossible. The endotracheal tube was removed immediately, but ventilation via a mask was also unsuccessful. The trachea was reintubated rapidly and ventilation controlled for about 4 min, at which time adequate ventilation again became difficult to achieve. Within 2 min, a tracheostomy was performed but the airway remained completely obstructed. Two minutes later, a cardiac arrest occurred and cardiopulmonary resuscitation was instituted. A ventilating bronchoscope

was inserted. Total occlusion of the trachea starting 2-3 cm above the carina and extending to both main stem bronchi was observed. The bronchoscope was passed through the obstruction, and ventilation resumed about 4 min following the arrest. Resuscitation was unsuccessful. Autopsy demonstrated a lymphosarcoma that infiltrated the carina, lungs, pericardium, and myocardium, and was adherent to the chest wall.

*Case 2.* A 16-year-old 68-kg boy who had been radiated for mediastinal Hodgkin's disease was scheduled for a staging laparotomy. Six weeks previously, he had severe chest pain, cough, night sweats, loss of appetite, and a palpable 2-cm chest wall nodule over the right fourth anterior rib. Following the biopsy he underwent 13 radiation treatments with a subsequent decrease in the severity and incidence of cough, dyspnea, sweats, chest pain, and an improvement in appetite. On physical examination the nodule was noted, and breath sounds were clear and equal bilaterally. Chest roentgenogram revealed no evidence of tracheal deviation or constriction but marked hilar adenopathy. Anesthesia was induced with 200 mg of thiamylal iv, isoflurane, and nitrous oxide. Spontaneous ventilation was maintained following endotracheal intubation. Metocurine (12 mg) subsequently was administered iv, and ventilation was controlled easily. Following an uneventful staging laparotomy and splenectomy, paralysis was reversed with neostigmine 2.5 mg and atropine 1.0 mg iv. The patient was transferred to the recovery unit breathing spontaneously with the trachea intubated. After 15 min the patient became tachypneic and demonstrated chest wall retraction. Breath sounds were absent on the left. With a  $FI_{O_2}$  of 0.5,  $pH_a$  was 7.28,  $Pa_{CO_2}$  54 mmHg,  $Pa_{O_2}$  142 mmHg. Chest roentgenogram showed the endotracheal tube to be in proper position. Fiberoptic bronchoscopy through the tube revealed extrinsic compression of the left main stem bronchus on inspiration. The trachea was extubated successfully following 30 min of positive-pressure ventilation and after complete emergence from the anesthetic. The remainder of his hospital course was uneventful.

*Case 3.* A 13-year-old 55-kg boy with an anterior mediastinal mass was scheduled for biopsy. He had been in good health until 3 days prior to admission, when mild chest pain developed that increased on inspiration. His appetite had decreased during this period and he had a low-grade fever. Physical examination was normal except for mildly decreased breath sounds bilaterally. Chest roentgenogram revealed a 7-cm right anterior mediastinal mass. Computerized axial tomography showed the mass at the level of the carina but not compressing the airway. Standard pulmonary function tests including a flow volume loop were performed in the upright and supine positions. Peak flow rate was reduced mildly in the upright position with the remainder of the variables within normal limits. In the supine position there were marked reductions in  $FEV_{1.0}$  and peak flow rates. The flow volume loop (fig. 1) demonstrated a plateau on the expiratory limb of the loop with the patient in the supine position. It was elected to perform the biopsy under local anesthesia. The local anesthetic was supplemented with diazepam 15 mg and fentanyl citrate 0.1 mg iv. The biopsy revealed Hodgkin's disease. The patient was discharged and underwent mantle radiation to the mediastinum for 2 weeks at which

\* Clinical Assistant Professor of Anesthesiology, State University of New York at Stony Brook; Physician-in-Charge, Pediatric Anesthesiology, Long Island Jewish-Hillside Medical Center.

† Chief Resident in Department of Anesthesiology at Long Island Jewish-Hillside Medical Center.

‡ Clinical Assistant Professor of Anesthesiology, State University of New York at Stony Brook; Attending Anesthesiologist at Long Island Jewish-Hillside Medical Center.

§ Associate Professor of Otolaryngology, State University of New York at Stony Brook; Chairman, Department of Otolaryngology, Long Island Jewish-Hillside Medical Center.

Received from the Department of Anesthesiology, State University of New York at Stony Brook, Stony Brook, New York, and the Departments of Otolaryngology and Anesthesiology, Long Island Jewish-Hillside Medical Center, New Hyde Park, New York. Accepted for publication June 21, 1983.

Address reprint requests to Dr. Neuman: Department of Anesthesiology, Long Island Jewish-Hillside Medical Center, New Hyde Park, New York 11042.

Key words: Airway; obstruction; mediastinal mass.

time he returned for staging laparotomy. The mass had decreased in size on chest roentgenogram. Pulmonary function tests including a flow volume loop (fig. 2) revealed essentially normal airway mechanics in the upright and supine positions demonstrating a marked improvement when compared with the preradiation studies. He underwent the procedure under general endotracheal anesthesia without difficulty and was discharged subsequently.

### DISCUSSION

The preoperative diagnosis of an anterior mediastinal mass should alert the anesthesiologist to a potentially life-threatening situation. Numerous reports in the literature describe major airway obstruction in these patients while under general anesthesia.<sup>1-3</sup> Keon<sup>1</sup> described a patient with an anterior mediastinal mass who arrested during induction of anesthesia and was unable to be resuscitated. At autopsy the tumor was found enveloping the heart and infiltrating the pericardium. Case 1 illustrates the futility of trying to control ventilation of a patient with distal tracheobronchial obstruction through the proximal airway. Similarly, our patient had extensive mediastinal involvement including pericardial and myocardial infiltration by the tumor. Preoperative cardiac assessment should include electrocardiography and echocardiography in patients who are symptomatic. Piro *et al.*<sup>2</sup> showed nearly a 10% incidence of acute life-threatening airway complications in a large group of patients with mediastinal Hodgkin's disease undergoing staging laparotomy. A number of these patients were asymptomatic and showed no airway compression on chest roentgenogram. Piro *et al.*<sup>2</sup> recommend that radiation therapy be undertaken prior to general anesthesia whenever possible.

The response of lymphomatous tumors to radiation or chemotherapy is normally dramatic. Chest roentgenograms reveal a marked decrease in tumor size, and symptoms are usually improved, yet Case 2 illustrates a patient who responded to radiation therapy with a diminution in tumor size and improvement in symptoms but who developed airway obstruction during emergence from general anesthesia. Following radiation or chemotherapy, the radiologic appearance of the tumor must be reviewed, however, a dynamic evaluation of pulmonary function such as an upright and supine flow volume loop may be helpful.

Although most anterior mediastinal masses are lymphomatous in origin, a number of benign conditions such as cystic hygroma, teratoma, and thymoma can present in a similar fashion. A tissue diagnosis, therefore, is mandatory before radiation or chemotherapy can be undertaken. The patient presented in Case 3 required biopsy of the tumor mass for diagnosis. Preoperative computerized axial tomography (CAT scan) revealed no airway obstruction. The pulmonary flow volume loop, however, revealed a significant decrease in peak flow rate with the patient in the supine position. This pattern is consistent

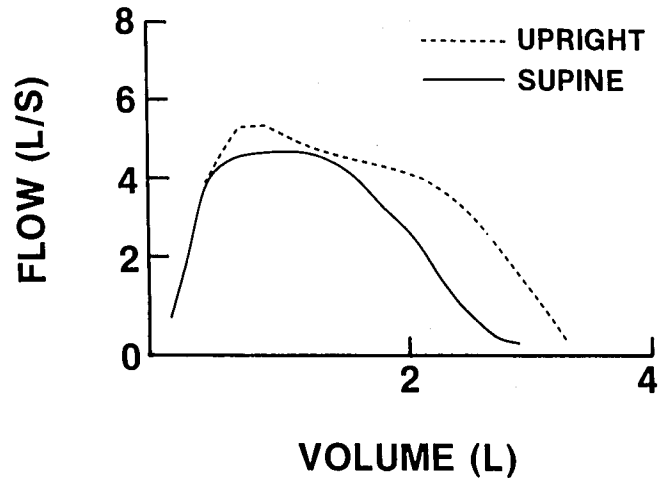


FIG. 1 (Case 3). Flow volume loop before radiation therapy in upright and supine positions. Marked reduction in vital capacity and expiratory flow rates. The expiratory flow rate plateaus, which is indicative of an intrathoracic airway obstruction.

with intrathoracic airway obstruction, and the procedure was performed under local anesthesia as described. The flow volume loop graphically relates the instantaneous air flow rate (ordinate) to the lung volume (abscissa).<sup>5</sup> The dynamic nature of this technique makes it an extremely sensitive tool for evaluating obstructive lesions of the major airways.<sup>6</sup> The inspiratory limb of the flow volume loop is useful in diagnosing extrathoracic airway obstruction, and the expiratory limb is sensitive to intrathoracic airway obstruction. During inspiration, the pleural pressure is markedly negative compared with the intratracheal pressure. This tends to increase airway diameter and minimize the effects of intrathoracic airway obstruction.<sup>7</sup> The upright and supine flow volume loops from Case 3 are illustrated in figure 1 and show the

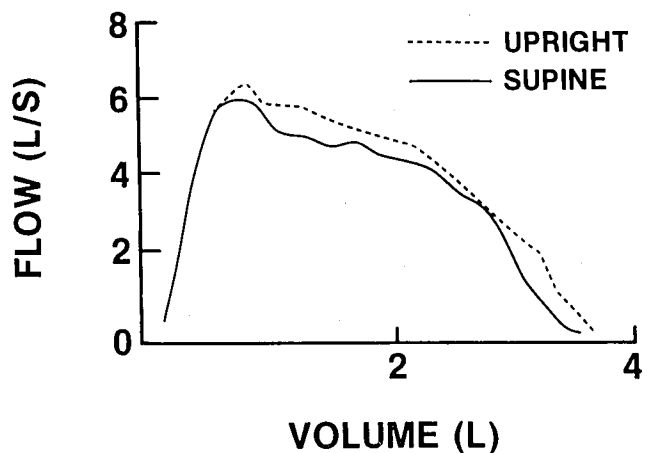


FIG. 2 (Case 3). Flow volume loop after radiation therapy in upright and supine positions. Improvement in expiratory flow rates and vital capacity with minimal change when supine.

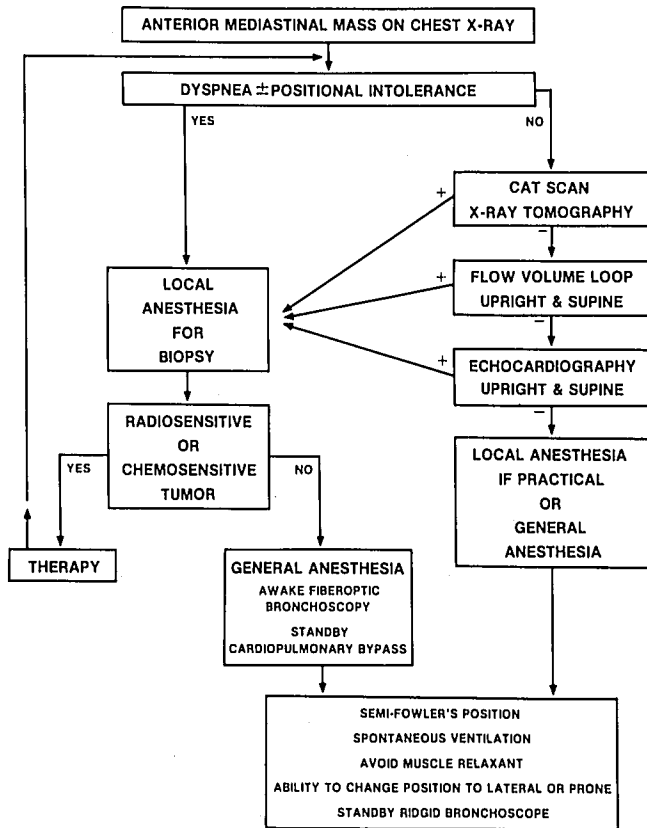


FIG. 3. Flow chart describing the preoperative evaluation of the patient with an anterior mediastinal mass. + indicates positive finding, - indicates negative work-up.

expiratory plateau seen with extrinsic intrathoracic airway obstruction.

Airway obstruction due to a mediastinal mass will vary with the respiratory cycle and the position of the patient. Radiographic techniques including the CAT scan fall short in that they are static studies of a dynamic process. The preoperative pulmonary evaluation of these patients should define the potential for airway obstruction. General anesthesia will exacerbate extrinsic airway compression in at least three ways. First, during general anesthesia, lung volume is reduced about 500 to 1,500 ml.<sup>8</sup> This is secondary to the increase in abdominal muscle tone and a decrease in inspiratory muscle tone. Second, the bronchial smooth muscle is relaxed during general anesthesia, the compressibility of the large airways increases, and a decrease in expiratory flow rate ensues. This will exacerbate the effects of extrinsic compression.<sup>9</sup> Finally, paralysis eliminates the movement of the diaphragm in a caudal direction seen during spontaneous respiration. The normal transpleural pressure gradient, which dilates the airways during inspiration, will be reduced, the caliber of the airways will be decreased, and the effect of extrinsic compression will be increased.<sup>9</sup> In Case 2, partial bronchial

compression was observed during inspiration upon emergence from the anesthetic. Obstruction during inspiration is more typical of an extrathoracic mass. However, during emergence a diaphragmatic mode of respiration with minimal chest wall motion can cause an intrathoracic mass to obstruct the airway during inspiration in the supine position. As the intercostal component becomes more prominent, the obstruction is minimized. This is likely to occur when the mass is fixed to the chest wall as in this case. Positive pressure ventilation was successful in treating this obstructive pattern until the patient has resumed a normal pattern of ventilation.

Figure 3 illustrates the approach to the patient with an anterior mediastinal mass. If signs or symptoms of airway compression, cardiac compression, or superior vena caval obstruction exist, general anesthesia should be avoided. In the asymptomatic patient, the series of noninvasive studies listed should be performed to rule out occult airway and/or cardiac involvement. An upright and supine flow volume loop, we feel, is the most sensitive noninvasive study for the diagnosis of airway obstruction. General anesthesia should be avoided if any of the tests are positive. Biopsies should be performed under local anesthesia and chemotherapy or radiation therapy should be instituted before the patient is reevaluated as a candidate for general anesthesia. For the patient who cannot be treated prior to a general anesthetic, such as, for the resection of a biopsy-proven benign, radioinsensitive, or chemoinsensitive tumor, a number of precautions must be taken. Awake fiberoptic bronchoscopy to assess the degree of obstruction and the airway distal to the obstruction should be performed in older children and adults. Femoral vein to femoral artery cardiopulmonary bypass should be available at the time of induction. The remainder of the precautions listed in figure 3 should be followed for all patients with anterior mediastinal masses who require general anesthesia.

In summary, the patient with an anterior mediastinal mass is at great risk for general anesthesia and should be evaluated in an organized way that emphasizes the dynamic nature of the disease process.

#### REFERENCES

1. Keon TP: Death on induction of anesthesia for cervical node biopsy. *ANESTHESIOLOGY* 55:471-472, 1981
2. Piro AH, Weiss DR, Hellman S: Mediastinal Hodgkin's Disease: a possible danger for intubation anesthesia. *Int J Radiat Oncol Biol Phys* 1:415-419, 1976
3. Bittar D: Respiratory obstruction associated with induction of general anesthesia in a patient with mediastinal Hodgkin's disease. *Anesth Analg* 54:399-403, 1975
4. Lokich JL, Goodman R: Superior vena cava syndrome. *JAMA* 231:58-61, 1975

5. Comroe JH: Physiology of respiration an introductory text, second edition. Chicago, Year Book Medical Publishers Inc., 1974, pp 134-155
6. Abramson AL, Goldstein M, Stenzler A, Steele A: The use of the tidal breathing flow volume loop in laryngotracheal disease of neonates and infants. *Laryngoscope* 92:922-926, 1982
7. Benumof JL: Respiratory physiology and respiratory function during anesthesia. *Anesthesia*. Edited by Miller RD. New York, Churchill Livingstone, 1981, pp 712-713
8. Bergmann NA: Reduction in resting end-expiratory position of the respiratory system with induction of anesthesia and neuromuscular paralysis. *ANESTHESIOLOGY* 57:14-17, 1982
9. DeGraff AC, Bouhuys A: Mechanics of airflow in airway obstruction. *Ann Rev Med* 24:111-134, 1973

Anesthesiology  
60:147-148, 1984

## Unilateral Cervical Epidural

RICHARD F. H. CATCHLOVE, M.D.,\* AND MICHEL GERMAIN, M.D.†

Unilateral and partial epidural block is reported occasionally,<sup>1,2</sup> but relatively rarely considering the frequency of lumbar epidural analgesia. A much less frequently performed block is that of the cervical region, which finds its main application in treatment of chronic pain such as tension-induced neck pain and headache. We also have observed in this region unilateral or partial block and in the following, we report one such case and its investigation.

### REPORT OF A CASE

A 48-year-old man complained of dorsal and lumbar pain that had developed while he was working on an assembly line. Occasionally he was treated by his family physician and an orthopedic surgeon with physiotherapy without improvement. He started to complain of occasional numbness in the right hand. The remainder of his medical history was unremarkable, apart from minor changes seen on cervical roentgenogram. Two years ago he quit work because of the pain and continued to seek medical treatment, without relief. On examination, nothing remarkable was found apart from some suboccipital and cervical tenderness. There was no sensory deficit. He was diagnosed as having anxiety/depressive neurosis, tension headaches and possibly, subclinical osteoarthritis. A treatment program of cervical epidural block with local anesthetic, transcutaneous nerve stimulation, antidepressant medication, and psychotherapy was instituted.

The cervical epidural was performed by placing the patient in the sitting position and flexing him forward on a pillow. Local analgesia was injected around the C7-T1 interspace. The epidural space was located using the hanging drop method and confirmed by loss of resistance to air. Lidocaine 1.5%, 2 ml, was injected into the epidural space, and a catheter was inserted cephalad for several centimeters. After securing the catheter, the patient was placed in the supine position, and a further 5 ml lidocaine 1.5% was injected. The patient was found to have no analgesia to needle prick on the right hand side, although there was a block from C3 to T1 on the left. Further injection of lidocaine was without affect, and all modalities remained intact on the right side. One week later, the procedure was repeated with the same result. On this occasion, a cervical epidurogram was done using metrizamide 200 mgI<sub>2</sub>/ml. A volume of 7 ml was injected, and roentgenograms were taken. A further 7 ml was injected, and more roentgenograms were taken. There appeared to be less dye on the right side of the cervical epidural region than on the left. One week later the same procedure was repeated when there was again a unilateral block. This time a much smaller volume (2 ml) of metrizamide (300 mgI<sub>2</sub>/ml) initially was injected, and there was clearly a deficit in filling on the right side (fig. 1). Subsequent injection of metrizamide filled the entire epidural space, but there remained less density in the right cervical region.

The other therapeutic modalities were continued during this time. Currently the patient complains of less pain, is less depressed, sleeps better, and is looking for work.

### DISCUSSION

This case illustrates that unilateral epidural block in the cervical region can be related to failure of distribution of the local anesthetic to one or the other side. This occurred in one case reported by Shanks<sup>1</sup> and was not seen in cervical roentgenograms by Jacobs and McCormick<sup>3</sup> or in the lumbar and thoracic epidurograms by Bromage *et al.*<sup>4</sup> The actual cause could not be determined from these results. The catheter placement probably was not at fault, since the same unilateral block was produced repeatedly and metrizamide spread freely in all directions except into the right cervical epidural space. A septum seems an unlikely explanation, since entry of

\* Director, Pain Management Unit, Royal Victoria Hospital; Assistant Professor, Department of Anesthesia, McGill University.

† Senior Resident, McGill Anesthesia Residency Training Program, McGill University.

Received from the Pain Management Unit, Royal Victoria Hospital, 687 Avenue des Pins Ouest, Montreal, Quebec, and the Department of Anesthesia, McGill University, Montreal, Canada. Accepted for publication June 27, 1983.

Address reprint requests to Catchlove: Pain Management Unit, Royal Victoria Hospital, 687 Avenue des Pins Ouest, Montreal, Quebec, H3A 1A1.

Key words: Anesthetic techniques: epidural, cervical. Complications: unilateral block.