

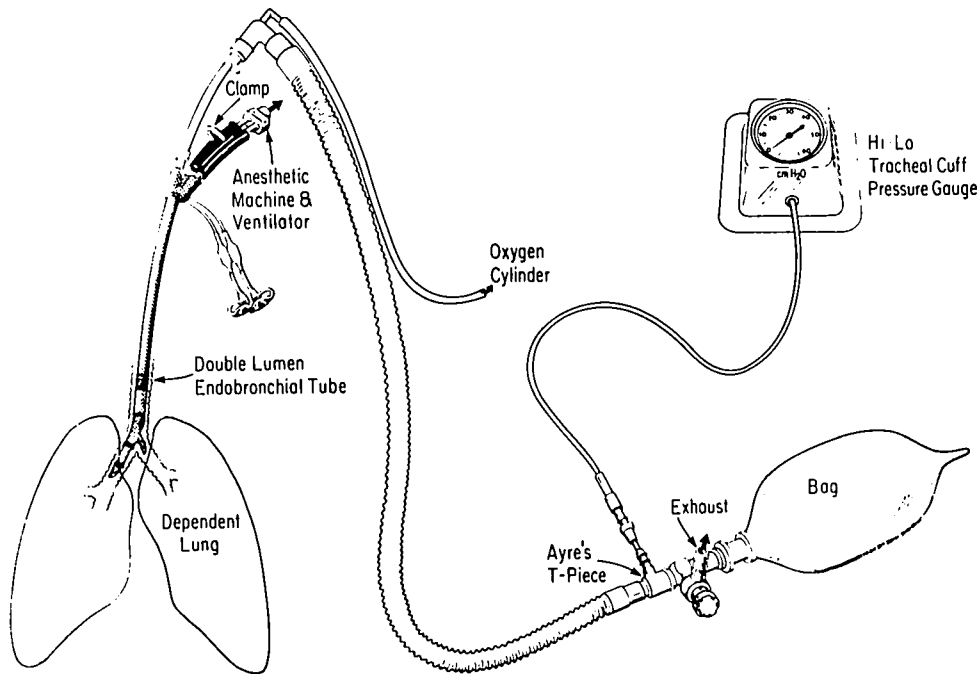FIG. 1. The device, consisting of a pediatric system, endotracheal cuff pressure gauge, and an exhaust valve, for applying CPAP during one-lung ventilation.

pressure gauge,[†] Ayre's T piece,[‡] and a standard oxygen cylinder with pressure gauge and a flow meter (fig. 1). Using this system, we found that by adjusting the exhaust valve and the oxygen flow, the CPAP can be monitored and quantitated as required.

SOMASUNDARAM THIAGARAJAH, M.D., F.F.A.R.C.S.
Assistant Professor of Clinical Anesthesiology

[†] National Catheter Company. Hi-Lo Tracheal Pressure Gauge. Cat. #518.

[‡] Vital Signs. Ayre's T piece with fresh gas flow at 90° angle. Cat. #518.

CARLA JOB, M.D.
Assistant Professor of Clinical Anesthesiology
ANITA RAO, M.D.
Resident

Department of Anesthesiology
Beth Israel Medical Center
Mount Sinai School of Medicine
New York, New York 10003

REFERENCE

1. Benumof JL: One lung ventilation: Which lung should be PEEPED. *ANESTHESIOLOGY* 56:161, 1982

(Accepted for publication July 28, 1983.)

A Device for Applying CPAP to the Nonventilated Upper Lung during One-lung Ventilation. II

To the Editor:—Unilateral pulmonary ventilation through an endobronchial tube frequently produces significant hypoxemia. There has been great interest in methods for maximizing arterial oxygenation when 100% oxygen and adjustments to ventilatory pattern do not suffice. Among these maneuvers are unilateral pulmonary artery occlusion¹ and application of PEEP to the dependent lung.² Capan *et al.*³ recently demonstrated that simple insufflation of oxygen to the nondependent lung was ineffective in improving arterial oxygenation during one-lung ventilation, but that oxygen insufflation with 10

cmH₂O CPAP applied to the nondependent lung resulted in marked improvement in PaO₂. This maneuver alone appeared to be more effective than other combinations of dependent lung PEEP and insufflation in improving oxygenation and did not reduce cardiac output.

We have constructed a device for application of non-dependent lung CPAP from equipment readily available in our anesthesia workroom. It is a convenient method of applying the technique suggested by Capan.³ Our device is designed for use with the Bronchocath endobronchial tubes (National Catheter Co., Argyle, New York)

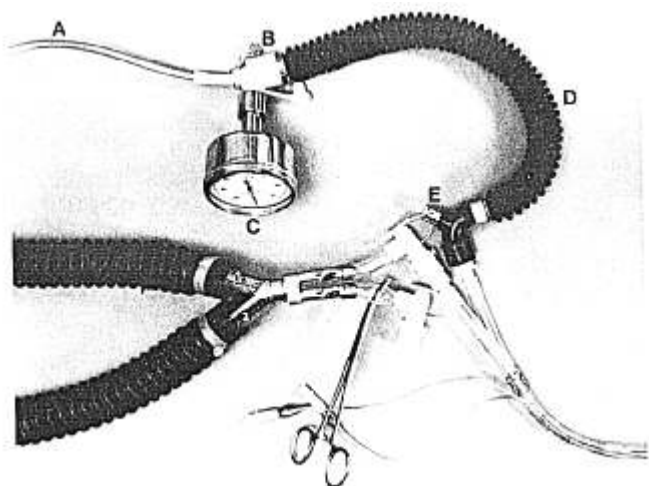


FIG. 1. The endobronchial CPAP device consisting of (A) oxygen connecting tube (#H8294-003119, Bard-Parker, Rutherford, New Jersey); (B) swivel adapter (#625109, Portex, Inc., Wilmington, Massachusetts); (C) inspiratory force meter (#60-60) with connector (#00-275-1, Clarence A. Smith, Inc., Arlington, Massachusetts); (D) Flexible corrugated adapter (#1100554, North American Drager Co.); and (E) elbow pop-off valve (Clarence A. Smith, Inc., Arlington, Massachusetts).

but could be modified easily for use with other endobronchial tubes.

It is pictured in figure 1 and consists of a length of oxygen tubing (A) from a flowmeter fitted to the rubber septum of a Portex swivel adapter (B). The 15-mm O.D. sidearm of (B) holds an aneroid manometer (C) measuring airway pressure. The 15-mm I.D. end of (B) is attached to a rubber flexible adapter tube (D). The distal (patient)

end of this tubing is fitted with an elbow connector with integral pop-off valve (E). This fits on the standard endotracheal tube connector of either Bronchocath lumen when the corresponding right-angle connector with suction port is clamped and disconnected during one-lung ventilation. In use, the oxygen flow rate and/or pop-off valve is adjusted to provide the desired amount of CPAP as measured on the manometer. We also have used the valve assembly and mask adapter for the Magill breathing system in place of the elbow connector (E) with success.

We have found that the ready availability of this device and its ease of operation simplify the management of hypoxemia during one-lung anesthesia.

ALEXANDER A. HANNENBERG, M.D.
PAUL R. SATWICZ, M.D.
ROBERT S. DIENES, JR., M.D.
JANE C. O'BRIEN, C.R.N.A.

*Department of Anaesthesia and Respiratory Therapy
Beth Israel Hospital
Boston, Massachusetts 02115*

REFERENCES

1. Nilsson E, Slater EM, Greenberg J: The cost of the quiet lung: Fluctuations in Pa_{O_2} when the Carlens tube is used in pulmonary surgery. *Acta Anaesthesiol Scand* 9:49-55, 1965
2. Katz JA, Laverne RG, Fairley HB, Thomas AN: Pulmonary oxygen exchange during endobronchial anesthesia: effect of tidal volume and PEEP. *ANESTHESIOLOGY* 56:164-171, 1982
3. Capan LM, Turndorf H, Patel C, Ramanathan S, Acinapura A, Chalon J: Optimization of arterial oxygenation during one-lung anesthesia. *Anesth Analg* 59:847-851, 1980

(Accepted for publication July 28, 1983.)

Propranolol prior to ECT Associated with Asystole

To the Editor:—A recent Clinical Report by Hood and Mecca¹ recommends the use of intravenous propranolol to attenuate the hypertensive response to ECT. We would like to report a case illustrating the occurrence of asystole associated with the use of iv propranolol in combination with ECT.

REPORT OF A CASE

A 68-year-old woman with her sixth episode of severe depression was scheduled for ECT. Electroconvulsive therapy was recommended because the current episode did not improve with an outpatient trial of pharmacotherapy. The patient's medical history included a myocardial infarction 5 yrs prior to admission and insulin-dependent diabetes mellitus. Admission laboratory tests were all within normal limits except for a fasting blood sugar of 337 mg/dl and the ECG, which showed an old anteroseptal myocardial infarction. Physical ex-

amination was unremarkable. The morning of the first scheduled treatment, the patient exhibited anxiety prior to treatment, with a pulse rate of 100/min and blood pressure of 180/120 mmHg. Before induction of anesthesia, propranolol, 1 mg iv, was administered, and the standard administration of atropine 0.4 mg iv was omitted. Thiopental 1.9 mg/kg, and succinylcholine, 0.5 mg/kg, were used to induce general anesthesia and muscle relaxation. Oxygen (100%) was administered via mask by positive pressure from the onset of induction. The treatment was monitored continuously by single-channel ECG and EEG. A bidirectional brief pulse electrical stimulus was delivered bilaterally without eliciting a seizure. The stimulation, however, was followed by progressive slowing of sinus rhythm for a period of 5 s, ultimately resulting in asystole. Cardiopulmonary resuscitation was instituted, following which regular sinus rhythm resumed after a total of 15 s of asystole. The patient recovered uneventfully from the anesthesia. Cardiac evaluation at follow-up reported no sequelae from the event. ECT treatment was interrupted in favor of further pharmacotherapy and psychotherapy. After 4 months of treatment without