

$$t = \frac{\sqrt{\text{PTC}} - \hat{\beta}_0}{\hat{\alpha}_0}$$

where $\hat{\alpha}_0$ and $\hat{\beta}_0$ denote the estimates of the common regression coefficients α_0 and β_0 . These estimates (SE) were found to be $\hat{\alpha}_0 = 0.0623$ (0.0023) and $\hat{\beta}_0 = 3.302$ (0.043).

The uncertainty of the prediction is mainly a result of the variation of the individual regression coefficients α and β around α_0 and β_0 ; the variation around the individual regression lines and the uncertainty in estimates $\hat{\alpha}_0$ and $\hat{\beta}_0$ are negligible in this connection. Figure 2 summarizes the results. There was no difference between groups 1 and 2 regarding the relationship between the first reaction to TOF stimulation and PTC. Also the initial dose of pancuronium had no influence.

In 43 patients stimulated on both arms, mean time (SE) to first reaction to TOF nerve stimulation was 53.6 min (19.0) for the arm stimulated with TOF stimulation and 53.0 min (18.3) for the arm stimulated with intermittent tetanic stimulations every 6 to 10 min. This difference is not statistically significant.

DISCUSSION

There is a close inverse correlation between number of posttetanic twitches derived from a recording (the posttetanic count: PTC) and time to first response to TOF nerve stimulation.¹ The numbers of posttetanic responses detected by a transducer are, however, not necessarily the same as the number of responses that can be felt manually. We found that it is possible to predict time to reappearance of first response to TOF nerve stimulation with reasonable accuracy simply by feeling the response at the thumb and counting the number of posttetanic responses.

Anesthesiology
60:374-377, 1984

Detection of Paradoxical Air Embolism by Transesophageal Echocardiography

HITOSHI FURUYA, M.D.,* AND FUKUICHIRO OKUMURA, M.D.†

Venous air embolism is a potentially serious complication that most commonly occurs during neurosurgery

* Staff Anesthesiologist.

† Chief of Anesthesiology.

Received from the Department of Anesthesiology, National Cardiovascular Center, 5-125, Fujishirodai, Suita, Osaka, 565, Japan. Accepted for publication September 5, 1983.

Address reprint requests to Dr. Okumura.

Key words: Embolism: air. Monitoring: transesophageal echocardiography.

In this study, pancuronium was used and consequently our results only apply to this drug. Although it is likely that the same principle would apply to other nondepolarizing neuromuscular blocking drugs, the time estimates will probably differ among the various drugs. For instance, the time estimates for the newer intermediate-acting neuromuscular blockers, atracurium and vecuronium, should be shorter than for pancuronium.

Tetanic stimulation may in itself influence recovery from a nondepolarizing neuromuscular blockade.^{4,5} However, our results indicate that there is no clinically significant differences in time to first response to TOF nerve stimulation, whether the nerve is stimulated with TOF or with intermittent tetanic stimulations (50 Hz for 5 s) every 6 to 10 min.


In summary, our results indicate that: 1) the time to return of response to TOF nerve stimulation may be derived from the number of posttetanic twitch responses felt at the thumb (tactile PTC); and 2) intermittent tetanic stimulation (50 Hz for 5 s) every 6 to 10 min during intense nondepolarizing neuromuscular blockade does not influence time to first response to TOF nerve stimulation.

REFERENCES

1. Viby-Mogensen J, Howard-Hansen P, Chræmmer-Jørgensen B, Ørding H, Engbæk J, Nielsen A: Posttetanic count (PTC): A method of evaluating an intense nondepolarizing neuromuscular blockade. *ANESTHESIOLOGY* 55:458-461, 1981
2. Viby-Mogensen J, Hansen PH, Jørgensen BC, Ørding H, Kann T, Fries B: A new nerve stimulator (Myotest). *Br J Anaesth* 52:547-550, 1980
3. Ali HH, Utting JE, Gray C: Stimulus frequency in the determination of neuromuscular block in humans. *Br J Anaesth* 42:967-977, 1970
4. Feldman SA, Tyrell MF: A new theory of the termination of action of the muscle relaxants. *Proc R Soc Med* 63:692-695, 1970
5. Ali HH, Savarese JJ: Monitoring of neuromuscular function. *ANESTHESIOLOGY* 45:216-249, 1976

with the patient in the sitting position. Paradoxical air embolism is rare, but may represent a serious complication. Although signs and symptoms of paradoxical air embolism have been described during neurosurgical procedures in the sitting position,^{1,2} a definitive diagnosis has not been established. We previously described the use of transesophageal echocardiography for detecting venous air embolism and have suggested arterial air embolism can also be detected by this method.³ We describe a case of paradoxical air in the left atrium and aorta that was

FIG. 1. Normal transesophageal echocardiogram. PAW = posterior aortic wall; AO = aortic root; AAW = anterior aortic wall; and RVOT = right ventricular outflow tract.



detected by transesophageal echocardiography during neurosurgery in the sitting position.

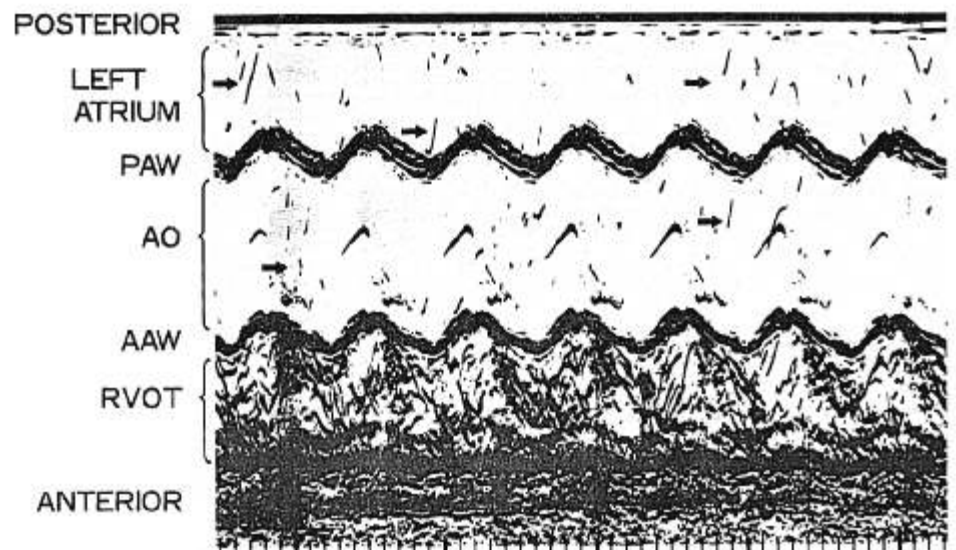
REPORT OF A CASE

A 39-year-old woman, who had suffered from bacterial endocarditis 27 years ago, was admitted for removal of a pinealoma. Mitral insufficiency was detected by cardiac catheterization and echocardiography, but no intracardiac shunt was observed. She tolerated daily activities well, and no additional cardiovascular findings were found by pre-operative examination. She had a right side ventriculo-peritoneal shunt inserted one month prior to removal of the tumor. Removal of the pinealoma was to be performed in the sitting position. After induction of anesthesia, a 7-F, double-lumen Berman angiographic catheter was inserted through the right femoral vein, and the catheter tip positioned in the pulmonary artery. During surgery, left radial artery pressure, pulmonary artery pressure, superior vena cava pressure, fraction of end-tidal carbon dioxide, and transesophageal echocardiogram were monitored continuously. The procedure for insertion of the trans-

esophageal echocardiographic transducer has been described previously,³ and the transducer was fixed at the level of the aortic valve (fig. 1).

Transesophageal echocardiography detected a small volume of air during craniotomy. It then showed massive air in the right ventricular outflow tract with lesser amounts in the left atrium and the aorta (fig. 2). This was followed by increased pulmonary artery and superior vena cava pressures, and decreased end-tidal carbon dioxide concentrations and systemic arterial blood pressure (fig. 3). Pressure on the neck, 10 cm of positive end-expiratory pressure, and 100% of oxygen were applied. About 30 ml of air were aspirated from the pulmonary artery catheter. The contrast echocardiogram of the left atrium and the aorta vanished within a few minutes, and then that of the right ventricular outflow tract disappeared. The pulmonary artery pressure then returned to normal. Another air embolism episode occurred later. Although a clear contrast echocardiogram was seen in the right ventricular outflow tract, no significant change in the hemodynamic variables or end-tidal carbon dioxide concentrations were found because of prompt treatment. The operation was performed uneventfully. Diabetes insipidus was complicated postoperatively, but no significant

FIG. 2. Contrast echocardiogram during air embolism. Contrast echocardiogram is in the right ventricular outflow tract, and slight degree of contrast echocardiogram is in the left atrium (*upper arrows*) and aortic root (*lower arrows*). Abbreviations are the same as in figure 1.



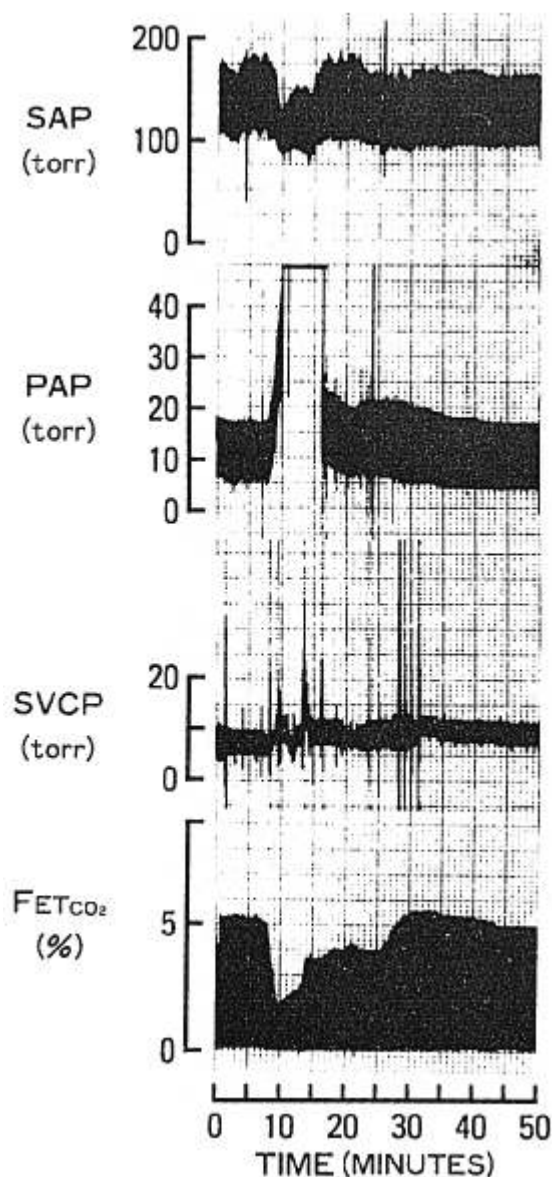


FIG. 3. Record of SAP (systemic arterial pressure), PAP (pulmonary artery pressure), SVCP (superior vena cava pressure), and F_{ETCO_2} (fraction of end-tidal carbon dioxide). Time means the duration from the start of the operation.

neurologic signs and symptoms secondary to cerebral air embolism were recognized.

DISCUSSION

Paradoxical air embolism is a rare complication that occurs in a patient undergoing neurosurgical procedures in the sitting position. If it occurs in a patient who has an intracardiac shunt, the result may be lethal. Although a probe foramen ovale is present in at least 20–35% of the adult population,⁴ paradoxical air embolism will not occur because the left atrial pressure is usually higher than that of the right atrium. Perkins-Pearson *et al.*⁵ re-

ported that paradoxical air embolism will occur when the right atrial pressure is 5 mmHg greater than the pulmonary capillary wedge pressure from venous air embolism. In our case, the superior vena cava pressure was substituted for right atrial pressure. When venous air embolism occurred, the mean pulmonary artery pressure increased from 14 to 38 mmHg, and the superior vena cava pressure increased from 6.4 to 9.4 mmHg. Therefore, perhaps the air in the right atrium entered the left atrium through the probe patent foramen ovale due to the increased right atrial pressure, although apparent intracardiac shunt was unlikely, as evidenced by the cardiac catheterization and echocardiography data. The volume of air that was aspirated from the pulmonary artery was approximately 30 ml, but larger volumes of air might exist in the right atrium as evidenced by a decreased systemic arterial pressure. If there was an intracardiac shunt, a much larger volume of air might enter the left atrium and serious systemic or neurologic complications might have resulted. Therefore, the presence of an intracardiac shunt is not necessary to explain paradoxical air embolism described in our case. Butler and Hills⁶ reported that air bubbles could escape into the arterial system when gas was infused into the venous system either as microbubbles or as a bolus even without the existence of intracardiac shunt. This is a possibility in our case. They also demonstrated that larger bubbles, such as these 130 μ m in diameter, could escape entrapment when the lungs were pretreated with a pulmonary vasodilator (aminophylline).

Because of the clinical significance of the arterial air volume, it is very difficult to decide what volume might be clinically important. When 0.5 to 1.0 ml of air/kg body weight was injected into the left ventricular cavity of the canine heart, 40% of the animals died immediately of myocardial infarction, and an additional 40% died in the following 24 hours.⁷ When 1.0 to 1.25 ml of air/kg body weight was injected into the internal carotid artery of the dogs, a 50% mortality rate resulted.⁸ One-half milliliter of air injected directly into the left coronary artery was associated with myocardial injury.⁹ Thus, the consequences of air in the arterial system depend not only on the volume shunted but also on the site of the destination of it. We could not determine how much volume of air was shunted to the arterial system as detected by transesophageal echocardiography.

In conclusion, transesophageal echocardiography may be very useful for detecting both venous and arterial air embolism during neurosurgery in a sitting position.

REFERENCES

1. Gronert GA, Messick JM, Cucchiara RF, Michenfelder JD: Paradoxical air embolism from a patent foramen ovale. *ANESTHESIOLOGY* 50:548–549, 1979
2. Marquez J, Sladan A, Gendell H, Boehnke M, Mendelow H: Par-

- adoxical cerebral air embolism without an intracardiac septal defect. *J Neurosurg* 55:997-1000, 1981
3. Furuya H, Suzuki T, Okumura F, Kishi Y, Uefuji T: Detection of air embolism by transesophageal echocardiography. *ANESTHESIOLOGY* 58:124-129, 1983
 4. Edward JE: Inter-atrial communication. Pathology of the heart. Edited by Gould SE. Springfield, Charles C Thomas, 1960, pp 260-261
 5. Perkins-Pearson NAK, Marshal WK, Bedford RF: Atrial pressure in the seated position. Implication for paradoxical air embolism. *ANESTHESIOLOGY* 57:493-497, 1982
 6. Butler BD, Hills BA: The lung as a filter for microbubbles. *J Appl Physiol* 47:537-543, 1979
 7. Spencer FC, Rossi NP, Yu SC: The significance of air embolism during cardiopulmonary bypass. *J Thorac Cardiovasc Surg* 49:615-634, 1965
 8. Fries CC, Levowitz B, Adler S, Cook AW, Karlson KE, Dennis C: Experimental cerebral gas embolism. *Ann Surg* 145:461-470, 1957
 9. Goldfarb D, Bahnson HT: Early and late effects on the heart of small amounts of air in the coronary circulation. *J Thorac Cardiovasc Surg* 46:368-378, 1963

Anesthesiology
60:377-380, 1984

Hypotensive Anesthesia for a Patient with Friedreich's Ataxia and Cardiomyopathy

T. M. BIRD, M.A., M.B.B.Chir., F.F.A.R.C.S.,* AND L. STRUNIN, M.D., F.F.A.R.C.S., F.R.C.P.(C.)†

Friedreich's ataxia is an autosomal recessive, inherited condition resulting in progressive limb and truncal ataxia. Cardiomyopathy is present in 90% of cases and kyphoscoliosis, causing steady deterioration of pulmonary function, in up to 80% of the cases.¹ Insertion of Harrington rods and spinal fusion may slow the progress of the pulmonary dysfunction,² but perioperative cardiopulmonary failure is a risk.³ Surgery is associated with marked blood loss^{4,5} which may be reduced by hypotensive anesthesia.^{6,7} We report a case of Friedreich's ataxia with cardiomyopathy who underwent hypotensive anesthesia for insertion of Harrington rods and spinal fusion. Sodium nitroprusside infusion resulted in a marked decrease in cardiac output associated with supraventricular tachycardia. Administration of isoflurane produced satisfactory hypotension with considerable reduction of intraoperative bleeding.

REPORT OF A CASE

A 20-year-old woman was diagnosed as having Friedreich's ataxia at the age of 6 years. At the same age, a systolic ejection murmur and abnormal electrocardiogram (ECG) were interpreted as evidence of a probable fibrotic cardiomyopathy. She had noted increasing dyspnea while climbing stairs before being permanently confined to a wheelchair at 14 years of age because of muscular weakness and incoordination. She was taking 0.125 mg digoxin bid to prevent arrhythmias and congestive cardiac failure. During the five years preceding this ad-

mission, a progressive thoracolumbar kyphoscoliosis had developed, and she was to undergo a Harrington rods insertion and spinal fusion to prevent further spinal curvature and compromise of her cardiopulmonary status.

Preoperative examination showed a normally developed girl of high intelligence, with the typical findings of Friedreich's ataxia⁴ and marked kyphoscoliosis, convex to the right. Cardiovascular examination showed an arterial blood pressure 100/60 mmHg with a regular heart rate of 100 bpm. There were no signs of left or right heart failure, although she did have marked gravitational edema of her ankles. A grade 2/6 systolic ejection murmur was heard over the precordium, but other heart sounds were normal. ECG showed sinus rhythm, a QRS axis of +100°, right ventricular dominance, and QRS and T patterns consistent with left ventricular strain or digoxin therapy. Echocardiography showed normal cardiac dimensions with good left ventricular function. Chest roentgenogram demonstrated clear lung fields with minimal cardiac enlargement and confirmed the gross thoracolumbar kyphoscoliosis centered around T₁⁰. Pulmonary function tests suggested a mixture of restrictive and reversible obstructive lung disease. With an F_IO₂ of 0.2, p_Ha was 7.43, Pa_{CO}2 29 mmHg, Pa_O2 91 mmHg, bicarbonate 19 mEq · l⁻¹, and base excess -3 mEq · l⁻¹, implying chronic hyperventilation. No nerve conduction studies were available.

Morphine, 10 mg, and hyoscine, 0.3 mg, were given im before anesthesia. Under local anesthesia, a 7-FG flow directed (R) catheter was inserted via the right internal jugular vein and the left radial artery was cannulated. A 14-gauge cannula was placed in a peripheral vein and all iv solutions were warmed. Hemodynamic variables were monitored using the computerized Haemodynamic Tracking System (Global Office Automation Systems, Calgary) and included cardiac index (CI), stroke volume (SVI), left ventricular stroke work (LVSWI), and systemic and pulmonary vascular resistance (SVRI, PVRI) (table 1).

Anesthesia was induced with iv droperidol, 5.0 mg, fentanyl 1,500 µg, and thiopental, 50 mg. After administration of pancuronium, 8.0 mg iv, the trachea was intubated and ventilation controlled breathing 65% nitrous oxide and oxygen. Other than a slightly elevated pulmonary capillary wedge pressure (PCWP), all hemodynamic variables were normal (table 1). The patient was then turned to the prone position, placed on a warming blanket, and all monitoring equipment repositioned and recalibrated. An infusion of sodium nitroprusside (50 mg in 500 ml 5% dextrose in water) was started at 1.0

* Lecturer.

† Professor.

Received from the Department of Anaesthesia, Foothill's Hospital, the University of Calgary, 1403 29th St. N.W., Calgary, Alberta T2N 2T9, Canada. Accepted for publication September 5, 1983.

Address reprint requests to Dr. Bird.

Key words: Genetics; Friedreich's Ataxia. Anesthetic Techniques; hypotension, induced.