

Anesthesiology  
60:487-488, 1984

## Pharyngeal and Esophageal Perforation Following Endotracheal Intubation

JAMES E. O'NEILL, M.D.,\* JOSEPH P. GIFFIN, M.D.,† JAMES E. COTTRELL, M.D.‡

Perforation of the pharynx or the esophagus is a rare complication of endotracheal intubation that may result in subcutaneous emphysema and mediastinitis.<sup>1-4</sup> The nature of such complications depends upon the location and depth of the perforation and the time interval between its occurrence, diagnosis, and treatment.<sup>2</sup> Previous reports<sup>1,2</sup> cite pharyngeal and esophageal tears that resulted when inexperienced individuals attempted emergency, usually resuscitative, intubations of the trachea. We report an esophageal and a pharyngeal perforation following endotracheal intubation that occurred during induction of anesthesia.

### REPORT OF TWO CASES

**Patient 1.** A 35-year-old woman was scheduled for a total abdominal hysterectomy. Her medical history was insignificant and laboratory data, chest roentgenogram, and electrocardiogram were within normal limits. Anesthesia was induced with thiopental 4 mg/kg iv, and muscle relaxation was obtained with succinylcholine 1 mg/kg iv. Additional incremental doses of succinylcholine were administered, since three attempts were necessary before intubation of the trachea was achieved. The initial laryngoscopy caused trauma to the pharyngeal mucosa and bleeding, making subsequent efforts at visualizing the vocal cords difficult. On the third attempt, a 7.5-mm cuffed endotracheal tube was inserted with the aid of a rigid stylet and a MacIntosh #3 laryngoscope blade. Anesthesia was maintained with 60% nitrous oxide and halothane, and pancuronium iv (total dose 16 mg) was administered, as needed, for muscle relaxation. The trachea was extubated in the operating room with the patient awake. On the first postoperative day, she developed a fever of 38.9° C and complained of a sore throat and dysphagia. Physical examination revealed diminished breath sounds over both lung bases. A chest roentgenogram disclosed a left lower lobe pneumonia and marked widening of the superior mediastinum with small radiolucent areas resembling air bubbles. Gram's stain of the patient's sputum revealed numerous diplococci, and her white blood count was 13,000 cells·mm<sup>-3</sup>. Despite treatment with iv ampicillin and clindamycin, her condition remained unchanged. An esophagogram revealed a posterior esophageal tear at the level of the cricopharyngeus muscle, and barium extravasation could be seen along the paraesophageal and paraaortic areas extending to the aortic arch (fig. 1). The patient returned to the operating room for an emergency

esophageal repair and drainage of a mediastinal abscess. After induction of anesthesia with thiopental 4 mg/kg iv, succinylcholine 1 ml/kg iv facilitated insertion of a 7.5-mm cuffed endotracheal tube. An uneventful course of anesthesia was maintained with 60% nitrous oxide, iv fentanyl (total of 0.35 mg) as needed, and a continuous infusion of 0.01% succinylcholine to maintain paralysis. Her postoperative course was uneventful and she was discharged 6 days later.

**Patient 2.** A 60-year-old female was admitted with a diagnosis of carcinoma of the cervix. Routine laboratory data and the electrocardiogram were within normal limits. A right upper lobe lung mass was seen on chest roentgenogram. An exploratory thoracotomy was planned. Preoperative medication administered in the operating room consisted of iv diazepam 5 mg and glycopyrrolate 0.2 mg. After anesthesia was induced with thiopental 3 mg/kg, succinylcholine 1 mg/kg was given iv for muscle relaxation. After an individual with limited experience in endotracheal intubation had made three unsuccessful efforts and done some blind probing with an endotracheal tube with a stylet inside it and a MacIntosh #3 laryngoscope blade, the patient's face became swollen and crepitant to touch. An experienced anesthesiologist replaced the trainee and visualized the vocal cords and inserted a 60-mm cuffed endotracheal tube. After intubation of the trachea, direct laryngoscopy was repeated and a small laceration of the right posterior pharynx was identified. Esophagoscopy revealed no esophageal tears. Anesthesia was maintained with iv fentanyl (total dose 0.3 mg) for the esophagoscopy, after which surgery was postponed. Controlled ventilation was continued in the recovery room. The neck crepitations gradually subsided by the first postoperative day, and the trachea was extubated.

On the fifth postoperative day, an esophagogram revealed leakage of barium from the pharyngeal tear with tracking into the soft tissue of the neck and superior mediastinum. The patient was returned to the operating room for incision and drainage of the mediastinal abscess and repair of the pharyngeal tear. The trachea was intubated on the first attempt by the same anesthesiologist. Her postoperative course was uneventful.

### DISCUSSION

Esophageal or pharyngeal tears resulting from the use of a laryngoscope, an endotracheal tube, or a stylet have not been reported previously as a complication during induction of anesthesia. In their series of eight patients who sustained complications of endotracheal intubation, Hawkins *et al.*<sup>1</sup> found that the most important risk factor in the development of pharyngeal or esophageal perforations was the relative inexperience of the individual performing the intubation, especially in an emergency setting.

Our cases reveal that esophageal and pharyngeal perforation can occur in the operating room. The exact technical defect that resulted in perforation in both our patients is unknown. A rigid stylet was used in both patients, but whether the stylet was inserted beyond the lumen of

\* Assistant Instructor.

† Assistant Professor.

‡ Professor and Chairman.

Received from the Department of Anesthesiology, SUNY/Downstate School of Medicine, Brooklyn, New York. Accepted for publication, September 26, 1983.

Address reprint requests to Dr. Giffin: Department of Anesthesiology, 450 Clarkson Avenue, Box 6, Brooklyn, New York 11203.

Key words: Intubation, endotracheal: complications. Complications: pharyngeal perforation, esophageal perforation.

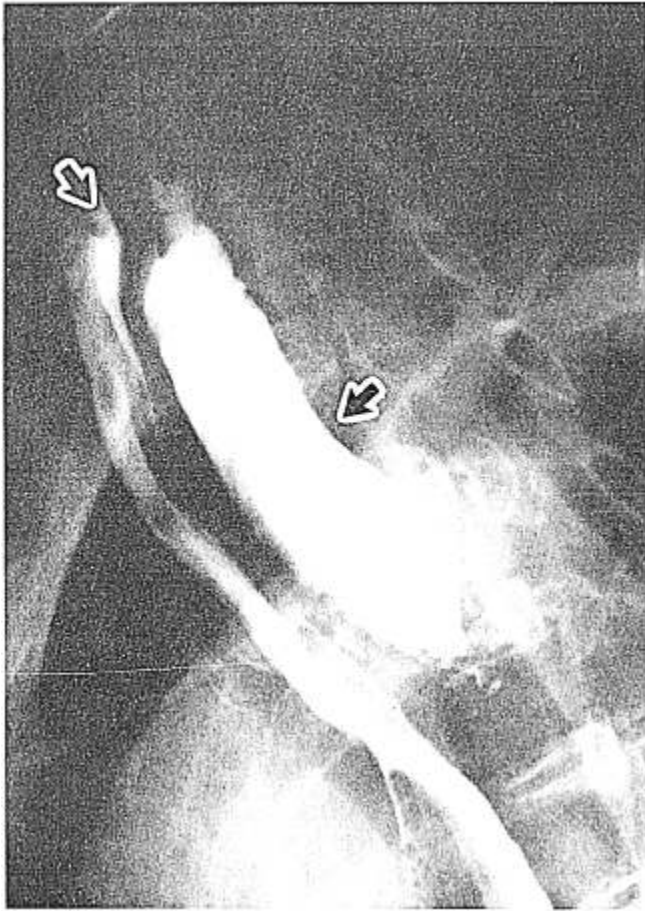


FIG. 1. Esophagogram revealing collection of barium in the soft tissues bordering the hypopharynx and superior esophagus. The barium extravasated through a tear in the wall of the posterior hypopharynx.

the tube, and therefore culpable is not certain. However, we believe that a rigid styleted endotracheal tube in the hands of an inexperienced individual may cause trauma and perhaps perforation, especially if excessive force is used. Inexperience with endotracheal intubation seems to be the principal cause of perforation in our cases. Experienced personnel successfully intubated the trachea during the first attempt.

In the first case the perforation occurred in the posterior esophagus at the distal end of the cricopharyngeus muscle, which is particularly susceptible to trauma. Once a tear is made, extension may occur if the endotracheal tube cuff is inflated against the torn mucosa.

Between the esophagus and the spinal aponeurosis lies a space that extends from the pharynx, past the mediastinum, to the diaphragm.<sup>2</sup> The pressure inside the space at the level of the mediastinum is subatmospheric; therefore, an opening along the course of this space, especially during positive pressure ventilation (PPV), could lead to

rapid filling with the contents of the esophagus and the pharynx.

Definitive diagnosis of an esophageal tear is dependent upon radiographic confirmation of interruption of the esophageal wall or direct visualization of the tear by endoscopy. Controversy exists over which technique is the more confirmatory.<sup>2</sup> In our first case, an anteroposterior chest roentgenogram was suggestive of a mediastinal process, while an esophagogram revealed a distinct tear with tracking of barium behind the esophagus and pooling of the material in the mediastinum.

Adequate treatment of mediastinitis resulting from esophageal perforation depends upon early diagnosis. Suspicion should be high in a patient with fever, dysphagia, and a history of a difficult endotracheal intubation. When the diagnosis is made, prompt surgical repair and drainage of the mediastinal tract or abscess is essential for an uneventful recovery.<sup>2</sup> If surgical treatment is delayed and mediastinitis develops, a 50% mortality rate may result.

Whereas esophageal tears may go unnoticed while the patient is unanesthetized, pharyngeal tears often are easily recognizable, since signs of subcutaneous emphysema develop in the face and neck. Postoperatively, the patient typically has the same complaints as does the patient with a torn esophagus. In addition, a patient with a perforation of the pyriform sinus may complain of numbness or anesthesia over the distribution of the internal branch of the superior laryngeal nerve. Adequate therapy for pharyngeal perforation is the same as that for esophageal perforation.

Esophageal perforation is a heretofore rarely reported complication of endotracheal intubation, especially during induction of anesthesia. It is a nonetheless serious and potentially fatal development that necessitates prompt diagnosis and treatment.

#### REFERENCES

1. Hawkins D, Seltzer D, Barnett T, Stoneman B: Endotracheal tube perforation of the hypopharynx. *West J Med* 120:282-286, 1974
2. Dubost C, Kaswin D, Duranteau A, Jehanno C, Kaswin R: Esophageal perforation during attempted endotracheal intubation. *J Thoracic Cardiovasc Surg* 78:44-55, 1979
3. Levine P: Hypopharyngeal perforation, an untoward complication of endotracheal intubation. *Arch Otolaryngol* 106:578-580, 1980
4. Wolff A, Kuhn F, Ogura F: Pharyngeal-esophageal perforations associated with rapid oral endotracheal intubation. *Ann Otolaryngol* 81:258-261, 1972
5. Stauffer J, Petty T: Accidental intubation of the Pyriform sinus, a complication of roadside resuscitation. *JAMA* 237:2324-2325, 1977
6. Leigh TF, Achord JL: Pharyngeal and esophageal perforation during instrumentation. *J Roentgenol* 91:757-765, 1964