

chest x-ray showed clearing of the pulmonary edema and the patient was weaned off IPPV uneventfully.

On reviewing the literature, I found three such cases had been reported previously. A 14-year-old, 74-kg boy developed laryngospasm and pulmonary edema following extubation after anesthesia for a simple mastectomy.² A 62-year-old man with carcinoma of the larynx developed laryngospasm and pulmonary edema following several unsuccessful attempts at intubation during induction of general anesthesia for endoscopy.³ A 33-year-old woman developed laryngospasm and pulmonary edema following unsuccessful attempts at intubation during induction of general anesthesia for tubal ligation.⁴

The mechanisms of the formation of pulmonary edema associated with upper airway obstruction are discussed in the above reports. The main factors are hypoxia and the large subatmospheric transpulmonary pressure gradients generated while trying to breathe against a closed glottis.

Anesthesiology
60:612-613, 1984

We should be aware that pulmonary edema may occur in adults, albeit rarely, following laryngospasm.

J. G. JENKINS, M.B., B.S., F.F.A.R.C.S.
Assistant Professor of Anesthesia
Department of Anesthesia
Stanford University Medical Center
Stanford, California 94305

REFERENCES

1. Lee KWT, Downes JJ: Pulmonary edema secondary to laryngospasm in children. *ANESTHESIOLOGY* 59:347-349, 1983
2. Cozanitis DA, Leijala M, Pesonen G, Zaki HA: Acute pulmonary edema due to laryngeal spasm. *Anaesthesia* 37:1198-1199, 1982
3. Oswald CE, Gates GA, Holmstrom FMG: Pulmonary edema as a complication of acute airway obstruction. *JAMA* 238:1833-1835, 1977
4. Jackson FN, Rowland V, Corssen G: Laryngospasm-induced pulmonary edema. *Chest* 78:819-821, 1980

(Accepted for publication December 15, 1983.)

Further Modifications of the Miller Blade for Difficult Pediatric Laryngoscopy

To the Editor:—Many innovative modifications of straight Miller blades (sizes 0-1) recently have been suggested to facilitate pediatric laryngoscopy and provide supplemental oxygen (O₂) during endoscopy and tracheal intubation. Such modifications have included widening the distal end of the blade,¹⁻³ reducing the width of the C-shape flange,³ placing a strip of rough adhesive tape

along the blade's lingual surface,⁴ increasing the angle between the blade and handle,² and adapting blades for continuous gas insufflation by taping,⁵ threading,⁶ or soldering^{7,8} extra insufflation channels alongside. Many of these individual modifications have proven quite beneficial clinically and have prompted commercial development of such new laryngoscope lines as the Foregger Oxyscopes

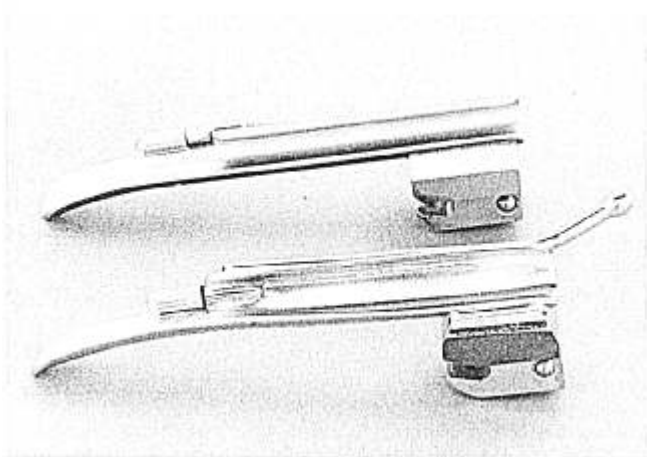


FIG. 1. Modified Miller-1 blade in foreground demonstrates an opened C-flange, side-arm insufflation port and channel, and corrugated lingual surface. A standard Miller-1 blade is in the background for comparison.

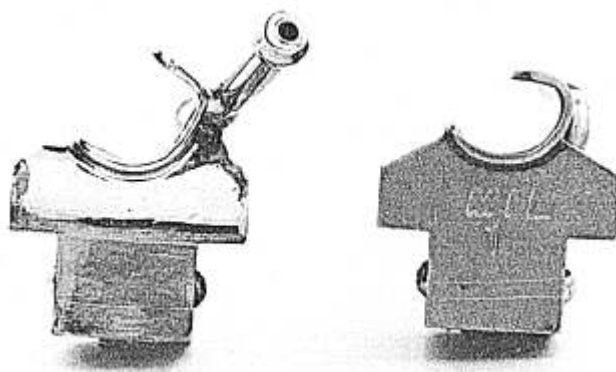


FIG. 2. Rear views of modified Miller-1 blade (left) and standard Miller-1 blade (right) demonstrate improved sighting capability and unobtrusive gas insufflation port on modified blade.

(Puritan-Bennett Corp., Foregger Medical Division, Langhorne, Pennsylvania).

We have combined several individual modifications in a single overall modification of a Miller-1 blade to facilitate difficult pediatric laryngoscopy and provide O₂ supplementation without risk of dislodgement of such loosely secured options as feeding tubes for O₂ insufflation or adhesive strips. A Miller-1 blade was fitted along its left side with a chrome-plated brass gas insufflation channel, corrugated along its lingual surface and widened in cross-section by bending the C-shape flange outward (figs. 1, 2). These modifications resulted in a laryngoscope blade that provided continuous gas insufflation, presented an atraumatic, nonskid surface to a slippery tongue, opened the rear aperture for improved glottic sighting, and had no loose attachments. We now have used this modified blade in a variety of clinical circumstances ranging from congenital anomalies (cystic hygroma, epignathus) to airway infections (croup, acute epiglottitis) and have found that it facilitates difficult endoscopy and provides unobtrusive oxygen or anesthetic insufflation when desired. Further adaptation of this modified brass blade (fig. 1) to a stainless steel instrument with a halogen lamp, cool fiberoptic illumination,* and appropriate battery-containing handle could result in a much improved pediatric laryngoscope with better illumination and little risk of thermal injuries.⁹ These further modifications are beyond our budget and engineering expertise.

* Currently available on MacIntosh and Miller Halogen Fiberoptic Laryngoscopes, Welch Allyn, Inc., Skaneateles Falls, New York.

The Einstein Carbon Dioxide Detector

To the Editor:—Despite the most diligent efforts by anesthesiologists to confirm proper placement of the endotracheal tube, undiagnosed intubation of the esophagus still occurs, potentially with devastating consequences. The routine practice of auscultating both lung fields and listening over the stomach is mandatory. Auscultation over the stomach reveals characteristic sounds if the tube is in the esophagus. However, transmission of sounds to the lungs created by “ventilation” through an esophageal intubation may result in a false feeling of security. Furthermore, there are certain circumstances, particularly in obstetric anesthesia, where the abdomen is prepared

prior to induction, that preclude abdominal auscultation. Maternal mortality reports from the United States¹ and United Kingdom* are potent reminders that failed intubation is an ongoing problem, with resultant mortality.

Murray and Modell² recently discussed various endotracheal tube accidents including esophageal intubation. They have established the value of carbon dioxide (CO₂) monitoring for confirming correct tube placement

* Crawford S: Failed Intubation (Editorial). *Obstetric Anesthesia Digest* 1:61-63, 1981.

JAMES H. DIAZ, M.D.
*Attending Anesthesiologist
and Co-Director Intensive Care Unit
Ochsner Clinic and
Alton Ochsner Medical Foundation
New Orleans, Louisiana 70121*

The author acknowledges and appreciates the design and engineering services provided by Mr. J. R. Crocker III (A-C Medical Supply, Inc., Metairie, Louisiana) and the legal advice and patentability surveys provided by Mr. James E. Wright, Jr. (New Orleans, Louisiana), and Mr. David E. Varner (Cushman, Darby, and Cushman, Washington, D. C.).

REFERENCES

1. Buekes HvZ, Mostert JW: A new anatomic laryngoscope. *ANESTHESIOLOGY* 57:552-553, 1982
2. Matsuki A: New pediatric laryngoscope. *ANESTHESIOLOGY* 57:556, 1982
3. Rokowski WJ, Gurmarnik S: Laryngoscope blades modified for neonates and infants. *Anesth Analg* 162:241-242, 1983
4. Moynihan P: Modification of pediatric laryngoscope. *ANESTHESIOLOGY* 156:330, 1982
5. Wung J, Stork R, Indyk L, Driscoll JM Jr: Oxygen supplement during endotracheal intubation of the infant. *Pediatrics* 59:1046-1048, 1977
6. Cork RC, Woods W, Vaughan RW, Harris T: Oxygen supplementation during endotracheal intubation of infants. *ANESTHESIOLOGY* 51:186, 1979
7. Hencz P: Modified laryngoscope for endotracheal intubation of neonates. *ANESTHESIOLOGY* 53:84, 1980
8. Todres ID, Crone RK: Experience with a modified laryngoscope in sick infants. *Crit Care Med* 9:544-545, 1981
9. Toung TJK, Donham RT, Shipley R: Thermal burn caused by a laryngoscope. *ANESTHESIOLOGY* 55:184-185, 1981

(Accepted for publication December 16, 1983.)