


FIG. 1. Endotracheal tube with bronchoscope *in situ*. Note doughnut-shaped intussusception.



tube was removed with the bronchoscope in place. The patient was reintubated and the procedure continued uneventfully.

As is shown in the photograph, upon withdrawal of the bronchoscope, the tip of the unit had intussuscepted into the covering sleeve of the bronchoscope, folding back the sleeve to the point where it completely occluded the lumen of the endotracheal tube and jammed in place. An attempt to remove the fiberoptic unit was made after the endotracheal tube was out of the patient, but it could not be done without destroying the unit.

We would recommend that if any difficulty be encountered in removing a fiberoptic bronchoscope from an endotracheal tube, that the endotracheal tube be removed, preferably under direct vision, as rapidly as pos-

sible with the bronchoscope in place and without the delay attendant upon further attempts to withdraw the unit. This mechanical failure also should be a part of the differential diagnosis whenever ventilation is interfered with during bronchoscopy.

MITCHEL SIEGEL, M.D.
Director

PETER COLEPRATE, M.D.
Critical Care Fellow

*Department of Anesthesiology
Booth Memorial Medical Center
Flushing, New York 1135*

(Accepted for publication March 2, 1984.)

Anesthesiology
61:215-216, 1984

A Simple Solution for Determining Shunt Flow during Carotid Endarterectomy

To the Editor:—The question of shunting during carotid endarterectomy previously has been discussed in the literature. To our knowledge, no one has yet discussed the question of accurate assessment of carotid flow during shunting. Because the appearance of a shunt in place gives no indication of the amount of flow, our cardiovascular surgeon (August Tomusk) devised a simple solution to this question.

By simply cutting the Javid shunt in half and inserting

a 3-mm cannulating Statham® flow probe (fig. 1) and connecting this to a Statham® 2204 blood flow meter, you can easily achieve an on line accurate determination of carotid shunt flow, while maintaining excellent field working conditions.

The above equipment usually is used in institutions performing coronary artery bypass surgery, and, hence, no added expenditures are necessary.

During the first three cases, I had two instances of

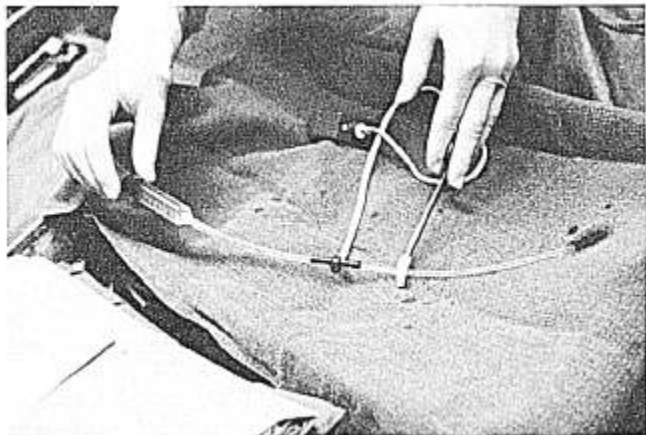


FIG. 1.

Anesthesiology
61:216-217, 1984

significant decreases in flow secondary to transient crimping of the Javid shunt. This crimping, while otherwise unobserved, was rapidly detected by the flows decreasing from the 200 ml/min range to 30-50 ml/min range.

In summary, we believe the above to be a reliable, clinically workable, inexpensive solution to shunt flow determination during carotid endarterectomy surgery.

ROBERT L. LINDSEY, M.D.
Associated Anesthesiologists
5800 Fairfield Blvd.
Suite 150, Worthman Mall
Fort Wayne, Indiana 46807

(Accepted for publication March 2, 1984.)

A Simplified Method of CPAP Delivery to the Nonventilated Lung during Unilateral Pulmonary Ventilation

To the Editor:—The proper management of anesthesia for thoracic surgical procedures employing a double-lumen endobronchial tube and unilateral pulmonary ventilation has been a subject of much debate. Multiple approaches have been proposed to improve oxygenation in this setting. In an editorial comment,¹ Benumof summarized the experience of multiple authors, recom-

mending a treatment sequence for severe hypoxemia during one-lung ventilation in the lateral position. If the application of 5-10 cmH₂O of positive end-expiratory pressure (PEEP) to the ventilated, dependent lung did not result in an improvement in oxygenation, he recommended the application of 5-10 cmH₂O of continuous positive airway pressure (CPAP) to the airway of the nonventilated, nondependent lung. The mechanics of CPAP application to the nonventilated lung have been left to the inventiveness of the individual anesthesiologist. Insufflation of oxygen via a catheter (*i.e.*, nasogastric tube) introduced into the endobronchial tube of the nonventilated lung has shown promise. However, utilizing this technique can lead to uncontrollable and unmeasurable levels of positive pressure applied to the lung. Numerous other reports²⁻⁴ have related effective means of applying CPAP to the nonventilated lung, but these have involved the use of individually constructed components not readily available to the practicing anesthesiologist. I have employed a system that is safe, sterile, and easily controlled utilizing equipment found in most anesthesia departments.

When unilateral ventilation becomes desirable, the ventilator and circle system are connected to the dependent limb of the endobronchial tube and ventilation continued. As illustrated, CPAP insufflation of oxygen to the nonventilated lung is accomplished by connecting the distal end of a Coaxial (CPRAM®) or Bain® breathing circuit to the superior limb of the endobronchial tube




FIG. 1. As described in the text, the CPRAM or BAIN circuit (here shown is an 18-inch CPRAM circuit) is connected directly to the limb of the endobronchial tube in contact with the nonventilated lung. The opposite end is fixed in an upright position and connected to the PEEP valve and an oxygen source. The ventilated lung remains connected to the primary circuit and anesthesia machine.