

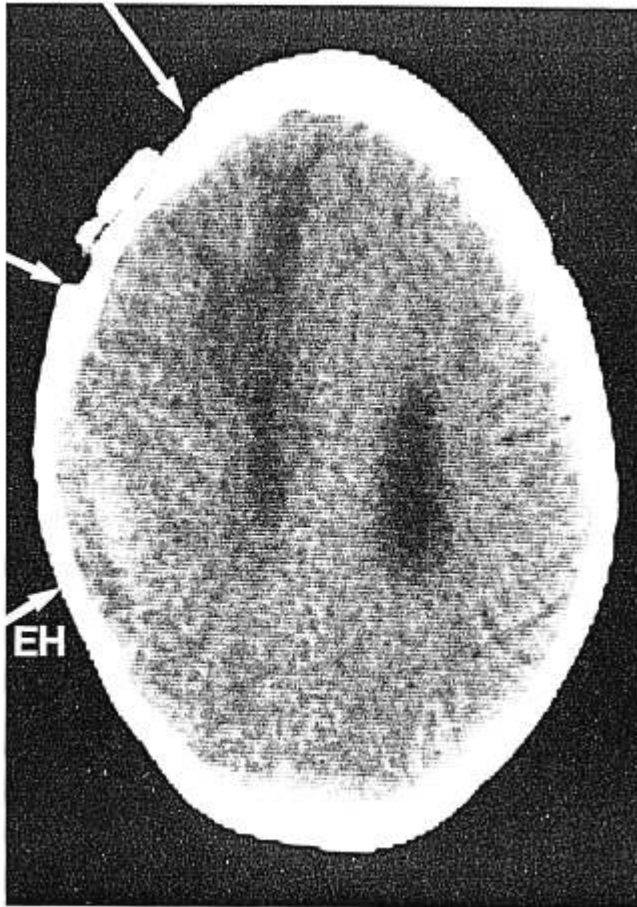FIG. 2. Computerized tomography scan, showing the epidural hematoma (EH) and the old craniotomy boundaries (at arrows).

are to be expected; 3) always use an abundant amount of sealing ointment around the pins; 4) never remove the headholder, unless there is no gradient left between head and heart level.

REFERENCES

1. Gardner WJ: Intracranial operations in the sitting position. *Ann Surg* 101:138-146, 1935
2. Albin MS, Babinski M, Maroon JC, Jannetta PJ: Anesthetic management of posterior fossa surgery in the sitting position. *Acta Anaesthesiol Scand* 20:117-128, 1976
3. Edelman JD, Wingard DW: Air embolism arising from burr holes. *ANESTHESIOLOGY* 53:167-168, 1980
4. Merrill DC, Samuels SI, Silverberg GD: Venous air embolism of uncertain etiology. *Anesth Analg* 61:65-66, 1982
5. Pang D: Air embolism associated with wounds from a pintype headholder. *J Neurosurg* 57:710-713, 1982
6. Cabezudo JM, Gilsanz F, Vaquero J, Areito E, Martinez R: Air embolism from wounds from a pintype headholder as a complication of posterior fossa surgery in the sitting position. *J Neurosurg* 55:147-148, 1981
7. Wilkins RH, Albin MS: An unusual entrance site of venous air embolism during operations in the sitting position. *Surg Neurol* 7:71-72, 1977
8. Martin JT: Positioning in anesthesia and surgery. New York, WB Saunders, 1978 pp 84-85

Anesthesiology
61:461-464, 1984

Short-term Sterility of the Pulmonary Artery Catheter Inserted Through an External Plastic Shield

WILLIAM E. JOHNSTON, M.D., DONALD S. PROUGH, M.D., ROGER L. ROYSTER, M.D.,
JAMES E. PEACOCK, M.D., GLENN P. GRAVLEE, M.D., STEPHEN A. MILLS, M.D.,
A. ROBERT CORDELL, M.D.

Flow-directed, pulmonary artery catheters frequently require repositioning after initial insertion to obtain wedge pressures with an appropriate volume of air for balloon inflation. Since Kopman and Sandza¹ and Gomez *et al.*² reported protecting the catheter within a plastic

shield, several manufacturers have provided catheter shields. However, no one has examined the ability of those shields to prevent contamination of the catheters. We therefore studied the incidence of bacterial colonization of the pulmonary artery catheter within one commercially available shield (Cath-Gard™ Catheter

Received from the Department of Anesthesia; the Section on Infectious Diseases, Department of Medicine; and the Section on Cardiothoracic Surgery, Department of Surgery, Bowman Gray School of Medicine of Wake Forest University, Winston-Salem, North Carolina. Accepted for publication February 27, 1984. Presented in part at the Sixth Annual Meeting of The Society of Cardiovascular Anesthesiologists, May 7-9, Boston, Massachusetts.

Address reprint requests to Dr. Johnston: Department of Anesthesia, Bowman Gray School of Medicine, 300 South Hawthorne Road, Winston-Salem, North Carolina 27103.

Key words: Equipment: Catheters, flow-directed, Swan-Ganz®. Sterilization.

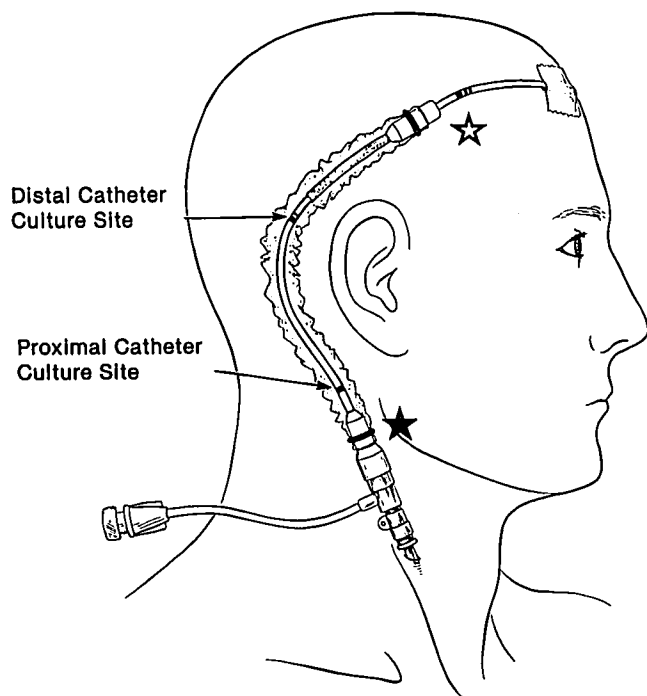


FIG. 1. The pulmonary artery catheter is inserted through a plastic shield that maintains a sterile segment of catheter for subsequent manipulations. ☆ and ☆ indicate measurement sites on the catheter to quantitate distal sheath migration and proximal catheter manipulation distances, respectively.

Contamination Shield, Arrow International, Inc., Reading, Pennsylvania).

MATERIALS AND METHODS

The study group comprised 21 male and 9 female patients scheduled for open-heart surgery (coronary artery surgery, $n = 27$; valvular replacement, $n = 3$). Their mean age was 56.8 ± 1.6 years. All patients received prophylactic antibiotic therapy with either vancomycin or a cephalosporin. In the operating room, a 7.5 Fr. quadruple-lumen pulmonary artery catheter (Edwards Laboratories, Inc., Santa Ana, California) was passed through the catheter shield and introducer sheath (Arrow Introducer Kit, Arrow International, Inc., Reading, Pennsylvania), which had been inserted percutaneously into the right internal jugular vein by Seldinger technique. The shield was secured to the catheter only by the flexible diaphragm at the distal end of the shield. The person inserting the catheter wore a sterile gown and gloves, the skin was prepared with povidone-iodine solution, and the area of insertion was draped with sterile skin towels. Following the insertion, povidone-iodine ointment and an external dressing were applied to the site of insertion. The shield enclosed approximately 22 cm of catheter.

We then recorded the length of the catheter inside the shield as measured at each end of the shield (fig. 1). We repositioned the catheter as necessary during cardiopulmonary bypass to avoid pulmonary artery damage and to maintain accurate pulmonary arterial and wedge tracings. All changes in catheter length were recorded after each manipulation. All of those changes occurred at the proximal end of the shield and were recorded as proximal catheter manipulations. We routinely measured the external catheter length once the patient was transferred to the intensive care unit (ICU) and again before catheter culture. If the free end of the shield moved spontaneously at any time before obtaining cultures, we measured the distance and termed those unaccountable changes as distal shield migrations. After the patients were stable hemodynamically and their tracheas extubated, we pulled the catheter back from the pulmonary artery to a central venous position. This permitted use of the catheter for drug administration or supplemental potassium chloride replacement. Immediately before that manipulation, we opened the shield near each end with sterile scissors and swabbed proximal and distal sites on the catheter for aerobic cultures (fig. 1). Specimens were incubated in trypticase-soy broth over a 3-day period. No further catheter manipulations were made after the shield was opened.

We observed the patients daily throughout their hospitalization for infectious complications. The Clinical Research Practices Committee approved this study. Based on their recommendation, consent was not obtained from the patient since this study in no way altered our routine management of their course.

Data were analyzed by chi-square analysis and analysis of variance with a significance level of $P \leq 0.05$. Where applicable, mean values with standard errors were used.

RESULTS

In the operating room, catheters were pulled back 4.9 ± 0.4 cm (range 1.5–9.0 cm) before starting cardiopulmonary bypass. Immediately before discontinuing bypass, the catheters were refloatated to a wedge position by advancing them 3.8 ± 0.5 cm (range 0–11 cm). The number of proximal catheter manipulations was 2.7 ± 0.1 in the operating room and 1.1 ± 0.1 in the intensive care unit (ICU). The range of distance changes during proximal catheter manipulations in the operating room was 1.5–10 cm out of and 0–11 cm into the patient. In the ICU, catheters were advanced 0–14 cm in and out of the patient to maintain adequate position.

Unaccountable distal shield migrations occurred in 25 of the 30 patients. Inward migration of the shield along the catheter occurred more frequently than outward migration both in the operating room ($P \leq 0.045$) and the ICU ($P \leq .007$). The range of shield migration

in the operating room and ICU, respectively, were 0–10 cm and 0–8 cm inward and 0–10 cm and 0–5 cm outward. At no time did nonsterile catheter (that lying outside the shield) enter the jugular vein.

The time from catheter insertion to culture of the catheter within the shield was 1.7 ± 0.2 days, with a range of 0.8 to 6.9 days. By visual inspection, all shields were intact before being opened with scissors.

Cultures of catheters inside the shields yielded *Staphylococcus epidermidis* at the proximal location in one patient and at the distal location in one patient (6.7% of catheters, 3.3% of cultured sites). The number of catheter manipulations and shield migrations, the amount of movement, and the duration of catheter insertion did not correlate significantly with positive shield cultures. The patient with the positive proximal catheter culture had the catheter in place for 2.9 days with intraoperative manipulations of 8, 5, and 4 cm insertions, 8 and 10 cm withdrawals, and no ICU manipulations. The distal shield remained constant during the operation and migrated 1 cm inward in the ICU. For the patient with the positive distal catheter culture, the catheter remained in the patient for 2.1 days, with inward intraoperative movement of 3 cm and outward movements of 3 cm and 1 cm. In the ICU, the proximal catheter was advanced 8 cm and withdrawn 2 cm. The distal shield remained constant without migration. Thus, the source of the positive catheter cultures is unclear.

No patient developed signs of localized or systemic infection secondary to pulmonary artery catheterization during the hospitalization period.

DISCUSSION

Although pulmonary artery catheters provide useful information during cardiopulmonary bypass, they do carry the risk of pulmonary artery perforation if the catheter migrates into small pulmonary vessels during extrapericardial manipulation of the heart.³ Hence, we and others⁴ routinely withdraw the catheter before bypass is begun. However, readvancement of the catheter into the patient may violate the sterility of the system, and catheter contamination has been cited as a cause of septicemia and bacterial endocarditis.^{5,6} The problem of maintaining a sterile segment of external catheter has prompted two modifications of the procedure: 1) adding a sterile plastic shield,^{1,2} and 2) filling the shield with a povidone–iodine solution.²

We did not use the second modification, however, further study of this technique is warranted, especially if the catheter is advanced after several days placement. Taping the distal diaphragm of the shield to the catheter may be effective in clinical practice to prevent unaccountable migrations. In our study without fixation, the

sheath tended to migrate inward, exposing previously sterile catheter, rather than outward.

Staphylococcus epidermidis is a common isolate from intravascular catheters, even in cardiac surgical patients.^{7–9} Its growth on catheters usually represents colonization and not infection.^{10–12} The semiquantitative culture technique described by Maki *et al.*, in which segments of the catheter are rolled over the surface of a sheep's blood agar plate, can differentiate catheter colonization from infection.¹³ We did not use that technique, since our catheters remained as central venous lines after we had obtained intrashield catheter cultures. As a consequence, our technique should overestimate the true incidence of catheter sepsis.

We conclude that external plastic shields maintain a sterile segment of pulmonary artery catheter for a 1–2 day period if inserted under rigorous sterile precautions (*i.e.*, sterile gown, gloves, drapes, povidone–iodine skin preparation, *etc.*). In this small series of patients, catheters were advanced or withdrawn as needed without serious infectious complications to the patient, despite the 6.7% incidence of *Staphylococcus epidermidis* cultured from intrashield catheters. The results should not be interpreted as evidence that catheters can be manipulated at a later time than those in this study or that catheters remaining a longer time after manipulation will not produce septic complications.

The authors express their appreciation to Mr. Bruce Kardon for his statistical consultation.

REFERENCES

1. Kopman EA, Sandza JG: Manipulation of the pulmonary-artery catheter after placement: Maintenance of sterility. *ANESTHESIOLOGY* 48:373–374, 1978
2. Gomez F, Spagna P, Lemole GM: Improved techniques in using the Swan–Ganz catheter. *Ann Thorac Surg* 27:468–471, 1979
3. Connors JP, Sandza JG, Shaw RC, Wolff GA, Lombardo JA: Lobar pulmonary hemorrhage. An unusual complication of Swan–Ganz catheterization. *Arch Surg* 115:883–885, 1980
4. Stone JG, Khambatta HJ, McDaniel DD: Catheter-induced pulmonary arterial trauma: Can it always be averted? *J Thorac Cardiovasc Surg* 86:146–150, 1983
5. Singh S, Nelson N, Acosta I, Check FE, Puri VK: Catheter colonization and bacteremia with pulmonary and arterial catheters. *Crit Care Med* 10:736–739, 1982
6. Green JF Jr, Fitzwater JE, Clemmer TP: Septic endocarditis and indwelling pulmonary artery catheters. *JAMA* 233:891–892, 1975
7. Freeman R, King B: Analysis of results of catheter tip cultures in open-heart surgery patients. *Thorax* 30:26–30, 1975
8. Freeman R, Hjersing N: Species of coagulase-negative staphylococci isolated from catheter tips from open-heart surgery patients. *Thorax* 35:355–359, 1981
9. Freeman R, Hjersing N, Burrige A: Catheter tip cultures on open-heart surgery patients: Association with site of catheter and age of patients. *Thorax* 36:355–359, 1981

10. Pinilla JC, Ross DF, Martin T, Crump H: Study of the incidence of intravascular catheter infection and associated septicemia in critically ill patients. *Crit Care Med* 11:21-25, 1983
11. Moyer MA, Edwards LD, Farley L: Comparative culture methods on 101 intravenous catheters. Routine, semiquantitative, and blood cultures. *Arch Intern Med* 143:66-69, 1983
12. Cleri DJ, Corrado ML, Seligman SJ: Quantitative culture of intravenous catheters and other intravascular inserts. *J Infect Dis* 141:781-786, 1980
13. Maki DG, Weise CE, Sarafin HW: A semiquantitative culture method for identifying intravenous catheter-related infection. *N Engl J Med* 292:1305-1309, 1977

Anesthesiology
61:464-466, 1984

Intravenous Nitroglycerin, Methemoglobinemia, and Respiratory Distress in a Postoperative Cardiac Surgical Patient

ANDREW M. ZURICK, M.D.,* REINHARD H. WAGNER, M.D.,† NORMAN J. STARR, M.D.,*
BRUCE LYTLE, M.D.,‡ FAWZY G. ESTAFANOUS, M.D.§

The use of nitrates for vasodilator therapy is a recognized method of therapy for angina pectoris and congestive heart failure.^{1,2} Nitrates, especially iv nitroglycerin, are also used intraoperatively for patients with coronary artery disease requiring surgery.² The World Health Organization has defined the acceptable daily intake of nitrates at 5 mg/kg and of nitrites at 0.4 mg/kg.³ Methemoglobinemia is a well-recognized result of exposure to nitrates; however, methemoglobinemia in levels of up to 20% is thought to be asymptomatic, not requiring specific therapy. Tolerant of these levels requires an adequate hemoglobin level, cardiac output, and extraction of oxygen at the tissue level. The current practices in surgery utilizing hemodilution to avoid exposure to homologous blood products may impose additional risk in patients requiring treatment with nitrates for coronary artery disease, since there will be a loss of functioning hemoglobin associated with a limited ability to increase cardiac output. Additionally, nitroglycerin therapy has been associated with hypoxemia as a result of alteration in V/Q relationships within the lung with generation of more areas of low V/Q.⁴

We recently observed a case of methemoglobinemia that was associated with pulmonary congestion and

respiratory distress in a postoperative cardiac surgical patient treated with iv nitroglycerin.

REPORT OF A CASE

A 55-year-old man, weighing 95 kg, had a diagnosis of severe atherosclerotic heart disease. He had suffered three prior myocardial infarctions during the period of 1978-1980 associated with congestive heart failure. His medications were nifedipine, 10 mg qid; isosorbide dinitrate, 10 mg qid; digoxin, 0.25 mg qd; and furosemide, 40 mg qd. He had a smoking history of 60 pack-years. Significant physical findings included an S-4 and a grade 2/6 systolic ejection murmur at the left sternal border. Cardiac catheterization revealed diffuse coronary artery disease with increased end-diastolic and end-systolic volumes associated with akinesia of the posterolateral, inferior, and apical portions of the left ventricle with an intraventricular clot. The left ventricular end-diastolic pressure (LVEDP) was 20-36 mmHg during the catheterization. For anesthesia he received fentanyl, 4 mg; diazepam, 10 mg; pancuronium, 20 mg, and O₂. The surgery included vein grafts constructed to the left anterior descending, right coronary, high lateral circumflex, and posteriolateral circumflex arteries. A left ventriculotomy was done to remove the ventricular clot. The patient received iv nitroglycerin throughout the procedure at a rate of 33-67 µg/min. Initial pulmonary capillary wedge pressure (PCWP) preinduction of anesthesia was 21 mmHg with a cardiac index of 1.56 l·min⁻¹·m². Following treatment with iv nitroglycerin, the PCWP decreased to 15 mmHg, and cardiac index increased to 2.7 l·min⁻¹·m². Following cardiopulmonary bypass, nitroprusside was required at 16-45 µg/min to maintain mean arterial pressure (MAP) 80-100 mmHg. These medications were continued for 25 h following surgery. Cardiopulmonary bypass was terminated with a left atrial pressure of 10-13 mmHg and a cardiac index (thermodilution) 2.2-2.7 l·min⁻¹·m². Ventilation was controlled the first postoperative night and the trachea extubated the next morning. His weight increased 5 kg from his preoperative weight. He then was given furosemide iv. He was hemodynamically stable, with left atrial pressure 20 mmHg, cardiac index 3.24 l·min⁻¹·m², mean arterial pressure 86 mmHg. PaO₂ was 80 mmHg with an FiO₂ of 0.45.

The vasodilators were weaned slowly over the first postoperative day. By the evening of the first postoperative day, the patient had developed both rales and rhonchi in both bases of the lung and required an increase in FiO₂ to 0.6 in order to maintain a PaO₂ of 65-74 mmHg. On the morning of the second postoperative day, the chest roentgenogram revealed bilateral areas of atelectasis and in-

* Staff Anesthesiologist.

† Academic affiliation. Fellow in Anesthesia.

‡ Staff Surgeon.

§ Chairman, Department of Cardiothoracic Anesthesia.

Received from the Departments of Cardiothoracic Anesthesia and of Thoracic and Cardiovascular Surgery, The Cleveland Clinic Foundation, 9500 Euclid Avenue, Cleveland, Ohio 44106. Accepted for publication February 27, 1984.

Address reprint requests to Dr. Zurick: Staff Anesthesiologist, Department of Cardiothoracic Anesthesia, 9500 Euclid Avenue, Cleveland, Ohio 44106.

Key words: Complications: methemoglobinemia. Surgery: cardiac, nitroglycerin.