

## Halothane Anesthesia Does Not Exacerbate Hepatic Dysfunction in Cirrhotic Rats

Mervyn Maze M.B. Ch.B. M.R.C.P. (UK),\* Christopher M. Smith, M.Sc.,† Jeffrey M. Baden, M.B. B.S., F.F.A.R.C.S., M.R.C.P. (UK)‡

The authors have refined a model of cirrhosis in the rat and used it to determine whether the administration of halothane anesthesia adversely affects preexisting liver disease. Male Wistar rats were placed on phenobarbital water and were assigned randomly to two groups. Group 1 rats were exposed by inhalation to carbon tetrachloride (CCl<sub>4</sub>) at weekly intervals for 12 exposures while Group 2 rats received only air. All treatment including phenobarbital then was withdrawn for 4 weeks. Rats then were bled for SGOT and SGPT determinations and 24 h later were exposed to 1.8% halothane in oxygen for 3 h (HAL); the remaining rats from each group were exposed to 100% oxygen for 3 h (O<sub>2</sub>). Twenty-four hours later, rats were killed and blood was obtained for SGOT and SGPT by cardiac puncture. Light microscopic histologic examination was performed blind on liver sections for cirrhosis and scored for superimposed acute focal necrosis. The weekly sublethal CCl<sub>4</sub> exposure resulted in histologically demonstrable cirrhosis in all surviving Group 1 animals. The mean (±SD) SGOT (128 ± 32 IU/l) and SGPT (86 ± 24 IU/l) values for the Group 1 rats were significantly greater ( $P < 0.01$ ) than those for Group 2 rats (98 ± 18 IU/l and 57 ± 12 IU/l, respectively). Cirrhotic animals showed neither deterioration in liver function nor acute liver cell necrosis after Hal compared with O<sub>2</sub>. However, Group 2 rats showed a modest but significant increase in SGOT ( $P < 0.05$ ) after HAL, while this change was not noted after O<sub>2</sub>. Thus, 1.8% halothane anesthesia in oxygen did not result in superimposition of acute liver cell injury in already cirrhotic rats. (Key Words: Avisthetics, volatile: halothane. Liver: cirrhosis; hepatotoxicity.)

THE INCIDENCE of chronic liver disease and the mortality rate from this condition progressively have increased over the last three decades.<sup>1</sup> Two-thirds of all chronic liver disease in the United States is alcohol induced, and the per capita ingestion of potentially cirrhogenic quantities of alcohol continues to escalate.<sup>2</sup> Thus, more patients with chronic liver disease are expected to present to anesthesiologists for management of their liver-related and coexisting surgical problems.

Whether anesthesia *per se* exacerbates liver dysfunction in patients with preexisting chronic liver disease is unknown. In one report, patients with cirrhosis undergoing surgical treatment of portal hypertension and bleeding esophageal varices had greater deterioration in liver function than patients with normal liver function undergoing cholecystectomy.<sup>3</sup> The lack of comparability between the study and control groups and the use of ether and cyclopropane for anesthesia lessen the validity of these results and their relevance to modern anesthetic practice.

There are many reasons why the assessment of appropriate anesthetic management of patients with liver disease has remained essentially uninvestigated. First, even in a relatively well-defined group such as alcoholic cirrhotics, the pattern and severity of the liver impairment are extremely variable. Thus, variance within experimental groups is large and statistical power low. Secondly, most of these patients already are being treated with a variety of drugs that may have their own effects on liver function. Thirdly, even if group sizes could be large enough to decrease variance, selecting appropriate variables to monitor deteriorating liver function can be difficult. Unfortunately, there is no single test, equivalent to glomerular filtration rate for renal function, that comprehensively will quantitate liver dysfunction; therefore, a combination of morphologic, biochemical, and functional tests must be used.

\* Assistant Professor of Anesthesiology.

† Research Assistant.

‡ Associate Professor of Anesthesiology.

Received from the Department of Anesthesia, Stanford University School of Medicine, Stanford, California, and the Anesthesiology Service, Veterans Administration Medical Center, Palo Alto, California. Accepted for Publication June 7, 1984. Supported in part by the Veterans Administration and the Department of Anesthesia, Stanford University. Presented in part at the 58th Congress of the International Anesthesia Research Society, Reno, Nevada, March 1984.

Address reprint requests to Dr. Maze: Anesthesia Service (112A), VA Medical Center, 3801 Miranda Avenue, Palo Alto, California 94304.

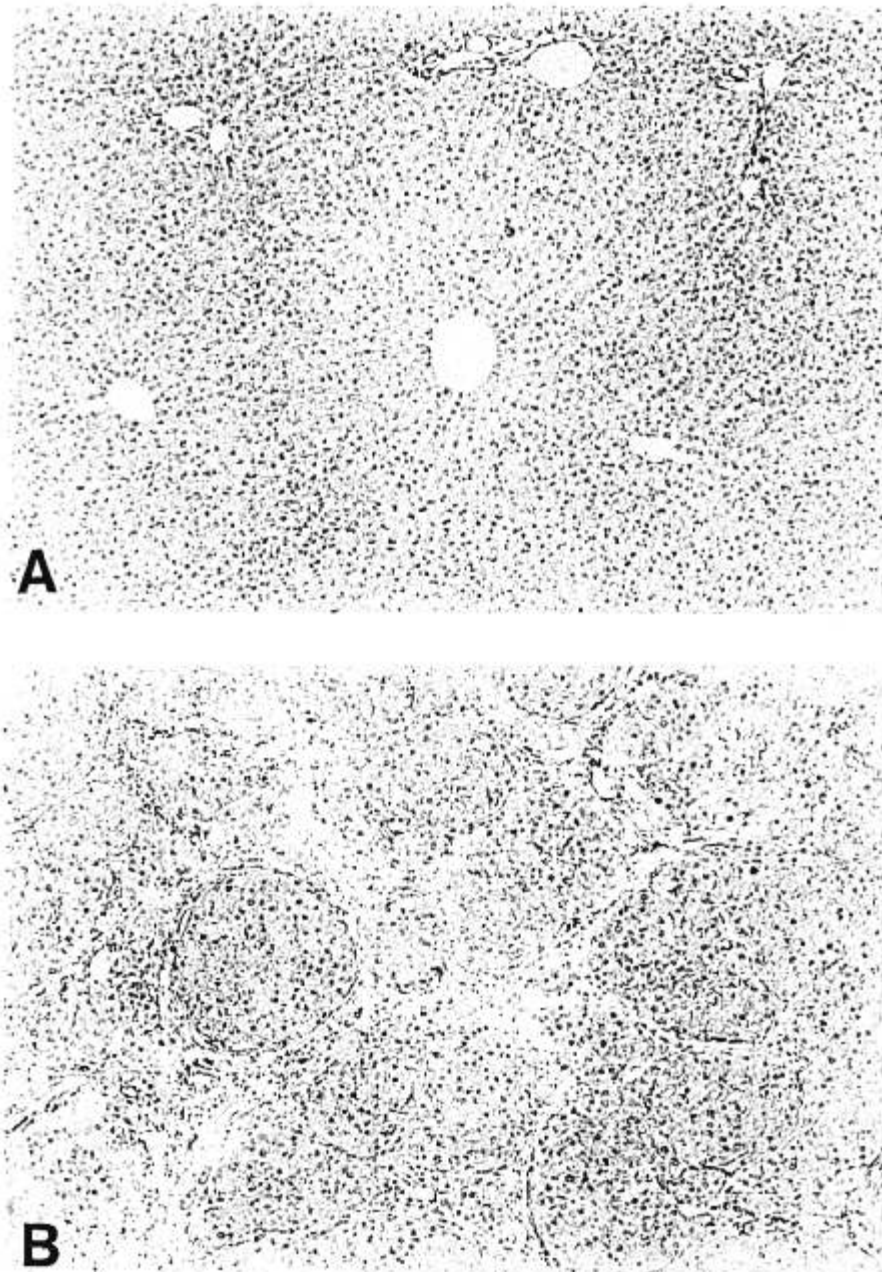


FIG. 1. Hematoxylin and eosin stained liver sections from normal (A) and carbon tetrachloride-treated rats (B) ( $\times 60$  magnification). The latter section is characteristic of the cirrhotic lesion as evidenced by the parenchymal nodules and fibrous septa that fully circumscribe the nodules and link the portal and central canals.

Lastly, it is difficult to separate the independent contributions of surgery and anesthesia on postoperative liver dysfunction.<sup>4</sup> In the present study, we have used a model of cirrhosis in the rat, modified from an earlier description by McLean *et al.*,<sup>5</sup> to explore the hepatotoxic potential of halothane in established liver disease.

#### Methods

Forty male Wistar rats, 150–200 g, were fed a stock pellet diet and given drinking water containing sodium phenobarbital 0.05% (w/v) and dextrose 5% (w/v)

(Group 1). After seven days they were exposed by inhalation to carbon tetrachloride ( $\text{CCl}_4$ ) at weekly intervals by the method of McLean *et al.*<sup>5</sup> In brief, a 160-l Plexiglas<sup>®</sup> chamber was charged for 10 min by introducing 2 l/min of fully saturated  $\text{CCl}_4$  vapor in air. This flow was maintained during exposure of rats, which at first was for 5 min but was increased step-wise to 15 min by the sixth week. Thereafter, the duration of exposure was maintained at 15 min for a further 6 weeks. Group 2 rats ( $N = 24$ ) received no  $\text{CCl}_4$  exposure during this 12-week period. Liver function tests then were performed on tail-blood samples by sequen-

tial multiple analysis (Technicon®) and again 4 weeks later after a period of no treatment. Group 1 and 2 rats then were assigned to one of the following treatments: halothane 1.8% v/v vaporized in 100% oxygen for 3 h (HAL) or 100% oxygen for 3 h (O<sub>2</sub>). Several rats in the halothane-treated group had their carotid artery cannulated under direct vision and their blood pressure monitored continuously. Arterial blood gases were measured at least twice on those rats during halothane exposure.

Twenty-four hours after treatment, rats were killed by exposure to 100% CO<sub>2</sub> for 1 min,<sup>6</sup> followed by cervical dislocation. Blood was obtained for SGOT and SGPT by cardiac puncture, and the liver was removed and separated into individual lobes. Light microscopic examination was performed blind on hematoxylin and eosin stained sections from each lobe. The sections were examined for cirrhosis and scored for superimposed focal necrosis using accepted histologic criteria.<sup>7</sup> A liver necrosis score for each animal was derived by averaging the number of necrotic foci per 100 mm<sup>2</sup> in 16 separate low-power (magnification ×100) fields. Data were analyzed by Students' paired and unpaired *t* tests where appropriate; *P* < 0.05 was considered statistically significant.

### Results

Fourteen Group 1 animals died during the initial period of CCl<sub>4</sub> exposure from massive hepatic necrosis. Twenty-six rats survived the course of CCl<sub>4</sub> treatment, and all had histologically demonstrable hepatic cirrhosis (fig. 1). The presence of cirrhosis could be predicted readily from the abnormalities in the liver function tests (notably the albumin/globulin ratio) that were performed after 12 weeks of CCl<sub>4</sub> exposure (table 1). Four weeks after CCl<sub>4</sub> treatment, the mean values (±SD) of SGOT (128 ± 32 IU/l) and SGPT (86 ± 24 IU/l) for Group 1 rats were still significantly greater (*P* < 0.01) than those for Group 2 rats (92 ± 18 IU/l and 57 ± 13 IU/l, respectively).

There were no statistically significant differences between the two groups in mean arterial pressure (MAP), PaCO<sub>2</sub>, PaO<sub>2</sub>, or blood glucose during the three hours of halothane anesthesia (table 2); both groups demonstrated significant hypercarbia, however.

Following halothane anesthesia, cirrhotic animals (Group 1) showed no further deterioration in liver function, as assessed by transaminase levels and liver necrosis indices (Figs. 2 to 4). Group 2 rats, however, showed a modest but statistically significant (*P* < 0.05) increase in SGOT (fig. 2). The mean liver necrosis index was not altered significantly in either group after halothane compared with oxygen treatment (fig. 4).

TABLE 1. Liver Function Tests\* for Cirrhotic (Group 1) and Control (Group 2) Rats

Group (n)†	SGOT‡ (IU/l)	SGPT‡ (IU/l)	Total Bilirubin‡ (mg/dl)	Albumin:Globulin‡
1 (26)	393 ± 49§	238 ± 38§	0.5 ± 0.1¶	0.94 ± 0.04¶
2 (24)	103 ± 24	48 ± 11	0.1 ± 0.03	1.2 ± 0.02

\* Tested at conclusion of CCl<sub>4</sub> exposures; see "Methods" in the text.

† Number of rats.

‡ Mean ± SD values.

§ *P* < 0.01.

¶ *P* < 0.05.

SGPT levels in cirrhotic rats were lower after oxygen treatment than before, indicating some improvement in liver function (fig. 3).

### Discussion

Subhuman primates are the only animals in which chronic administration of alcohol reliably results in the typical postnecrotic cirrhosis found in humans.<sup>8</sup> In rodents, progression beyond the fatty liver stage is rare, even after continuous high-dose administration of alcohol.

The rat model of cirrhosis was modified from a previously reported model.<sup>5</sup> Refinements were incorporated to increase the yield of cirrhosis and to decrease the mortality in the early stages. We added dextrose to the drinking water to prevent death from hypoglycemia, which often is seen during the first few weeks of CCl<sub>4</sub> treatment. Furthermore, we exposed rats to CCl<sub>4</sub> weekly rather than twice weekly to minimize the development of resistance to CCl<sub>4</sub> hepatotoxicity.<sup>9</sup> Because the genesis of cirrhosis is dependent on provoking repeated bouts of acute hepatic necrosis, we fasted the animals before exposure to enhance acute hepatotoxicity of CCl<sub>4</sub>.<sup>10</sup> The overall yield of viable cirrhotic animals by this modified technique was 65%.

Many similarities exist between CCl<sub>4</sub>-induced liver disease in the rat and cirrhosis in the human.<sup>11</sup> Hepatomegaly, splenomegaly, portosystemic shunts, varices, ascites, pleural effusions, poor synthetic function of the

TABLE 2. Cardiorespiratory Data for Cirrhotic (Group 1) and Control (Group 2) Rats during Halothane Anesthesia

Group (n)*	pH†	PaCO <sub>2</sub> † (mmHg)	PaO <sub>2</sub> † (mmHg)	MAP‡ (mmHg)
1 (9)	7.33 ± 0.04	153 ± 55	59 ± 8	75 ± 22
2 (11)	7.32 ± 0.06	189 ± 90	59 ± 6	71 ± 13

\* Number of rats.

† Mean ± SD values.

‡ Lowest mean arterial pressure.

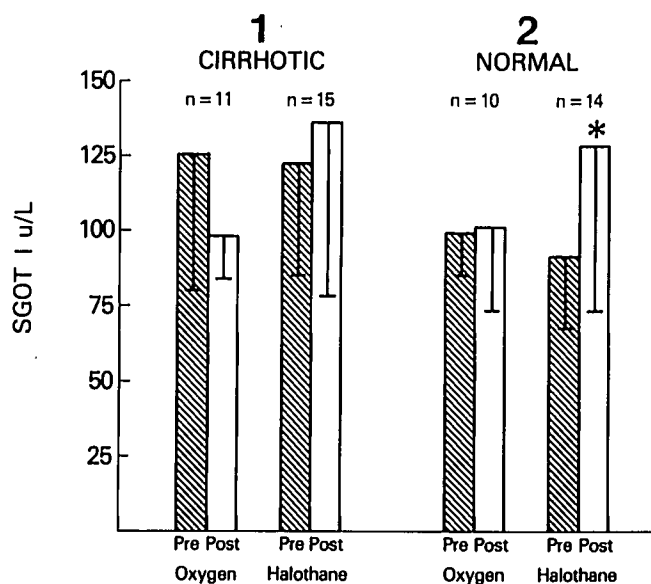


FIG. 2. Bar graph of mean  $\pm$  SD of SGOT levels for cirrhotic and normal rats before (pre) and after (post) either oxygen or halothane treatments. \* denotes significantly different from the pre value ( $P < 0.05$ ).

liver, coagulation problems, and testicular atrophy are common features. Thus, although we have the usual reservations for extrapolating animal data to humans, we believe that the rat model of  $\text{CCl}_4$ -induced cirrhosis is a valid one for examining the effects of anesthetics on liver function in the setting of preexisting liver disease.

Anesthesia with halothane 1.8% v/v (or about 1.5 MAC for the rat) in oxygen for 3 h did not result in superimposition of acute liver injury in cirrhotic rats, although it did result in slight liver dysfunction in the

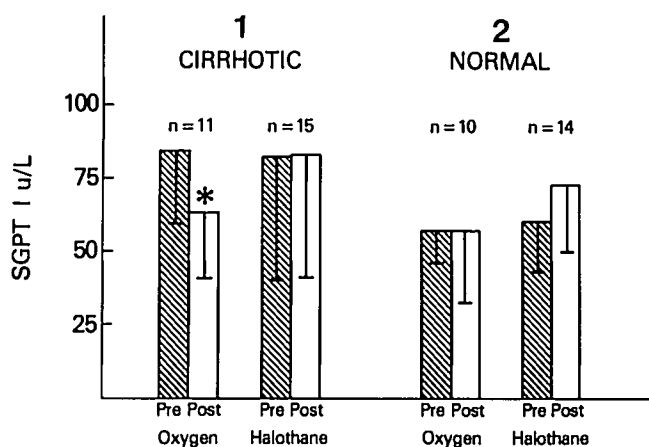


FIG. 3. Bar graph of mean  $\pm$  SD of SGPT levels for cirrhotic and normal rats before (pre) and after (post) either oxygen or halothane treatments. \* denotes significantly different from the pre value ( $P < 0.05$ ).

#### HEPATIC HISTOPATHOLOGY

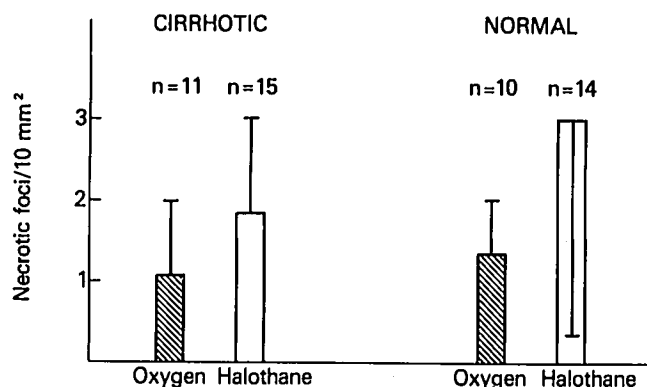


FIG. 4. Bar graph of mean  $\pm$  SD of necrotic foci index in the livers of cirrhotic and normal rats after oxygen or halothane treatment. Index derived from the average of 16 separate fields per animal.

normal rats. This suggests that the cirrhotic state confers some measure of resistance to halothane-induced hepatic dysfunction. A possible explanation is that biotransformation of halothane to hepatotoxic intermediates<sup>12</sup> is reduced in cirrhotic rats. The extent of halothane metabolism, however, was not assessed in this study. Another reason for their relative resistance to hepatotoxicity from halothane may be attributed to the cirrhotic rats being "selected out" as survivors of the  $\text{CCl}_4$ -induced lesion. However, more recent unpublished studies in our laboratory refutes this explanation, since we were able to produce further hepatic dysfunction by manipulation of the experimental conditions.

It is also possible that the modest hypercarbia present during anesthesia conferred "luxury" hepatic perfusion by its direct vasodilating effect on the splanchnic circulation.<sup>13</sup> While this effect may be necessary to maximize protection, it still does not explain the different effect that halothane had on liver function in normal and cirrhotic animals, since both groups were equally hypercarbic (table 2).

The high inspired oxygen concentration used in our study also must be considered when interpreting the results. Diminished hepatic oxygen delivery, secondary to halothane-induced cardiorespiratory depression, may be a critical factor in the anesthetic management of patients with liver disease, especially when hepatic perfusion already is compromised. Apparently, the high  $\text{FI}_{\text{O}_2}$  breathed during anesthesia did exert an ameliorative effect, since the SGPT significantly improved in the cirrhotic rats exposed to oxygen alone.

Volatile agents have distinct advantages over intravenous anesthetic agents in patients with liver disease.

First, they can be used with a high inspired oxygen concentration, which may be important in some cirrhotic patients with severe intrapulmonary shunting.<sup>14</sup> Secondly, alterations in pharmacokinetics from liver disease may occur through changes in hepatic blood flow, drug binding, volume of distribution, and drug biotransformation.<sup>15</sup> Although these factors are often important for the intravenous anesthetics, they are not important for the volatile anesthetics, which do not depend to any extent on the liver for their elimination. While this study does not purport to show that halothane is the most appropriate agent for use in patients with chronic liver disease, this study supports the contention that halothane anesthesia is not contraindicated in those patients.

### References

1. Schmidt W: The epidemiology of cirrhosis of the liver: A statistical analysis of mortality data with special reference to Canada, *in* Alcohol and the Liver. Edited by Fisher MM, Rankin JG. New York, Plenum Press, 1977, pp 1–26
2. Saunders JB: Alcoholic liver disease in the 1980's. *Br Med J* 287:1819–1821, 1983
3. French AB, Barss TP, Fairlie CS, Bengle AL, Jones CM, Linton BB, Beecher HK: Metabolic effects of anesthesia in man. V. A Comparison of the effects of ether and cyclopropane on the abnormal liver. *Ann Surg* 135:145–163, 1952
4. Gelman SI: Disturbances in hepatic blood flow during anesthesia and surgery. *Arch Surg* 111:881–883, 1976
5. McLean EK, McLean AEM, Sutton PM: Instant cirrhosis: An improved method for producing cirrhosis of the liver in rats by simultaneous administration of carbon tetrachloride and phenobarbitone. *Br J Exp Pathol* 50:502–506, 1969
6. Breazile JE, Kitchell RL: Euthanasia for laboratory animals. *Fed Proc* 28:1577–1579, 1969
7. Scheuer PJ: *Liver Biopsy Interpretation*. Baltimore, Williams and Wilkins, 1968, pp 55–69
8. Lieber CS: Animal models of ethanol dependence and liver injury in rats and baboons. *Fed Proc* 35:1232–1236, 1976
9. Glende EA: Carbon tetrachloride-induced protection against carbon tetrachloride toxicity. *Biochem Pharmacol* 21:1697–1702, 1972
10. Gomez MID, DeCastro CR, Ferreyra EC, D'Acosta N, DeFenos OM, Castro JA: Mechanistic studies on carbon tetrachloride hepatotoxicity in fasted and fed animals. *Toxicol Appl Pharmacol* 32:101–108, 1975
11. Tamayo RP: Is cirrhosis of the liver experimentally produced by CCl<sub>4</sub> an adequate model for human cirrhosis? *Hepatology* 3:112–120, 1983
12. Plummer JL, Beckwith ALJ, Bastin FN, Adams JF, Cousins MJ, Hall P: Free radical formation in vivo and hepatotoxicity due to anesthesia with halothane. *ANESTHESIOLOGY* 57:160–166, 1982
13. Thomson IA, Fitch W, Hughes RL, Campbell D: Effect of increased concentrations of carbon dioxide during halothane anaesthesia on liver blood flow and hepatic oxygen consumption. *Br J Anaesth* 55:1231–1237, 1983
14. Berthelot P, Walker JC, Sherlock S, Reid L: Arterial changes in the lungs in cirrhosis of the liver. *N Engl J Med* 274:291–298, 1966
15. Williams RL: Drug Administration in hepatic disease. *N Engl J Med* 309:1616–1622, 1983