

Verapamil: Placental Transfer and Effects on Maternal and Fetal Hemodynamics and Atrioventricular Conduction in the Pregnant Ewe

S. H. N. Murad, M.D.,* K. M. A. Tabsh, M.D.,† K. A. Conklin, M.D., Ph.D.,‡ G. Shilyanski, M.D.,§
F. Ziadlourad, M.D.,¶ P. A. Kapur, M.D.,¶ W. E. Flacke, M. D.**

Verapamil may have application in the field of obstetrics for treatment of maternal and fetal tachyarrhythmias. This study was performed to assess the maternal and fetal hemodynamic effects of this drug, as well as to determine its placental transfer and effects on maternal and fetal atrioventricular conduction in the pregnant ewe. Verapamil, 0.2 mg/kg, administered intravenously over 3 min, resulted in a transient decrease in maternal mean and diastolic blood pressures. There was, however, no significant change in fetal systolic, diastolic, and mean blood pressures. Maternal and fetal heart rates also were unchanged throughout the experiment. Atrioventricular conduction, assessed by measurement of PR intervals, was prolonged in both the ewe (41%) and the fetus (78%). Placental transfer of verapamil was limited, as shown by the umbilical vein to uterine artery drug concentration ratios of 0.35-0.45 throughout most of the experiment. Fetal hepatic extraction of the drug appeared to be substantial, since the drug concentration in the fetal carotid artery was less than that of the umbilical vein at 1, 3, and 5 min after drug injection. (Key words: Anesthesia: obstetric. Ions: calcium, blockers. Pharmacology: verapamil. Placenta: transfer, verapamil.)

CALCIUM CHANNEL-BLOCKING DRUGS have been used to treat a variety of medical problems, including supra-ventricular tachyarrhythmias, Prinzmetal's angina, angina pectoris, and systemic hypertension, and to control the ventricular rate in atrial fibrillation and flutter.¹ Although one may encounter a pregnant patient being treated with a calcium blocker for a medical condition, these agents may have direct application in the field of obstetrics. For example, Wolff *et al.* reported a case in which a fetal tachyarrhythmia (264-282 beats/min) associated with early cardiac failure responded favorably to maternally administered oral

verapamil plus beta-acetyldigoxin.² Calcium blockers also reduce contractions of the pregnant†† and non-pregnant³ uterus and may have value as tocolytic agents.⁴ Although reports of use of these agents in the pregnant patient are scarce at the present time, greater obstetric use of these drugs in the future is likely.

Verapamil has been studied extensively in humans and animal models and has been shown to possess negative inotropic and peripheral vasodilating effects and to prolong atrioventricular (AV) conduction time. Its actions, however, have not been studied in the pregnant animal model. Because it may be beneficial for treatment of fetal tachyarrhythmias,² knowledge of its placental transfer and effects on fetal atrioventricular conduction would have important implications for this clinical application. The objectives of our investigation were to determine the placental transfer and effects of verapamil on fetal and maternal hemodynamics and atrioventricular conduction time in the acutely instrumented pregnant ewe.

Materials and Methods

Nine pregnant ewes (weighing 50-59 kg) at 130-140 days gestation were used for the experiments following the research council's guide for the care and use of laboratory animals. Each animal was premedicated with xylazine, 0.3 mg/kg, intramuscularly, 1 h prior to the procedure. It then was placed in the lateral position and received diazepam, 2.5-6.5 mg, intravenously as needed to prevent the animal from moving. Under local anesthesia (30-40 ml 1% lidocaine) the following catheters were placed in the ewe: a femoral artery catheter for blood pressure (BP) monitoring, a femoral vein catheter for fluid and drug administration, and a middle uterine artery catheter for blood sampling. A hysterotomy then was performed and the following fetal catheters were placed: a carotid artery and an umbilical vein catheter for blood sampling, and a femoral artery catheter for BP monitoring. In ewes with twin gestations, only one fetus was instrumented. A fetal scalp electrode (Corometrics Medical Systems, spiral elec-

* Assistant Professor of Anesthesiology, Harbor/UCLA Medical Center.

† Associate Professor of Obstetrics and Gynecology, UCLA School of Medicine.

‡ Associate Professor of Anesthesiology, UCLA School of Medicine.

§ Fellow in Anesthesiology, Harbor/UCLA Medical Center.

¶ Assistant Professor of Anesthesiology, UCLA School of Medicine.

** Professor of Anesthesiology, UCLA School of Medicine.

Received from the Department of Anesthesiology, Harbor/UCLA Medical Center, Torrance, California, and the Departments of Anesthesiology and Obstetrics and Gynecology, UCLA School of Medicine, Los Angeles, California. Accepted for publication July 23, 1984.

Address reprint requests to Dr. Murad, Department of Anesthesiology, Harbor/UCLA Medical Center, 1000 Carson Street, Torrance, California 90509.

†† Golichowski AM, Hathaway DR, Jose MJL, Haeberle JR: Tocolytic and cardiovascular effects of nifedipine in the ewe. Abstracts, Society of Gynecologic Investigation, p 240, 1983.

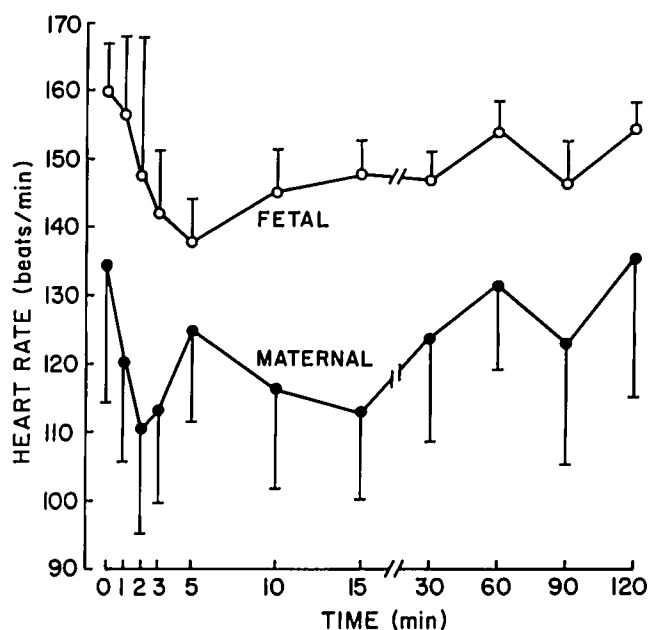


FIG. 1. Maternal (closed circles) and fetal (open circles) heart rate before (time 0, control) and at various times after intravenous injection of verapamil, 0.2 mg/kg. Values are mean \pm SEM. There is no significant difference between control and subsequent values.

trode) was placed on the left anterior chest wall of the fetus for ECG monitoring. The uterus and skin then were closed with clamps, and four metal needles were placed subcutaneously under the skin of the ewe for ECG monitoring. Blood pressures were monitored using Gould Statham® P23 ID pressure transducers (Model TA1010). Electrocardiograms and blood pressures were recorded using Physiocontrol® VSM1 monitors with recorders. The animal received Ringer's lactate at a rate of 2 ml/min throughout the procedure. Following a 1-h stabilization period, and prior to drug administration, blood samples were drawn from the maternal femoral artery and fetal carotid artery for blood gas analysis and verapamil assay blanks. Control hemodynamic variables and maternal and fetal electrocardiograms then were recorded.

Immediately prior to drug administration, infusion of Ringer's lactate was increased to 4 ml/min so as to match the rate at which the drug was to be given. Verapamil, 0.2 mg/kg, diluted to a total of 12 ml in Ringer's lactate, was injected over 3 min into the maternal femoral vein. The drug concentration in blood samples from the uterine artery, umbilical vein, and fetal carotid artery was determined at 1, 2, 3, 5, 10, 15, 30, 60, 90, and 120 min. The blood samples (2 ml whole blood) were collected in heparin-treated glass tubes. The plasma was separated by centrifugation, frozen, and later assayed for verapamil content by high-performance liquid chromatography using fluorescence detection according to the method of Watson

and Kapur.⁵ All experimental samples were assayed in duplicate.

Maternal and fetal arterial blood gases were measured at 0, 10, 30, 60, 90, and 120 min. Hemodynamic variables and ECG were monitored throughout the experimental period. Hemodynamic data were subjected to statistical analysis using analysis of variance for repeated measurements, with Bonferroni *t* test, accepting $P < 0.05$ as significant. Comparison of umbilical vein and fetal carotid artery verapamil concentrations was done using a nonpaired *t* test, accepting $P < 0.05$ as significant.

Results

MATERNAL AND FETAL HEMODYNAMICS

Hemodynamic parameters were stable throughout the 1-h period from instrumentation of the ewe until the beginning of the experiment (i.e., the time of verapamil injection). Maternal heart rate (HR) did not change significantly from control throughout the experiment (fig. 1). Maternal systolic blood pressure (SBP) also was not significantly different from control throughout the experiment (fig. 2). Maternal mean arterial blood pressure (MABP) and diastolic blood pressure (DBP), however, decreased for 5 min after drug administration (fig. 2). Fetal HR (fig. 1) and fetal systolic, mean and diastolic blood pressures (fig. 2) were not significantly different from control throughout the experimental period.

ATRIOVENTRICULAR CONDUCTION

The maternal PR interval was prolonged significantly from 2 until 5 min after drug administration (fig. 3). The control PR interval of 0.128 ± 0.014 s increased maximally (41%) to a value of 0.180 ± 0.013 s 5 min after drug injection. The fetal PR interval was increased significantly for the first 5 min of the experiment (fig. 3). The maximum increase in the fetal PR interval, observed at 3 min, was 78% (control of 0.092 ± 0.007 to 0.162 ± 0.010 s).

PLASMA VERAPAMIL CONCENTRATIONS

Figure 4 illustrates the plasma verapamil concentrations that were found in the uterine artery and umbilical vein. The initial uterine artery value, 1 min after drug injection, was 150 ± 30 ng/ml. Although the plasma level rapidly declined, detectable amounts of the drug still were present at 120 min. The initial umbilical vein verapamil concentration was 22.2 ± 5.2 ng/ml (fig. 4, table 1). The drug was detectable in the umbilical vein until 60 min, after which the amount

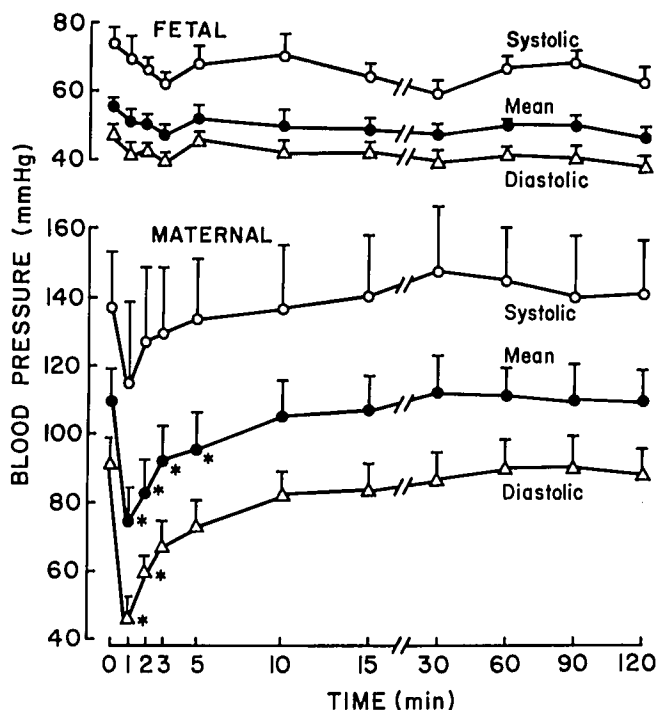


FIG. 2. Maternal and fetal systolic (open circles), mean (closed circles), and diastolic (open triangles) blood pressures before (time 0, control) and at various times after intravenous injection of verapamil, 0.2 mg/kg. Values are mean \pm SEM. Asterisks indicate a significant difference from control ($P < 0.05$).

found was less than the sensitivity of the assay procedure (2 ng/ml). The fetal carotid artery plasma level was significantly less than that of the umbilical vein at 1, 3, and 5 min after drug administration (table 1).

The initial (1 min) fetal-maternal drug concentration ratio between the umbilical vein and the uterine artery was 0.15 (fig. 5). By 5 min this ratio had increased to 0.38 and remained between 0.35 and 0.45 until 60 min.

MATERNAL AND FETAL BLOOD GASES

The control maternal arterial blood gas values were: pH , 7.41 ± 0.01 ; P_{O_2} , 98 ± 6 mmHg; and P_{CO_2} , 33 ± 3 mmHg. The control blood gas values from the fetal carotid artery were: pH , 7.25 ± 0.02 ; P_{O_2} , 20 ± 2 mmHg; and P_{CO_2} , 53 ± 2 mmHg. There was no significant change in maternal or fetal pH , P_{O_2} , or P_{CO_2} throughout the experiment.

Discussion

The hemodynamic effects of verapamil have been studied extensively in a variety of animal models, although investigations in pregnant animals are lacking. In this study, the maternal HR was unchanged in the

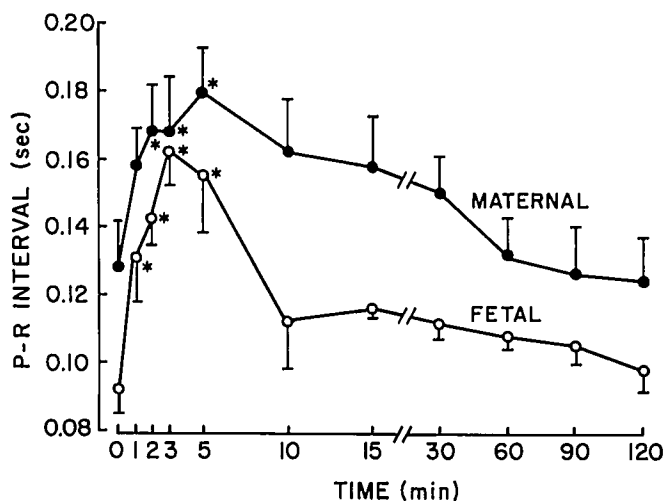


FIG. 3. Maternal (closed circles) and fetal (open circles) P-R interval before (time 0, control) and after intravenous injection of verapamil, 0.2 mg/kg. Values are mean \pm SEM. Asterisks indicate a significant difference from control ($P < 0.05$).

acutely instrumented pregnant ewe after intravenous administration of verapamil, 0.2 mg/kg. This is in contrast to observations in a variety of animal models⁶⁻¹¹ and in humans,¹² where tachycardia following verapamil occurs due to sympathetic stimulation via the baroreceptor mechanism. This response results from the

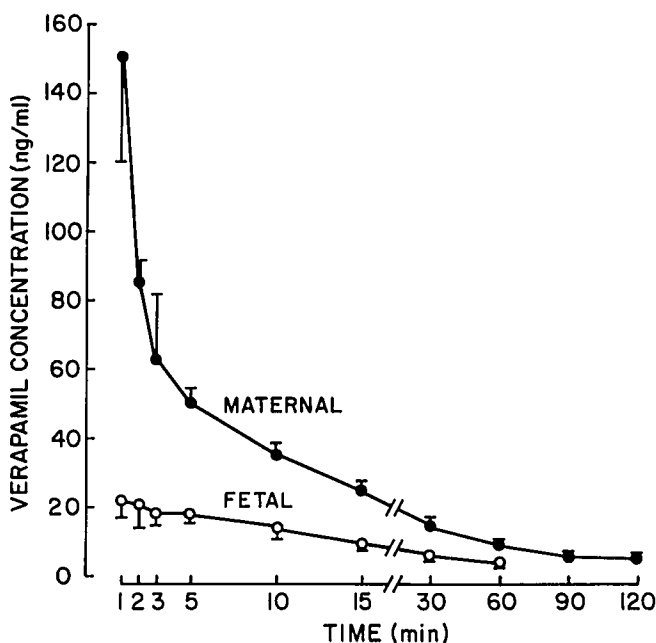


FIG. 4. Plasma verapamil concentrations in the uterine artery (closed circles) and umbilical vein (open circles) after intravenous injection of verapamil, 0.2 mg/kg. Values for the umbilical vein at 90 and 120 min were below the sensitivity of the assay procedure (2 ng/ml). Values are mean \pm SEM.

TABLE 1. Plasma Verapamil Concentrations in the Umbilical Vein (UV) and Fetal Carotid Artery (CA)

Time*	Plasma Level†	
	UV	CA
1	22.2 ± 5.2	9.7 ± 1.7‡
2	21.4 ± 7.4	8.9 ± 1.4
3	18.2 ± 3.4	9.2 ± 1.8‡
5	18.9 ± 2.8	7.0 ± 1.1‡
10	14.4 ± 3.2	7.6 ± 2.0
15	9.7 ± 1.9	6.0 ± 1.1
30	6.0 ± 1.0	4.2 ± 0.9
60	3.7 ± 0.6	2.5 ± 0.7

* Minutes after intravenous injection of verapamil, 0.2 mg/kg.

† Values in ng/ml ± SEM.

‡ Significant difference ($P < 0.05$) between UV and CA plasma levels.

direct effect of the drug on vascular smooth muscle, which produces peripheral vasodilation. Our results, however, may be explained by the elevated control maternal HR (135 beats/min), which is likely due to the fact that animals were used just 1 h following instrumentation, and they were sedated only enough to prevent movement. Thus, the reflex sympathetic stimulation may have been offset by the negative chronotropic effect of verapamil that occurs via depression of sinoatrial node discharge.¹ In the fetus, as in the ewe, no significant change in HR was noted.

There were significant but transient decreases in the maternal MABP and DBP after verapamil administration. These results are consistent with the direct peripheral vasodilating effects of the drug and are compa-

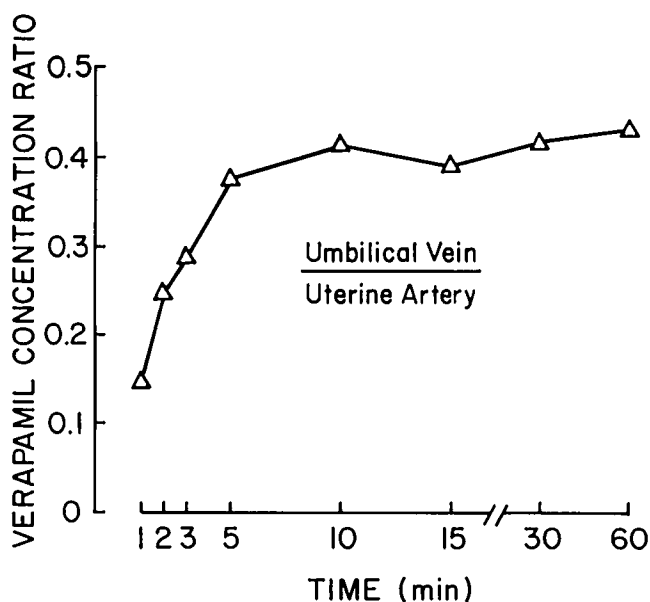


FIG. 5. Plasma verapamil concentration ratio: umbilical vein to uterine artery.

able to observations of others in animal models⁶⁻¹¹ and in humans.¹² Systolic BP, however, was unchanged throughout the experiment. The maintenance of SBP is likely due to the increase in sympathetic stimulation via the baroreceptor reflex, which can result in an increase in cardiac output.^{7,8,10-12} The short duration of the decreases in MABP and DBP can be attributed to the rapid decrease in verapamil concentration in maternal plasma, since these hemodynamic depressant effects are largely plasma-level related.¹⁵ In the fetus, SBP, MABP, and DBP did not change significantly from control throughout the experiment. The lack of effect of verapamil on fetal BP as compared with maternal BP is likely due to the absence of a high peak plasma level in the fetus.

Verapamil significantly prolonged AV conduction time as reflected by the increase in PR interval. The peak increase in the ewe and the fetus occurred at 5 and 3 min, respectively, after drug injection. Although the duration of the effect in the ewe and the fetus were the same (5 min), the relative magnitude of the response in the fetus (78% increase) was greater than that of the ewe (41% increase). This may be due to the fact that the control PR interval of the fetus (0.092 ± 0.007 s) was substantially less than that of the ewe (0.128 ± 0.014 s) or possibly that a fetal myocardial conduction system is more sensitive to the drug. The effect of verapamil on AV conduction has been well documented by other investigators in animals^{6,11,14-17} and humans.¹⁸ Certain of our findings compare favorably with those of others,^{6,11,16,18} e.g., the peak effect of verapamil on the PR interval occurred within 10 min of drug injection. However, the duration of the effect observed here (5 min) was considerably less than others have found (60 min) in the anesthetized dog.¹¹ The reason for this difference is unclear.

Verapamil crossed the placenta to a limited degree. Although the drug was detected in the fetal circulation within 1 min, after 3 min the fetal/maternal drug concentration ratio remained between 0.35 and 0.45 until 60 min. These results are similar to those observed by others who have measured placental transfer in humans at the time of delivery. Wolff *et al.*,² in two patients, found the fetal/maternal ratio to be 0.17 and 0.26 when blood samples were obtained 49 and 109 min, respectively, after oral verapamil administration. Strigl *et al.*¹⁹ found the mean ratio from seven patients to be 0.51 when parturients received a continuous infusion of verapamil during the second stage of labor. Although one might anticipate a higher fetal/maternal ratio due to ion trapping of verapamil (pK_a 8.5) in the fetal circulation (because the fetal pH is less than the maternal pH), other factors must limit its placental transfer. One of these may be its high degree of protein binding in maternal plasma.²⁰ It is also of interest to

note the initially (1, 3, and 5 min) higher drug concentrations in the umbilical vein as compared with the fetal carotid artery. One explanation for this may be the relatively high hepatic extraction ratio for verapamil.²¹ Since blood from the umbilical vein perfuses the fetal liver before entering the systemic circulation of the fetus, hepatic uptake of the drug may account for this observation.

Finally, it is important to note that our experiments were performed 1 h after instrumentation, for which the animals received drugs that could alter the cardiovascular variables recorded. For example, diazepam (in doses larger than those employed in these experiments) causes maternal and fetal tachycardia and maternal hypertension in the pregnant ewe.²² Lidocaine can produce peripheral vasodilation and myocardial depression. Although these effects may have altered our control measurements, we did not detect any change in the cardiovascular variables during the 1-h stabilization period, as might be expected with declining blood levels of diazepam and lidocaine. Furthermore, the presence of these drugs may have altered the cardiovascular responses to verapamil. Although this possibility cannot be excluded, drug interactions also would have been a concern if these experiments were performed during general anesthesia.

In conclusion, intravenous administration of verapamil in the pregnant ewe resulted in maternal and fetal cardiovascular effects that are consistent with its pharmacologic properties. Atrioventricular conduction was prolonged in both the ewe and the fetus. However, while the ewe had high peak verapamil plasma levels, and concomitantly decreased blood pressure, the fetus had low plasma levels and exhibited only the conduction prolongation effect of the drug. Placental transfer of verapamil was limited, as shown by the fetal-maternal ratios of 0.35 to 0.45 throughout most of the experiment. This information pertaining to the fetal response to maternally administered verapamil and placental transfer of the drug may have implications for the use of this agent for treatment of fetal tachyarrhythmias.

References

1. Reves JG, Kissin I, Lell WA, Tosone S: Calcium entry blockers: Uses and implications for anesthesiologists. *ANESTHESIOLOGY* 57:504-518, 1982
2. Wolff F, Breuker KH, Schlensker KH, Bolte A: Prenatal diagnosis and therapy of fetal heart rate anomalies: with a contribution on the placental transfer of verapamil. *J Perinat Med* 8:203-207, 1980
3. Forman A, Andersson KE, Ulmsten U: Combined effects of diflunisal and nifedipine on uterine contractility in dysmenorrhoeic patients. *Prostaglandins* 23:237-246, 1982
4. Ulmsten U, Andersson KE, Wingerup L: Treatment of premature labor with the calcium antagonist nifedipine. *Arch Gynecol* 229:1-5, 1980
5. Watson E, Kapur PA: High-performance liquid chromatographic determination of verapamil in plasma by fluorescence detection. *J Pharm Sci* 70:800-801, 1981
6. Nakaya H, Schwarz A, Millard RW: Reflex chronotropic effects of calcium-channel-blocking agents in conscious dogs. *Circ Res* 52:302-311, 1983
7. Newman RK, Bishop VS, Peterson DF, Leroux EJ, Horowitz LD: Effect of verapamil on left ventricular performance in conscious dogs. *J Pharmacol Exp Ther* 201:723-730, 1977
8. Walsh RA, Badke FR, O'Rourke RA: Differential effects of systemic and intracoronary calcium channel blocking agents on global and regional left ventricular function in conscious dogs. *Am Heart J* 102:341-350, 1981
9. Norfleet EA, Heath KR, Kopp VJ, Sprague DH, Corke BC: Verapamil—different cardiovascular responses during N₂O analgesia and halothane anesthesia (Abstract). *ANESTHESIOLOGY* 57:A75, 1982
10. Neugebauer G: Comparative cardiovascular actions of verapamil and its major metabolites in the anesthetized dog. *Cardiovasc Res* 12:247-254, 1978
11. Angus JA, Richmond DR, Dhumma-Upakorn P, Cabbin LB, Goodman AH: Cardiovascular action of verapamil in the dog with particular reference to myocardial contractility and atrioventricular conduction. *Cardiovasc Res* 10:623-632, 1976
12. Vincenzi M, Allegri P, Gabaldo S, Maiolino P, Ometto R: Hemodynamic effects caused by i.v. administration of verapamil in healthy subjects. *Arzneimittelforsch* 26:1221-1223, 1976
13. Kapur PA, Flacke WE: Lack of correlation of verapamil plasma level with cumulative protective effects against halothane-epinephrine ventricular arrhythmias. *J Cardiovasc Pharmacol* 4:652-657, 1982
14. McAllister Jr RG, Bourne DWA, Dittert LW: The pharmacology of verapamil. I. Elimination kinetics in dogs and correlation of plasma levels with effect on the electrocardiogram. *J Pharmacol Exp Ther* 202:38-44, 1977
15. Mangiardi LM, Hariman RJ, McAllister Jr RG, Bhargava V, Surawicz B, Shabetai R: Electrophysiologic and hemodynamic effects of verapamil. Correlation with plasma drug concentrations. *Circulation* 57:366-372, 1978
16. Kapur PA, Flacke WE: Epinephrine-induced arrhythmias and cardiovascular function after verapamil during halothane anesthesia in the dog. *ANESTHESIOLOGY* 55:218-225, 1981
17. Millard RW, Lathrop DA, Grupp G, Ashraf M, Grupp IL, Schwartz A: Differential cardiovascular effects of calcium channel blocking agents: potential mechanisms. *Am J Cardiol* 49:499-505, 1982
18. Heng MK, Singh BN, Roche AHG, Morris RM, Mercer CJ: Effects of intravenous verapamil on cardiac arrhythmias and on the electrocardiogram. *Am Heart J* 90:487-498, 1975
19. Strigl R, Gastroph G, Hege HG, Doring P, Mehring W: Nachweis von Verapamil in mütterlichen und fetalen Blut des Menschen. *Geburtshilfe Frauenheilkd* 40:496-499, 1980
20. Schomerus M, Spiegelhalter B, Stieren B, Eichelbaum M: Physiological disposition of verapamil in man. *Cardiovasc Res* 102:605-612, 1976
21. Woodcock BG, Schulz W, Kober G, Reitbrock N: Direct determination of hepatic extraction of verapamil in cardiac patients. *Clin Pharmacol Ther* 30:52-56, 1981
22. Conklin KA, Graham CW, Murad S, Randall FM, Katz RL, Cabalum T, Lieb SM, Brinkman CR III: Midazolam and diazepam: maternal and fetal effects in the pregnant ewe. *Obstet Gynecol* 56:471-474, 1980