

Anesthesiology
62:185-187, 1985

Ventricular Tachycardia Resulting from Central Venous Catheter Tip Migration Due to Arm Position Changes: Report of Two Cases

GREGORY W. KASTEN, M.D.,* EDDIE OWENS, M.D.,* DOUGLAS KENNEDY, M.D.†

Ventricular dysrhythmias sometimes occur when flow-directed pulmonary artery catheters are passed through the right ventricle.^{1,2} This complication is usually self-limiting and not of major consequence.^{1,2} We cared for two patients who experienced sustained ventricular tachycardia following insertion of long arm central venous catheters via the basilic vein. Both episodes of ventricular tachycardia appeared to be triggered by changes in the arm position following insertion of the catheter. Following these cases, we examined the effect of arm position on the migration of the catheter tip in a cadaver.

REPORT OF TWO CASES

Case 1. The patient was a 62-year-old, 89-kg man scheduled for a right upper lobectomy for lung carcinoma. Medical history was significant for hypertension and a 50 pack/year smoking history. Medications included alpha methyl dopa and hydrochlorothiazide. He denied any history of angina, myocardial infarction, congestive heart failure, diabetes, or renal disease. Past surgical operations included appendectomy and inguinal hernia repair under spinal anesthesia. Arterial blood pressure was 130/70 mmHg, heart rate 78 bpm and respiratory rate 20 breaths/min. Airway, cardiac, and respiratory examination was within normal limits. Laboratory values included a serum potassium of 4.1 mEq/l, sodium 145 mEq/l, blood urea nitrogen 20 mg/dl, creatinine 1.0 mg/dl and hematocrit 47%. With a $F_{I_{O_2}}$ of 0.12, arterial blood gas analysis revealed that the pH_a was 7.43, P_{aCO_2} 47 mmHg, and P_{aO_2} 81 mmHg. The 12-lead ECG showed a normal sinus rhythm, rate 68 bpm and no abnormalities. Pulmonary function tests showed a forced vital capacity of 3.46 l (73% of predicted) and a forced expired volume in 1 s of 2.2 l (68% of predicted).

The patient was premedicated with 10 mg morphine, 50 mg hydroxyzine, and 0.3 mg glycopyrolate im. Arterial blood pressure was 150/90 mmHg, heart rate 90 bpm, and respiratory rate 20 breaths/min. The ECG showed normal sinus rhythm. The right radial artery was cannulated with a 20-gauge catheter after a normal Allen's test and continuous arterial pressures were monitored.

A 61-cm, 16-ga plastic catheter (Intracath®, Deseret Medical, Inc.) was passed through a 14-ga needle with the use of the right basilic vein. The arm was abducted 90 degrees out at this time. The

catheter was inserted easily and approximately 3 cm of the catheter was outside the vein when it was anchored to the skin. The manometer reading was 2 cmH₂O with good fluctuation with respiration. Anesthesia was induced with *d*-tubocurarine 3.0 mg, diazepam 5.0 mg, fentanyl 50 µg, thiopental 100 mg, lidocaine 100 mg, and succinylcholine 100 mg iv. His trachea was intubated easily with a 39 French double lumen endobronchial tube, both cuffs were inflated, and tracheal and bronchial tubes were clamped alternately, demonstrating proper placement. The lowest arterial blood pressure throughout induction of anesthesia was 120/79 mmHg, and the ECG showed normal sinus rhythm. Esophageal stethoscope, oral temperature probe, and oral airway were inserted, and pancuronium 6 mg and fentanyl 100 mcg were given iv. Ventilation was controlled and 50% oxygen and 50% nitrous oxide given.

The patient then was placed in a left-side-down position, with the right arm pulled across the chest in a manner such that the right hand rested near the left shoulder. Bilateral breath sounds were confirmed in the new position. The ECG monitor then demonstrated sustained runs of ventricular tachycardia with greatly reduced perfusion pressure on the arterial waveform display. A bolus of 100 mg of lidocaine was given iv, ventilation controlled with the $F_{I_{O_2}}$ 1.0, and bilateral breath sound were confirmed again. Arterial blood-gas analysis revealed that the pH_a was 7.55, P_{aCO_2} was 24 mmHg, P_{aO_2} was 238 mmHg, and BE 1.4 mEq/l. Ventricular tachycardia persisted. A CVP reading at this time showed a reading of 30 cmH₂O with a large fluctuation in the manometer fluid level. The patient was placed in supine position, and the arm was abducted again to 90 degrees. At the same time, the central venous pressure (CVP) line was pulled back 4 cm. Immediately, the heart rhythm converted to normal sinus rhythm. The CVP line was anchored at this point (approximately 7 cm from the vein), and no further ectopy was present. The patient was turned to the left-side-down position with no arrhythmias. He tolerated the operation well and showed no signs of ectopic beats in the 24-h period following the surgery while being monitored in the intensive care unit.

Case 2. The patient was a 62-year-old man who entered the hospital for evaluation of claudication. He had a long history of vascular disease and had several previous vascular surgical procedures performed. Other history included myocardial infarction 3 years prior, transient ischemic attacks, chronic obstructive pulmonary disease, chronic active hepatitis, and a seizure disorder. One month before admission, the patient was found to have a right pleural effusion and mild elevation of the right hemidiaphragm. The only medications the patient was receiving was phenytoin 300 mg every day and phenobarbital 45 mg daily.

Arterial blood pressure was 128/76 mmHg, and heart rate was 76 beats/min. A faint apical murmur was heard on cardiac examination and slight wheezing was noted on auscultation of the chest. The ECG revealed a sinus rhythm with left bundle branch block. The chest roentgenogram showed mild hyperinflation of the lungs, normal heart size, and mild elevation of the right hemidiaphragm. The hematocrit was 44%, serum sodium was 133 mEq/l, potassium 4.2 mEq/l, chloride 99 mEq/l, and CO_2 27 mEq/l.

Anesthesia was induced with 100 µg of fentanyl and 125 mg of thiopental iv. Endotracheal intubation was facilitated by the admin-

* Assistant Professor of Anesthesiology.

† Resident, Department of Anesthesiology.

Received from the Department of Anesthesiology, University of Kentucky Medical Center, Veterans Administration Medical Center, Lexington, Kentucky. Accepted for publication August 8, 1984.

Address reprint requests to Dr. Kasten: Department of Anesthesiology, University of Kentucky, Lexington, Kentucky 40536-0084.

Key words: Complications: ventricular tachycardia. Veins: basilic, cannulation.

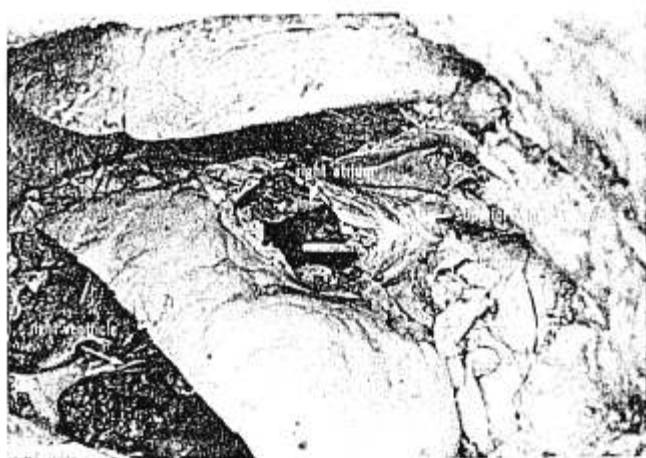

FIG. 1. Position of the central venous catheter in the right atrium with the arm abducted to 90 degrees.

istration of 8 mg of pancuronium iv. Anesthesia was maintained by 0.5 to 1.0% isoflurane and 50% nitrous oxide. The patient was in the supine position with arms abducted. Central venous pressure was monitored using a 16-ga, 61-cm catheter (Intracath,[®] Deseret Medical, Inc.) inserted via the right basilic vein at the antecubital fossa. The intraoperative period was uneventful: systolic arterial blood pressure ranged between 90 and 130 mmHg; the central venous pressure was 4–18 cm H₂O; the ECG revealed normal sinus rhythm throughout the surgery, which consisted of repair of a left femoral artery pseudoaneurysm with placement of an interpositional graft. Anesthesia time was 7 h and 45 min. The patient awakened shortly after arrival in recovery room. His strength was quite good, his ventilation was judged to be adequate, and the trachea was extubated.

Approximately 10 min later, the patient sat up in bed, moved his arms close to his chest, and complained that he could not breathe (breath sounds were normal on physical examination at this time). Seconds later, the patient became cyanotic, collapsed back into the bed, and was noted to be in ventricular fibrillation. Resuscitation was prompt and included external cardiac massage, electrical defibrillation, ventilation via Ambu[®] bag and mask, and reinsertion of the endotracheal tube.

Lidocaine, 100 mg, was administered as a bolus iv, followed by a second bolus of 75 mg a few minutes later, and a constant infusion of lidocaine was begun at 4 mg/min. Over the next 2 hr, the patient had frequent bursts of multifocal premature ventricular beats with occasional short runs of ventricular tachycardia. The patient was hemodynamically stable in spite of the ectopy. Auscultation of the chest revealed good breath sounds bilaterally. Laboratory values obtained following the resuscitation showed a serum potassium of 3.7 mEq/l; analysis of arterial blood gases obtained during the resuscitation (Ambu[®] bag with supplemental oxygen administered) revealed a PaO₂ of 75 mmHg, a PaCO₂ of 40 mmHg, a pH_{7.22}, and a base excess of -8.3 mEq/l. The metabolic acidosis was corrected by the administration of iv sodium bicarbonate.

A 12-lead ECG obtained in the recovery room showed sinus tachycardia, left bundle-branch block, and frequent premature ventricular contractions. No other changes were noted compared to the preoperative ECG.

As 250 mg bretylium tosylate was being infused slowly, a portable chest roentgenogram obtained shortly after resuscitation revealed normal heart size, good positioning of the endotracheal tube, lungs free of acute disease, and continuing mild elevation of the right hemidiaphragm. The position of the central venous pressure line

was judged to be in the right atrium near the tricuspid valve. The arms were abducted to 90 degrees when the roentgenogram was taken. Following this, the patient moved his arms to a more adducted position. The ventricular ectopy continued.

The central venous pressure catheter was withdrawn approximately 5 cm. The ventricular ectopy immediately ceased, allowing weaning of the lidocaine infusion over the next few hours. Serial ECGs were unchanged from that obtained before surgery; serial cardiac isoenzymes revealed no evidence of myocardial infarction. The remainder of the intensive care unit stay was uneventful, and the patient was moved to a ward bed on the fourth postoperative day.

METHODS AND RESULTS

We decided to examine if arm position changes could cause a migration of the CVP catheter tip position. A cadaver was obtained that had been embalmed commercially. This method of embalming removes more blood from the major vessels and allows easier passage of catheters. The cadaver was prepared by exposing the right ventricle, right atrium, and superior vena cava. Using a Fogarty catheter, all debris was removed from the venous system between the superior vena cava and the right basilic vein. This allowed the catheter to pass freely in the venous system. A 16-ga, 61-cm catheter (Intracath[®] Deseret Medical, Inc.) was inserted into the right basilic vein with the arm abducted 90 degrees. A stylet was required in the catheter to allow passage through the venous system. The catheter then was advanced through the venous system until the tip was in the right atrium approximately 0.5 cm above the tricuspid valve (fig. 1). The catheter then was sutured securely in place at the point of insertion in the antecubital fossa. After this, the arm then was abducted across the chest in such a manner so that the right wrist was touching the left shoulder. This change in arm position resulted in the catheter tip advancing approxi-

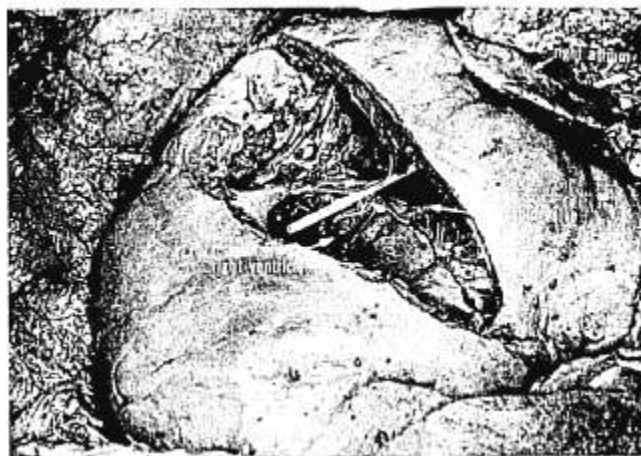


FIG. 2. Position of the central venous catheter following adduction of the arm across the chest. Note that the catheter tip now resides in the right ventricle.

mately 2.8 cm. The final position of the catheter in the right ventricle is shown in figure 2. The arm was abducted again to 90 degrees and the catheter tip moved back to its original position in the right atrium.

DISCUSSION

We believe that both episodes of ventricular tachycardia in our two patients resulted from the CVP catheter tip touching the endocardium of the right ventricle. Ventricular dysrhythmias can occur when flow directed pulmonary artery catheters are passed through the right ventricle.^{1,2} These pulmonary artery catheters have the advantage of the inflated balloon covering the catheter tip and being less irritating to the ventricle.³ The CVP catheter tip is not covered by an inflatable balloon and could be expected to be at least as irritating as the pulmonary artery catheter. The sudden change in CVP manometer reading in case 1 from 2 cmH₂O to 30 cmH₂O strongly suggests that the catheter entered the right ventricle. In both cases 1 and 2, the ventricular arrhythmias completely ceased upon pulling the CVP catheter back 4 to 5 cm.

The question arose as how the catheter tip entered the right ventricle. Initial placement suggested either the superior vena cava or right atrium, based on manometer height and pulsation. Both episodes of dysrhythmias occurred shortly after the arm position was changed from 90 degrees abduction to a position of the arm lying much more adducted. Our examination of the cadaver showed that the catheter tip does advance if the arm is moved from 90 degrees abduction to a position of the arm lying across the chest. We suspect that the initial placement of the CVP catheter in both of these cases was in the right atrium near the tricuspid valve. Upon moving the arm from 90 degrees abduction to a position across the chest, the catheter tip advanced into the right ventricle. The catheter tip irritated the right ventricle and resulted in the severe ventricular dysrhythmias. It is interesting that the administration of lidocaine in case 1 and lidocaine with bretylium in case 2 was ineffective in restoring sinus rhythm. This is in accordance with the results of Salmenperä *et al.*, who found that prophylactic lidocaine did not prevent ventricular arrhythmias during pulmonary artery catheterization.² Thus, it is apparent that usual antiarrhythmic agents are not effective when the cause of the arrhythmias is mechanical stimulation.

When placement of a CVP line is attempted via the antecubital fossa route, several points deserve emphasis.

First, placement should be in the superior vena cava rather than the right atrium, unless the possibility of air embolism is great.⁴ Placement of the catheter in the right atrium can result in atrial arrhythmias or, should the tip migrate forward into the ventricle, ventricular arrhythmias can result. The position of the CVP tip can be confirmed by chest roentgenogram. If at all possible, this should be done soon after the placement of the catheter. Once placed, the possibility of forward migration, particularly with arm movement, always should be kept in mind.

If the CVP line is connected to a transducer, monitoring the pressure waveform will allow identification of a change from atrial to ventricular placement. Alternatively, a sudden increase in water manometer height and pulsation will suggest ventricular position. Sudden onset of ventricular arrhythmias that do not respond to standard antiarrhythmic drugs in patients with CVP catheters should suggest the possibility of ventricular placement.

In summary, these cases and the investigation of the cadaver suggest that when the central venous catheter is placed near the tricuspid valve with the arm abducted, serious ventricular arrhythmias can result should the arm position change and move the catheter tip into the right ventricle. Earlier investigations of the placement of CVP catheters via peripheral veins did not describe this migration or arrhythmia problem.^{5,6} For surgical cases in which arm position will be altered after insertion of the catheter, we recommend that placement of the catheter be in the superior vena cava. In patients with sudden onset of ventricular arrhythmias, migration of the central venous catheter into the ventricle should be included in the differential diagnosis.

REFERENCES

1. Elliott G, Zimmerman GA, Clemmer JP: Complications of pulmonary artery catheterization in the care of critically ill patients. *Chest* 76:647-653, 1979
2. Salmenperä M, Peltola K, Rosenberg P: Does prophylactic lidocaine control cardiac arrhythmias associated with pulmonary artery catheterization? *ANESTHESIOLOGY* 56:210-212, 1982
3. Miller RD: *Anesthesia*. New York, Churchill Livingstone, 1981, pp 189-191
4. Michenfelder JD, Martin JT, Altenburg BM, Rehder K: Air embolism during neurosurgery. *JAMA* 208:1353-1358, 1969
5. Kellner GA, Smart JF: Percutaneous placement of catheters to monitor "central venous pressure." *ANESTHESIOLOGY* 36: 515-517, 1972
6. Holt MH: Central venous pressure via peripheral veins. *ANESTHESIOLOGY* 28:1093-1095, 1967