

- infusions in the management of very severe tetanus. *Intensive Care Med* (In press)
8. Kerr JH, Corbett JL, Prys-Roberts C, Crampton Smith A, Spalding JMK: Involvement of the sympathetic nervous system in tetanus. *Lancet* 2:236-241, 1968
  9. Keilty SR, Gray RC, Dundee JW, McCullough H: Catecholamine levels in severe tetanus. *Lancet* 2:195-197, 1968
  10. Mroczek WJ, Lee WR, Davidow ME: Effect of magnesium on cardiovascular haemodynamics. *Angiology* 28:720-724, 1977
  11. Somjen GG, Baskerville EN: Effect of excess magnesium on vagal inhibition and acetylcholine sensitivity of the mammalian heart in situ and in vitro. *Nature* 217:679-680, 1968
  12. Levin RM, Haugaard N, Hess ME: Opposing actions of calcium and magnesium on the metabolic effects of epinephrine in the rat heart. *Biochem Pharmacol* 25:1963-1969, 1976
  13. Paddle BM, Haugaard N: Role of magnesium in effects of epinephrine on heart contraction and metabolism. *Am J Physiol* 221:1178-1184, 1971

Anesthesiology  
62:190-193, 1985

## Airway Management in a Patient with Sleep Apnea Using a Permanent Silicone Tracheal Cannula

FREDERICK A. HENSLEY, JR., M.D.,\* MICHAEL T. SNIDER, M.D., PH.D.,†  
MICHAEL A. ORSINI, M.D.,‡ ROGER J. CADIEUX, M.D.§

The sleep apnea syndrome, if not detected and appropriately treated, can have life-threatening implications.<sup>1,2</sup> Apnea, defined as complete airflow cessation for greater than 10 s,<sup>2</sup> has been divided into three types by Gastaut *et al.*:<sup>3</sup> central, mixed, and obstructive. Obstructive sleep apnea is by far the most prevalent type,<sup>4</sup> and a tracheostomy that can be closed during the day and opened at night has become the treatment of choice for this condition.<sup>5</sup>

During the last 5 years, more than 100 tracheostomies have been performed at our institution for obstructive sleep apnea, and the airway most frequently inserted is the silicone tracheal cannula<sup>¶</sup> (STC) (fig. 1A). This permanent tracheostomy tube is easily inserted, is incon-

spicuous, maintains normal speech, and hence has been well accepted by patients.<sup>6,7</sup> This STC has an internal diameter of 8 mm, with a wall thickness of 1 mm. An inner flange secures the cannula to the anterior tracheal wall to prevent anterior displacement. Immediately following insertion, a wing-shaped faceplate secures the cannula to the skin of the neck to prevent posterior displacement. After healing of the tracheostomy, a ring washer replaces the faceplate. (fig. 1B). During waking hours, the patient obstructs the lumen with a plug. During sleep the plug is removed to provide an alternative airway and thus prevents upper airway obstruction. Because of the more frequent and anticipated widespread use of this STC in the treatment of sleep apnea, we report the anesthetic management of a patient with such an airway undergoing peripheral surgery.

### REPORT OF CASE

A 60-year-old man, weighing 67 kg, was admitted for arthroplasties of his right hand. His history was significant for severe steroid-dependent arthritis, recently diagnosed sleep apnea, and associated multifocal premature ventricular contractions. Since his apnea was related to upper airway obstruction, an STC had been inserted under local anesthesia 1 month prior to the current admission. Subsequently, Holter monitoring revealed a marked decrease in the frequency of his ventricular dysrhythmias. Posttracheostomy evaluation in our Sleep Laboratory during the current admission showed no airway obstruction during sleep, but residual central sleep apneic activity persisted (*i.e.*, less than 30 events during an 8-h period). Examination of the tracheostomy and STC was unremarkable. Prior to tracheostomy he had undergone multiple general anesthetics with endotracheal tubes for joint surgery without complication.

There are no reports available concerning the management of the airway containing a STC during general anesthesia. Therefore, we questioned whether 1) this thin-walled tube would accept and support

\* Assistant Professor of Anesthesia, The Milton S. Hershey Medical Center, The Pennsylvania State University.

† Associate Professor of Anesthesia and Physiology, The Milton S. Hershey Medical Center, The Pennsylvania State University.

‡ Assistant Professor of Otorhinolaryngology, The Milton S. Hershey Medical Center, The Pennsylvania State University.

§ Assistant Professor of Psychiatry, Sleep Research and Treatment Center, The Milton S. Hershey Medical Center, The Pennsylvania State University.

Received from the Departments of Anesthesia, Physiology, and Otorhinolaryngology and the Sleep Research and Treatment Center, The Milton S. Hershey Medical Center, The Pennsylvania State University, Hershey, Pennsylvania. Accepted for publication August 8, 1984.

Address reprint requests to Dr. Hensley: Department of Anesthesia, Milton S. Hershey Medical Center, 500 University Drive, Hershey Pennsylvania 17033.

Key words: Airway: silicone tracheal cannula. Ventilation: Sleep apnea.

¶ Manufactured by Boston Medical Products, Inc., 180 Cambridge Street, Boston, Massachusetts 02114.

a standard endotracheal tube connector without kinking or being displaced; 2) controlled mechanical ventilation could be maintained in face of a large retrograde pharyngeal air leak around this uncuffed tube; 3) a soft cuffed small bore endotracheal tube could be placed safely from above without displacing or permanently collapsing the unremoved tracheostomy tube; 4) the STC should be removed and replaced by an orally placed endotracheal tube for surgery; 5) the STC should be removed and the tracheal stoma directly intubated. Accordingly, we planned our anesthetic management to answer these questions.

**Operative Management:** The patient received 100 mg hydrocortisone im 1 h prior to coming to the operating room. After starting an iv infusion and monitoring the ECG, the end-tidal CO<sub>2</sub> by infrared analyzer, and arterial blood pressure by cuff, we performed an uneventful halothane oxygen inhalation induction by using both the face mask and tracheostomy tube connected in series, thus allowing the patient to breathe both through his upper airway by mask and tracheostomy simultaneously. Should upper-airway obstruction occur, the patient breathes solely through the STC. This modification of the standard anesthesia circuit is shown in figure 2. From the inspiratory limb of a standard anesthesia circuit, oxygen and halothane were delivered at high flow first to a standard T-connector. This T was connected to the tracheostomy tube via a bronchoscopy swivel adapter\*\* and a 7.0-mm\*\* endotracheal tube connector. The other side of the T was connected to a 12-inch length of respiratory tubing, leading to a Y-tube that was connected to the mask and expiratory limb. Airway management was satisfactory during spontaneous ventilation with this arrangement. During the long maintenance period of anesthesia, we tried other modes of airway management. The tracheostomy tube was plugged and the mask connected to a routine circle system. Not surprisingly, much difficulty was encountered in maintaining the airway. Even with both nasal and oral airways, upper airway obstruction only partially was relieved. Subsequently, the tracheostomy was unplugged and attached to the standard circle system. Although spontaneous ventilation was possible, attempts at controlled ventilation were impossible because of a large retrograde air leak through the larynx. This leak was blocked easily with a hypopharyngeal pack, and controlled ventilation was possible. As the procedure progressed, we noticed that the cannula had rotated because of the weight of the T-connector and the corrugated anesthesia tubing. To check the intratracheal alignment of the tracheostomy tube, a 4-mm pediatric bronchoscope was passed transnasally. The hypopharyngeal pack was removed and the bronchoscope advanced to the level of the cervical trachea. The cannula was found to be rotated and displaced posteriorly, thus obstructing one-third of the tracheal lumen. We externally manipulated the outer rim of the tracheal cannula under bronchoscopic visualization and restored it to its correct position. The bronchoscope was removed and, under deep halothane anesthesia, the trachea was intubated with an oral 7.0-mm endotracheal tube. We used the bronchoscope to verify that the tracheal cannula was neither deformed nor displaced by the act of intubation or the presence of the endotracheal tube. After the surgery was completed, the endotracheal tube was removed under deep halothane anesthesia, and emergence was uneventful without associated apnea or dysrhythmias. Monitoring for possible apnea in the postanesthesia recovery period was facilitated by use of an end-tidal CO<sub>2</sub> monitor and ear oximeter.

#### DISCUSSION

Since the use of the STC is becoming popular at many institutions, more and more patients will appear

\*\* Manufactured by Portex Inc., 421 Industrial Way, Wilmington, Massachusetts 01887.

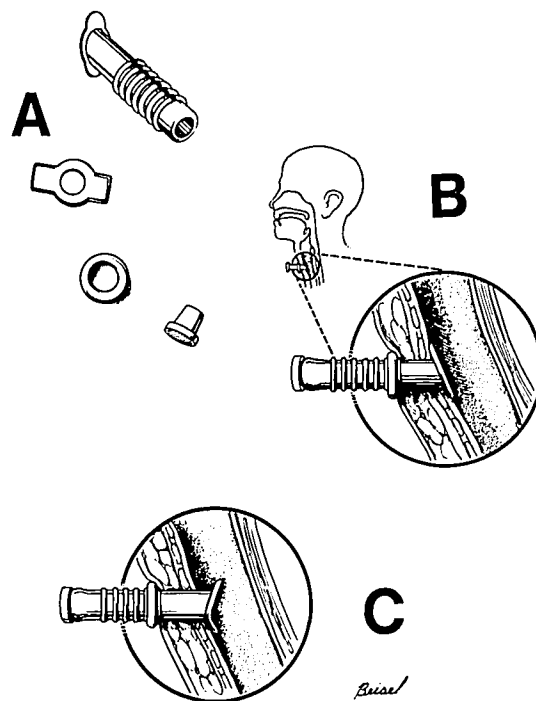


FIG. 1A. Components of the silicone tracheal cannula from counter clockwise direction: cannula—note groove on the inferior aspect, wing face plate, ring washer, removable plug. B. Sagittal section of trachea showing tracheal cannula in proper position. Notice that the superior portion of the outer securing ring fits firmly against the skin. C. Sagittal section of trachea showing improper position of tracheal cannula, with inner flange projecting into the lumen of the trachea.

for elective and emergency surgery with this airway in place. Although the anesthetic airway management of other nonstandard tracheostomy tubes, such as the T-tube, have been described,<sup>8,9</sup> no reports in the literature could be found concerning this relatively new type of airway. Even if regional anesthesia is planned, a clear

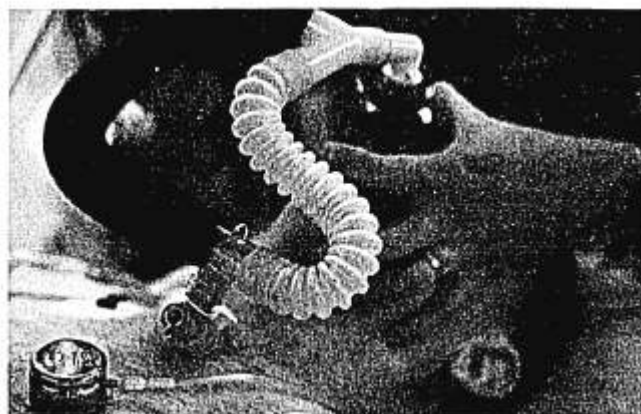


FIG. 2. Tubing system for attaching outlet limb of the Y-piece to tracheal cannula. Upper and lower airway entry points are ventilated simultaneously.

understanding of the tube design and possible alternatives in airway management, should a general anesthetic be required, are essential. Preoperative evaluation of such a patient involves clarification of the patient's current respiratory status as well as examination of the tube for proper position and patency. This is accomplished first by identifying a longitudinal groove located on the inferior aspect of the tube, which serves as a reference guide for proper rotary alignment of the cannula. (fig. 1A) If the cannula is accidentally rotated 180 degrees so that the groove is in a superior position, the angulated inner flange will protrude into the trachea and partially will obstruct the lumen (fig 1C). In addition, the superior portion of the outer securing washer should be pushed tightly against the skin; otherwise, the inner flange will not be held flush against the anterior wall of the lumen (fig. 1B). If both the groove and securing washer are aligned properly, then the tube should be in the correct position. If the position still is questioned, a lateral neck roentgenogram can be used to verify the alignment.

Patency of the cannula also should be demonstrated before induction of anesthesia by unplugging the tube and temporarily occluding the patient's nose and mouth. Prior to induction of anesthesia, one must decide whether the tracheal cannula should be removed and what type circuit should be used to adequately ventilate the patient during induction. When considering the removal of the STC, one must know if it is chronically or acutely placed. Like a conventional tracheostomy, there is danger of losing the airway in the first 5–7 days after placement of the STC since at this time a preserved tract has not yet been formed and, hence, recannulation may be impossible. A chronically placed STC does have a preserved tract. However, at our institution neither patient nor physician removes or replaces these tubes once placed for sleep apnea. Severe bleeding into the airway can occur from disruption of the granulation tissue formation around the grooves of the cannula if removed. Indeed, the tube is designed so that granulation tissue permanently will seat the STC. Removal, therefore, could lead to loss or compromise of the tracheal airway, which could be disastrous. This is especially true if an experienced surgeon is not present. For these reasons it is our opinion that, unlike the conventional tracheostomy, there is a greater risk in temporary removal of the STC and replacement with an alternate airway into the tracheal stoma. We therefore would recommend its removal only under emergency conditions that would preclude oral or nasal intubation and packing of the hypopharynx (*e.g.*, massive facial trauma). Only an experienced surgeon should remove the tube under these special circumstances.

Our preferred anesthetic circuit for induction and early maintenance of anesthesia utilizes a circle system with tracheostomy and face mask in series (fig. 2). Disadvantages with this arrangement involve possible displacement, rotation, or kinking of the cannula due to the weight of the connecting apparatus. With this circuit, the mask replaces the hypopharyngeal pack and prevents the efflux of a positive-pressure inflation through the larynx. There is minimal rebreathing. The dead space added between the T- and the Y-connectors by the additional tubing is only 60 ml. In actuality, the dead space is less because the fresh gas flow flushes the connecting tubing during the expiratory pause and early inspiration. Indeed, measurements made with infrared CO<sub>2</sub> monitors during spontaneous and controlled ventilation under anesthesia in patients fitted with this series circuit show only 1 torr inspired CO<sub>2</sub> at the mask, when the fresh gas flow is 10 l/min.

Other techniques of airway management during anesthetic induction may be utilized. In fact, this patient subsequently has undergone two peripheral joint surgery procedures, both involving two different methods of airway maintenance during induction. For the first, an iv induction of anesthesia was employed after the STC was plugged, with ventilation via mask and oral airway. For the second procedure, the patient had a satisfactory inhalation induction via the tracheostomy with occlusion of the upper airway. Again, with this technique, care must be taken not to displace the tube.

Maintenance of anesthesia probably is best accomplished by oral intubation of the trachea with a soft cuffed, small bore endotracheal tube, which can be placed easily without displacing the cannula. As long as the STC is in proper position, and plugged, the position of the endotracheal tube cuff in relation to the tracheostomy is of little significance. After extubation of the trachea and during the emergence and recovery phase, the tracheal cannula should be unplugged to provide a good airway. Special care and observation also is considered necessary in the recovery phase if a component of central apnea is present, since we do not know the effects of residual anesthetics in this circumstance.

Anesthetic management for emergencies in patients who recently have eaten finally must be discussed. Preoxygenation via the tracheostomy with occlusion of the upper airway followed by rapid intravenous induction and intubation would seem the most logical choice. If trouble was encountered with intubation in elective or emergency cases, a pharyngeal pack could be inserted and the patient ventilated by the tracheostomy.

In conclusion, proper anesthetic management of a patient with a STC in place begins with preoperative assessment to ascertain correct alignment and patency

of the cannula. Multiple alternatives to anesthetic induction have been discussed in both the elective and emergency situation. Endotracheal intubation is the preferred method of airway management during maintenance of anesthesia.

The authors thank Barbara Furio and Tina Taylor for their help in the preparation of this manuscript.

#### REFERENCES

1. Lugaresi E, Collagna G, Mantovani M: Hypersomnia with Periodic Apneas. New York, Spectrum Publications, 1978, pp 27-58
2. Guilleminault C, Van Den Hoed J, Mitler MM: Clinical overview of the sleep apnea syndrome, Sleep Apnea Syndromes. Edited by Guilleminault C, Dement W. New York, Alan R Liss, 1978, pp 1-12
3. Gastaut H, Tassinari CA, Duron B: Polygraphic study of the episodic, diurnal, and nocturnal manifestations of the pickwick syndrome. Brain Res 2:167-186, 1966
4. Sukerinan S, Healy GB: Sleep apnea syndrome associated with upper airway obstruction. The Laryngoscope 89:878, 1979
5. Guilleminault C, Simmons FB, Motta J: Obstructive sleep apnea syndrome and tracheostomy. Arch Intern Med 141:985-988, 1981
6. Montgomery WW: Silicone tracheal cannula. Ann Otol 89:521-528, 1980
7. Orsini M, Conner G, Cadieux R, Kales A: Clinical experience with the silicone tracheal cannula in obstructive sleep apnea. Otolaryngol Head Neck Surg 92:132-135, 1984
8. Lane GA, Steude GM, Pashley NT: Anesthesia for a patient with a tracheal t-stent. Anesth Analg 60:218-219, 1981
9. Rah LH, Griffith RL, Jones R, Salzberg M: Anesthetic management of the pediatric patient with a tracheal t-tube. Anesth Analg 60:445-447, 1981

Anesthesiology  
62:193-195, 1985

### Cerebrospinal Fluid Concentration of 5-Hydroxyindoleacetic Acid in Pregnancy

FRED J. SPIELMAN, M.D.,\* ROBERT A. MUELLER, M.D., PH.D.,† BARRY C. CORKE, M.B., CH.B., F.F.A.R.C.S.‡

Anesthetic requirement is reduced during pregnancy.<sup>1</sup> Perhaps increased tolerance to pain during pregnancy might modify the discomfort of labor and delivery, which could involve naturally occurring neuropeptides thought to influence pain perception. Plasma beta-endorphin levels during pregnancy increase progressively, reaching their highest concentration at delivery.<sup>2</sup> However, Steinbrook *et al.*<sup>3</sup> observed that cerebrospinal fluid (CSF) levels of beta-endorphin did not change over the course of pregnancy or during labor.

Serotonin is a neurotransmitter that plays a significant role in nociperception. Studies using pharmacologic, surgical electrophysiologic, and dietary manipulations demonstrate that increased activity of central nervous system serotonergic neurons are associated with analgesia, whereas decreased activity of the transmitter

correlate with hyperalgesia.<sup>4,5</sup> The major metabolite of serotonin is 5-hydroxyindoleacetic acid (5-HIAA). Levels of 5-HIAA may provide direct information on the functional state of serotonergic neurons.<sup>6</sup> Because CSF levels of serotonin or 5-HIAA in pregnancy have not been determined, we quantitated the release of 5-HIAA in maternal CSF during successive states of pregnancy and labor.

#### METHODS

Approval for this investigation was obtained from our Committee on the Protection of the Rights of Human Subjects. Subjects for the study were selected from patients who received spinal anesthesia. Four groups of 10 patients were studied: pain-free nonpregnant women, ages 18-40 years, undergoing elective surgery; women having cervical cerclage at 13-18 weeks' gestation; women having an elective repeat cesarean section at term; and women at term in painful active labor. No subject received narcotic, sedative, or oxytocic medications prior to the operation. All patients had not eaten for at least 4 h before the procedure. The sample of CSF consisted of the first 2 ml aspirated from a 25-gauge needle. All samples were kept in a freezer (-60°) until analysis was performed (no longer than 2 weeks). 5-HIAA levels were determined using high-pressure liquid chromatography described by Kilts *et al.*<sup>7</sup> All values were corrected for loss during storage. Recovery

\* Assistant Professor of Anesthesiology and Obstetrics and Gynecology.

† Professor of Anesthesiology and Pharmacology.

‡ Associate Professor of Anesthesiology and Obstetrics and Gynecology.

Received from the Department of Anesthesiology, University of North Carolina School of Medicine, Chapel Hill, North Carolina 27514. Accepted for publication August 8, 1984. Sponsored by USPHS NS 17509.

Address reprint requests to Dr. Spielman.

Key words: Anesthesia: obstetric. Cerebrospinal fluid: serotonin, 5-hydroxyindoleacetic acid.