

Anesthesiology  
62:206, 1985

## Grand Mal Seizures Following Fentanyl-Lidocaine

*To the Editor:*—In experimental animals, seizure activity has followed the administration of high-dose fentanyl (200–400  $\mu\text{g}/\text{kg}$ ).<sup>1</sup> However, grand mal seizures recently have been reported in two patients after the use of much smaller doses of fentanyl (100–200  $\mu\text{g}$ ). Neurologic and EEG examinations of these patients were negative.<sup>2,3</sup> The present case illustrates the occurrence of grand mal seizures following a fentanyl-lidocaine sequence.

The patient was a 24-year-old female, 60-kg body weight, who was scheduled for mitral valve replacement because of severe mitral stenosis. She was premedicated with morphine 10 mg, scopolamine 0.4 mg, and promethazine 25 mg. The patient came to the operating room in a sleepy condition. Anesthesia was induced with a bolus of fentanyl 10  $\mu\text{g}/\text{kg}$ , which was injected over 2 min, while the patient was breathing 100% oxygen. Multiple premature ventricular contractions (PVCs) were observed, which were controlled by intravenous lidocaine 2 mg/kg. The PVCs disappeared, but the patient developed repeated episodes of grand mal seizures. Diazepam 10 mg could control the seizures. Subsequent anesthesia and surgery were uneventful. Postoperative neurologic examination was negative.

These grand mal seizures may be attributed to lidocaine administration. However, the small dose of lidocaine used incriminates the previous injection of fentanyl as a predisposing factor. It is possible that the threshold convulsive dose of lidocaine is diminished by prior fentanyl administration.

ANIS BARAKA, M.D.  
SANIA HAROUN, M.D.  
*Department of Anesthesiology  
American University of Beirut  
Beirut, Lebanon*

## REFERENCES

1. Carlsson C, Smith DS, Keykhah MM, Englebach I, Harp JR: The effects of high-dose fentanyl on cerebral circulation and metabolism in rats. *ANESTHESIOLOGY* 57:375–380, 1982
2. Safwat AM, Daniel D: Grand mal seizures after fentanyl administration. *ANESTHESIOLOGY* 59:78, 1983
3. Hoiem AO: Another case of grand mal seizures after fentanyl administration. *ANESTHESIOLOGY* 60:387–388, 1984

(Accepted for publication September 10, 1984.)

Anesthesiology  
62:206–207, 1985

## A Neglected Source of Nitrous Oxide in Operating Room Air

*To the Editor:*—As a noninvasive monitoring technique, intraoperative measurement of end-tidal  $\text{CO}_2$  is a common practice. Some of these  $\text{CO}_2$  monitors require rather high-flow rates for sampling of gases, e.g., 150 ml/min for the Datex<sup>®</sup> Normocap  $\text{CO}_2$  monitor or 200 ml/min for the NEC San-ei Expired Gas Monitor 1H21A<sup>®</sup>. Wasted sampling gases from these machines are another source<sup>1</sup> of air pollution in the operating room. Recently, we measured nitrous oxide concentrations in the breathing zone<sup>2</sup> of the anesthetist while a  $\text{CO}_2$  monitor was in use.

In a well-ventilated room with a nonrecirculating supply of 13 air exchanges per hour, while the NEC San-ei Expired Gas Monitor 1H21A<sup>®</sup> was in use and with the anesthesia waste gas scavenger on (anesthesia gas flow of  $\text{N}_2\text{O}$  41/min,  $\text{O}_2$  21/min), nitrous oxide concentrations were below 25 PPM. However, in a poorly ventilated room (room ventilator off), nitrous oxide concentrations went up to around 100 PPM in an hour. Thus, in a poorly ventilated operating room,  $\text{CO}_2$

monitor waste gas should be scavenged as well as anesthesia waste gases. Indeed, when  $\text{CO}_2$  monitor waste sampling gas was scavenged, we were able to keep the nitrous oxide concentration below 25 PPM.

MASAO YAMASHITA, M.D.  
*Senior Lecturer*

SHUICHI SHIRASAKI, M.D.  
*Resident in Anesthesia*

AKITOMO MATSUKI, M.D.  
*Associate Professor*

*Department of Anesthesiology  
Hiroaki University  
School of Medicine  
Hiroaki 036  
Japan*

REFERENCES

1. Wray RP: A source of nonanesthetic nitrous oxide in operating room air. *ANESTHESIOLOGY* 52:88-89, 1980

2. Kaarakka P, Malischke PR, Kreul JF: Alternative sites for measuring breathing zone N<sub>2</sub>O levels. *ANESTHESIOLOGY* 55:A139, 1981

(Accepted for publication September 10, 1984.)

Anesthesiology  
62:207, 1985

Lamp Placement and the Miller I Laryngoscope Blade

To the Editor:—In the June 1984 issue of *ANESTHESIOLOGY*, Dr. Diaz described the modifications of the straight Miller blade, suggested to facilitate laryngoscopy.<sup>1</sup> The Miller I blades currently available differ considerably from that originally described and illustrated by Dr. Miller.<sup>2</sup> He recognized the necessity of

placing the lamp close to the distal end of the blade for adequate laryngeal illumination.

I have modified the Welch-Allyn Miller I blade by removing the distal 13 mm of the blade and refashioning the distal end with a slight curve. Figure 1 shows the standard Welch-Allyn and Penlon Miller I blades and the shortened Welch-Allyn version. The modified blade has a working length of 67 mm, compared with the original 80 mm length. On laryngoscopy, the lamp is closer to the larynx, greatly improving illumination. With the manufacturer's models, the pharyngeal and paraepiglottic tissues often prolapse onto the lamp.

For patients up to 6 months of age, the shortened blade has no disadvantages.

R. D. M. JONES  
Director of Anaesthesia  
The Grantham Hospital  
125 Wong Chuk Hang Road  
Aberdeen, Hong Kong

REFERENCES

1. Diaz JH: Further modifications of the Miller blade for difficult pediatric laryngoscopy. *ANESTHESIOLOGY* 60:612-613, 1984
2. Miller RA: A new laryngoscope. *ANESTHESIOLOGY* 2:317-320, 1941

(Accepted for publication September 10, 1984.)

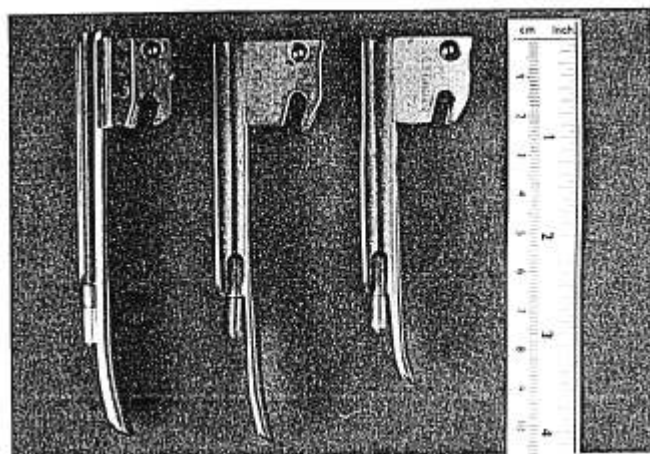


FIG. 1. Left: Standard Penlon Miller I blade. Middle: Standard Welch-Allyn Miller I blade. Right: Shortened Welch-Allyn Miller I blade.

Anesthesiology  
62:207-208, 1985

A Case of Artifactual S-T Depression

To the Editor:—Recently, during a routine cholecystectomy, new and significant S-T segment depression appeared on our Hewlett-Packard® #78304A ECG monitor. This occurred while we monitored lead II (fig. 1). Fortunately, the depression lasted only a few minutes and resolved spontaneously without treatment.

After resolution, we checked all the lead wire attachments; each was well secured. Then, accidentally, we found that minor movement of the patient cable holding the lead wires could produce or terminate the S-T segment changes at will.

The New Dimensions in Medicine (NDM) fully shielded ECG lead wire with snap electrode connector

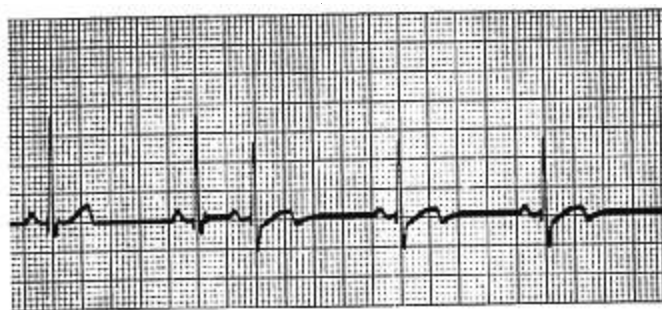


FIG. 1. New and significant S-T segment depression and T-wave configuration change occurring with minor movement of the NDM patient cable: lead wire interface.