

REFERENCES

1. Wray RP: A source of nonanesthetic nitrous oxide in operating room air. *ANESTHESIOLOGY* 52:88-89, 1980
2. Kaarakka P, Malischke PR, Kreul JF: Alternative sites for measuring breathing zone N<sub>2</sub>O levels. *ANESTHESIOLOGY* 55:A139, 1981

(Accepted for publication September 10, 1984.)

Anesthesiology  
62:207, 1985

### Lamp Placement and the Miller I Laryngoscope Blade

*To the Editor:*—In the June 1984 issue of *ANESTHESIOLOGY*, Dr. Diaz described the modifications of the straight Miller blade, suggested to facilitate laryngoscopy.<sup>1</sup> The Miller I blades currently available differ considerably from that originally described and illustrated by Dr. Miller.<sup>2</sup> He recognized the necessity of

placing the lamp close to the distal end of the blade for adequate laryngeal illumination.

I have modified the Welch-Allyn Miller I blade by removing the distal 13 mm of the blade and refashioning the distal end with a slight curve. Figure 1 shows the standard Welch-Allyn and Penlon Miller I blades and the shortened Welch-Allyn version. The modified blade has a working length of 67 mm, compared with the original 80 mm length. On laryngoscopy, the lamp is closer to the larynx, greatly improving illumination. With the manufacturer's models, the pharyngeal and paraepiglottic tissues often prolapse onto the lamp.

For patients up to 6 months of age, the shortened blade has no disadvantages.

R. D. M. JONES  
Director of Anaesthesia  
The Grantham Hospital  
125 Wong Chuk Hang Road  
Aberdeen, Hong Kong

REFERENCES

1. Diaz JH: Further modifications of the Miller blade for difficult pediatric laryngoscopy. *ANESTHESIOLOGY* 60:612-613, 1984
2. Miller RA: A new laryngoscope. *ANESTHESIOLOGY* 2:317-320, 1941

(Accepted for publication September 10, 1984.)

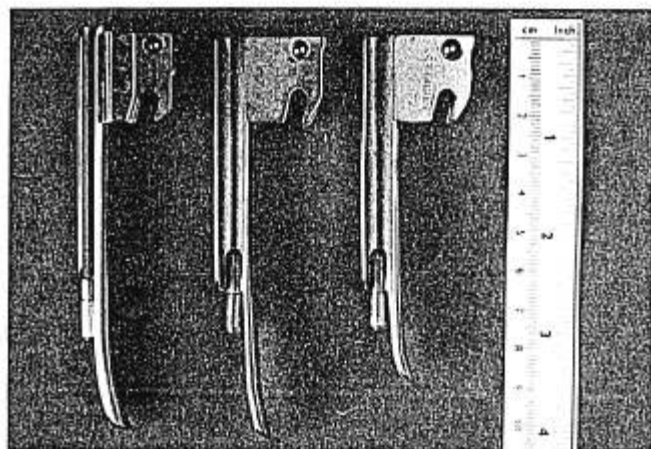


FIG. 1. Left: Standard Penlon Miller I blade. Middle: Standard Welch-Allyn Miller I blade. Right: Shortened Welch-Allyn Miller I blade.

Anesthesiology  
62:207-208, 1985

### A Case of Artifactual S-T Depression

*To the Editor:*—Recently, during a routine cholecystectomy, new and significant S-T segment depression appeared on our Hewlett-Packard® #78304A ECG monitor. This occurred while we monitored lead II (fig. 1). Fortunately, the depression lasted only a few minutes and resolved spontaneously without treatment.

After resolution, we checked all the lead wire attachments; each was well secured. Then, accidentally, we found that minor movement of the patient cable holding the lead wires could produce or terminate the S-T segment changes at will.

The New Dimensions in Medicine (NDM) fully shielded ECG lead wire with snap electrode connector

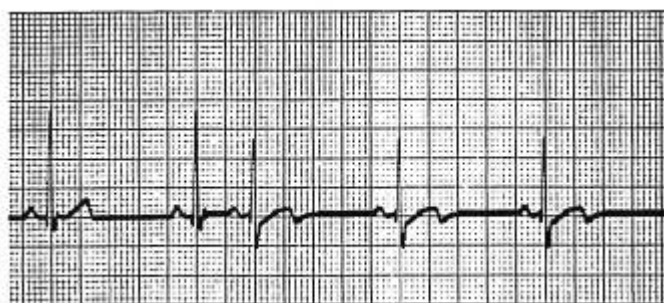

FIG. 1. New and significant S-T segment depression and T-wave configuration change occurring with minor movement of the NDM patient cable: lead wire interface.

and 04 series patient cable is excellent electrical equipment, which has functioned reliably for us over the last 5 years. As a result, we evolved a policy of replacing reusable electrical equipment only when damage was obvious or suspected. In retrospect, the lack of a regular replacement schedule is what enabled a damaged system to simulate intermittent artifactual S-T segment depression.

Since discovering this problem with apparently undamaged lead wires, we have instituted an informal but

regular replacement schedule for NDM lead wires and patient cables. We offer this information in the hope that other departments will benefit from our experience.

AUGUST M. MANTIA, M.D.  
Staff Anesthesiologist  
Western Pennsylvania Hospital  
4800 Friendship Avenue  
Pittsburgh, Pennsylvania 15224

(Accepted for publication September 21, 1984.)

Anesthesiology  
62:208-209, 1985

### An Unusual Source of Leak in the Anesthesia Circuit

*To the Editor:*—Equipment-related complications and hazards are well known to the anesthesiologist.<sup>1</sup> Leaks in the anesthesia machine circuit are common occurrences and usually are discovered during a routine machine checkout.<sup>2,3</sup> Disposable circuits commonly are used and can be the cause of leaks and airway obstruction.<sup>4-6</sup> This report illustrates a previously undescribed serious leak in a disposable anesthesia circuit that could not be detected by routine machine check-out.

#### REPORT OF A CASE

Patient 1, a 16-year-old prima gravida at term underwent emergency cesarean section because of fetal distress. We preoxygenated the patient and induced anesthesia with thiopental and succinylcholine, utilizing a standard rapid-sequence induction. We performed an uneventful laryngoscopy and intubated the trachea with a 7.0-mm endotracheal tube. After inflating the endotracheal tube cuff and

connecting the endotracheal tube to a semiclosed anesthesia circuit, we were unable to ventilate the patient adequately, and there was a significant audible leak. In an attempt to isolate the source of the leak, we independently documented the integrity of the endotracheal tube cuff and the anesthesia circuit. A second attempt at ventilation localized the leak to the plastic elbow of the disposable circuit (fig. 1). We removed the plastic elbow from the circuit and were able to ventilate the patient easily. The infant was delivered with Apgar scores of 7 and 9 at 1 and 5 min, respectively. At the completion of the operation, the patient was extubated awake without problems.

Thorough checkout of the anesthesia machine does not always ensure that leaks significant enough to interfere with ventilation will be detected.<sup>7</sup> In spite of following a standard protocol that includes pressurizing the breathing system to 40 cm H<sub>2</sub>O against a closed relief valve and an occluded patient port,<sup>3</sup> we failed to demonstrate a significant hazard. Figure 1 demonstrates a defect in the inner ring of the elbow of a NARDA® nonconductive disposable anesthesia breathing circuit (N1310DN). This leak can be detected if only the inner ring is occluded during the breathing system checkout. This case emphasizes the importance of inspecting as well as testing all anesthesia equipment prior to use.

RICHARD D. COLAVITA, M.D.  
Clinical Instructor in Anesthesia

JEFFREY L. APFELBAUM, M.D.  
Assistant Professor of Anesthesia

Department of Anesthesia  
University of Pennsylvania  
School of Medicine  
3400 Spruce Street  
Philadelphia, Pennsylvania 19104




FIG. 1. View of the elbow from the NARDA® disposable anesthesia circuit (N1310DN) demonstrating a defect of the inner ring.

#### REFERENCES

1. Spooner RB, Kirby RR: Equipment-related anesthesia incidents. *Int Anesthesiol Clin* 92:133-147, 1984