

REFERENCES

1. Wright RB, Manfield FFV: Damage to teeth during the administration of general anesthesia. *Anesth Analg* 53:405-408, 1974
 2. Evers W, Racz GB, Glazer J, Dobkin AB: Oraisive as a protection for the teeth during general anesthesia and endoscopy. *Can Anaesth Soc J* 14:123-128, 1967
 3. Jephcott A: The Macintosh laryngoscope: A historical note on its clinical and commercial development. *Anaesthesia* 39:474-479, 1984
 4. Skinner EW, Phillips RW: *The Science of Dental Materials. Physical Properties of Dental Materials.* Philadelphia, WB Saunders, 1967, pp 47-50
 5. Cullen SC: Current comment. *ANESTHESIOLOGY* 22:846-848, 1961
- Anesthesiology
62:358-363, 1985

Intrathecal Morphine Tolerance: Use of Intrathecal Clonidine, DADLE, and Intraventricular Morphine

DENNIS W. COOMBS, M.D.,* RICHARD L. SAUNDERS, M.D.,† DANIEL LACHANCE, B.S.,‡
SEDDON SAVAGE, M.D.,§ THORIR S. RAGNARSSON, M.D.,¶ LAWRENCE E. JENSEN, M.S.**

Continuous intrathecal morphine infusion provides a new approach to provide analgesia for the terminally ill patient in pain. Unfortunately, tolerance to morphine given intrathecally may predate death from the tumor. With such tolerance, the pain again can become unbearable unless permanent neurolysis or neuroablative surgery succeeds.¹

One approach to overcoming the tolerance is to "rest" the mu opiate receptors while activating alternate receptor systems known to mediate antinociception. Yaksh *et al.*² demonstrated both adrenergic and serotonergic descending inhibitory systems in the spinal cord. Activation of postsynaptic adrenergic receptors at the spinal level with either the lipophilic alpha agonist clonidine or its more polar analogue ST-91 yields a potent and prolonged antinociception as measured by the shock titration paradigm in monkeys.³ Alternatively, activation of delta opiate receptors in the dorsal horn

produces analgesia in various laboratory models.⁴⁻⁶ A third approach to overcoming tolerance to narcotics given intrathecally is to administer morphine into the cerebral ventricles (ICV). Theoretically, this might increase morphine availability at opiate receptors modulating pain at higher levels of the cerebrospinal axis. Lobato *et al.*⁷ and Leavens *et al.*⁸ reported analgesia in humans with this route of morphine administration.

We report temporary control of cancer pain during chronic intrathecal infusion of clonidine in a patient with metastatic rectal adenocarcinoma, already tolerant to high doses of morphine administered systemically and intrathecally. We also report lack of analgesia following intrathecal administration of the specific delta agonist Da La² D-Leu⁵ enkephalin (DADLE). Additionally, the ineffectiveness of high-dose ICV morphine was noted in this same patient. Finally, 3 months after intrathecal neurolysis, spinal opiate receptor sensitivity to low-dose intrathecal morphine reemerged.

MATERIALS AND CASE REPORT

Drug Delivery System. The drug delivery system consisted of a subcutaneously implanted Infusaid® Model 400 reservoir pump (Infusaid Corp., Norwood, Massachusetts) with a constant flow rate (4 ml per day) connected in series with an L1-2 intrathecal Silastic® catheter. Detailed descriptions of this system are reported elsewhere.⁹ Drug dosages were varied by changing the concentration of the drugs in the pump reservoir. If needed, bolus intrathecal doses were given via the auxiliary port of the reservoir.

Prior to human use, compatibility and stability of clonidine HCl were tested *in vitro* in a reservoir maintained at 37° C in a water bath for 56 days via serial

* Assistant Professor, Department of Surgery (Anes.), Dartmouth-Hitchcock Medical Center.

† Associate Professor, Department of Surgery (Neurosurgery), Dartmouth-Hitchcock Medical Center.

‡ Senior Medical Student, Dartmouth Medical School.

§ Postgraduate Fellow in Pain Management, Department of Surgery (Anes.), Dartmouth-Hitchcock Medical Center.

¶ Resident in Neurosurgery, Department of Surgery, Dartmouth-Hitchcock Medical Center.

** Administrative Research Assistant, Department of Surgery (Anes. Res.), Dartmouth-Hitchcock Medical Center.

Received from the Department of Surgery, Dartmouth-Hitchcock Medical Center, Hanover, New Hampshire 03755. Accepted for publication September 13, 1984. Supported in part by grants from the Kingsbury Fund, Keene, New Hampshire and the NCI, Grant No. CA 33865-01.

Address reprint requests to Dr. Coombs.

Key words: Analgesics, narcotics: morphine, tolerance. Anesthetic techniques: spinal.

measurement of clonidine HCl levels and resultant flow rates (Data on file at Infusaid Corp., Norwood, Massachusetts). Clonidine concentrations were measured by a double isotope radioimmunoassay.¹⁰ Clonidine concentrations were observed to fluctuate less than 12% over the 56 days. Liability of serious neurotoxicity resulting from intraspinal clonidine was precluded by investigations in sheep prior to obtaining an investigational new drug application (IND), Institutional Review Board approval, or initiating clinical studies.†† DADLE was prepared in a saline solution from lyophilized powder (Peninsula Laboratories, Palo Alto, California) and sterilized by passage through a 0.22- μ m filter. Once in solution, the DADLE was brought to the patient's bedside and injected immediately through a 22-gauge lumbar spinal needle. Administration of drugs was performed under a protocol approved by the institutional review board; both patient and daughter gave written and oral informed consent.

This patient had originally met our study criteria for continuous intraspinal morphine infusion via an implantable reservoir device in November 1982.¹¹ Demonstration of tolerance to high-dose intrathecal morphine (15 mg intrathecally daily) was required prior to admission to the bolus intrathecal clonidine study. Significant psychological depression was excluded by clinical examination and a Zung self-rating depression score < 0.65.¹² A minimum acceptable therapeutic response to bolus intrathecal clonidine was required prior to initiation of continuous infusion. Minimal response was defined as at least a 50% reduction from the patient's preclonidine pain report on visual pain analogue scale scores (VPASS),¹³ with the decrease sustained for at least 8 h.

Patient 1. In May 1979, the patient, a 52-year-old obese woman, underwent an abdominal perineal resection of a 2.0 \times 1.5 cm Duke's B1 adenocarcinoma. Postoperative course was complicated by a perineal body abscess and sigmoid colostomy stricture; and eventually constant left-sided sacral pain prevented her return to a desk job. Over the next 2 years, this pain was complicated by perineal body suture granuloma and flares of degenerative joint disease, primarily involving lumbosacral and knee joints. Neurologic evaluation in March 1981 demonstrated a polysegmental postoperative sacral neuropathy. During September 1981, intermittent urinary retention appeared. Evaluation for recurrent disease and bilateral leg and back pain demonstrated a presacral mass that was irradiated with 5,000 rads. Her daily analgesic intake increased to 20 mg po methadone. In February 1982, recurrent pain and sympathetic dystrophy in the extremities led to an additional 2,000 rads of pelvic irradiation and cesium inserts.

In November 1982, the pain was uncontrolled by 80 mg po methadone daily, and an Infusaid Pump[®] was implanted for continuous infusion of intrathecal morphine. Pain control initially was achieved with 2 mg intrathecal morphine per day and prn po acetaminophen and oxycodone. Methadone withdrawal was averted with a 2-week course of oral clonidine.¹⁴ Two subsequent courses of cis-platinum,

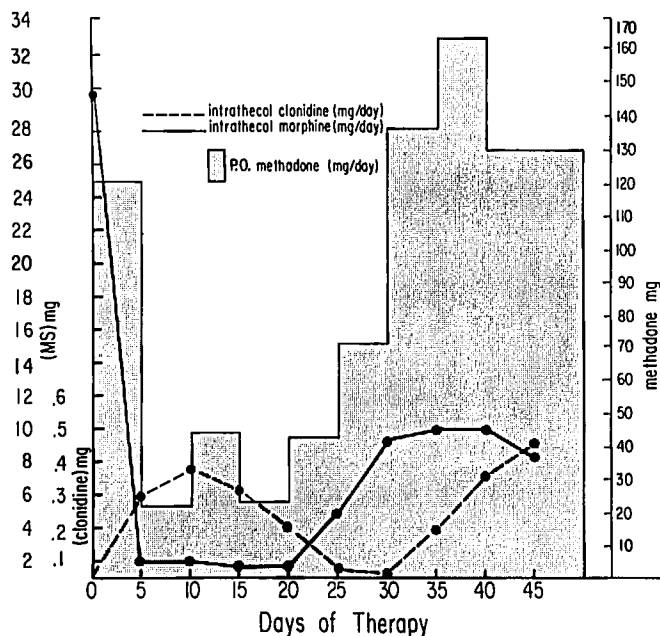


FIG. 1. Combined intrathecal morphine and clonidine infusion over the initial 45-day trial with corresponding po methadone requirements. The corresponding analgesic response is shown in figure 2. The patient's hydromorphone requests were minimal but are graphed as methadone equivalents (7.5 mg po hydromorphone = 20 mg po methadone).

BCNU, and DTIC, with weekly 5-FU had no effect on tumor size. Examination in July 1983 revealed sacral invasion by tumor including the caudal dural sac. Intrathecal morphine doses gradually were increased and methadone reinstated and increased until the combination of 30 mg intrathecal morphine with 120 mg po methadone daily failed to control her pain. She was bedridden and in constant pain for the week prior to readmission.

In late September 1983, the patient was placed on a double-blind protocol for bolus infusion of intrathecal clonidine. A 0.3 mg intrathecal clonidine bolus yielded more than 18 h analgesia, characterized by greater than 50% reduction in pain report (VPAS). In contrast, placebo (2 ml intrathecal normal saline) yielded no pain relief, while a 0.15 mg bolus of clonidine yielded intermediate relief. Side effects included 3–4 h of sedation and transient hypotension to 70 mmHg systolic, easily controlled with iv metaraminol injection. Bradycardia (48 bpm) responded to a single iv dose of 0.2 mg atropine. Thus, a trial of combined intrathecal infusion of 0.3 mg/day clonidine with 2 mg/day morphine was instituted. This was supplemented with a reduced po methadone maintenance schedule of 10 mg/day and by 2 mg po hydromorphone prn. Intrathecal and po analgesic use during this trial is shown in figure 1, while the resultant analgesia as measured by mean daily visual pain analogue scores during the 45 days on this regimen is shown in figure 2. On this regimen she again was able to ambulate. Despite good analgesia, orthostatic hypotension (systolic blood pressure 76–98 mmHg) unresponsive to ergonovine,¹⁵ fludrocortisone, and po ephedrine led us to taper the clonidine dose by day 27 (intrathecal clonidine was discontinued for two days). A concomitant escalation of narcotic requirement occurred. Pelvic computed axial tomography (CAT) scan revealed further marked increase in pelvic tumor size with intraspinal tumor extending to L3. Reinstitution on day 30 of 0.2 mg/day intrathecal clonidine infusion failed to control pain, but

†† Coombs DW, Allen C, Meier FA, Fratkin JD: Chronic intraspinal clonidine in sheep. *Regional Anesthesia* 9:47–48, 1984.

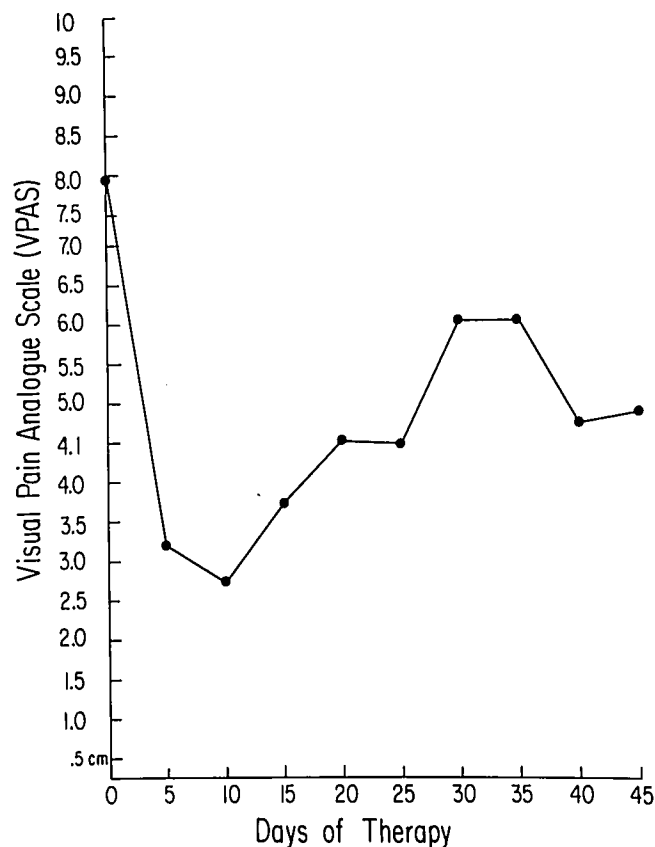


FIG. 2. Mean daily visual pain analogue scores reported by the patient during a 45-day trial of intrathecal morphine and clonidine. Note baseline report of 8 cm was obtained during the 2 days before initiation of the trial. Concomitant analgesic dosages are shown in figure 1.

upward manipulation of intrathecal clonidine to 0.6 mg/day and morphine 10 mg/day reestablished analgesia. At day 45, with pain controlled, the patient was discharged home on this clonidine-morphine regimen. However, after only 2 weeks, she was readmitted for low back and leg pain uncontrolled by daily intrathecal infusion of 0.5 mg clonidine and 40 mg morphine. Increase of intrathecal morphine to 75 mg/day was to no avail.

Intrathecal bupivacaine infusion was begun in an attempt to control the pain. Permanent neurolytic block was considered, but the patient refused. On day 12 of therapy, the bupivacaine infusion was interrupted, and bolus intrathecal DADLE was given incrementally over 1 h to a total of 2.25 mg, but no analgesia was obtained. Twelve hours later, a right ventriculostomy was performed, and ICV morphine was administered incrementally over 1 h to a total of 17.5 mg. Intraventricular morphine produced no sedation, respiratory depression, or analgesia. The only consequence was a brief 2-min period of mild retching. The patient consented to neurolysis the following day. A 4-ml 7% phenol in glycerine intrathecal block was injected at T10-11 in the prone position, and satisfactory analgesia was obtained. Intrathecal phenol block was repeated 1 month later, due to recurrence of pain. Two months later, with recurrence of pain, reinstatement of intrathecal morphine (2 mg/day) via the auxiliary pump port again yielded pain relief for 8-12 h. In February 1984, the silastic catheter was disconnected from the pump and exteriorized to facilitate home use. From February until May, pain control was maintained at

home with alternating doses of intrathecal bupivacaine (0.25%) 1-3 ml and 2 mg intrathecal morphine. The only side effect was 10 min intermittent burning discomfort following intrathecal injections, suggesting arachnoiditis development. Notably, this percutaneous intrathecal catheter was in continuous use for all but the final 3 weeks of life, when it became obstructed. During this latter period, terminal care was facilitated by combinations of phenothiazines and sedatives until her death from inanition.

DISCUSSION

Intrathecal morphine substantially enhances the analgesic effect of systemic opiates.^{16,17} The magnitude of this effect suggests a multiplicative interaction between the spinal and supraspinal opiate receptor systems.¹⁸ However, as with tolerance in the centrally mediated opiate system, tolerance also develops in the spinal system.^{19,20} In terms of cancer pain control, intraspinal morphine is a useful adjunct with obvious limitations once increasingly high doses are ineffective.^{19,20}

Intrathecal morphine initially produces analgesia characterized by tachyphylaxis via its action primarily upon spinal mu receptors. However, at least two spinal opiate receptor populations, so-called mu and delta receptors, are believed to modulate nociceptive pain transmission in the dorsal horn via specific receptor agonists.⁵ Thus, at least two possible ways exist to circumvent the limitation imposed by spinal narcotic tolerance. Both attempt to put the mu receptors to "rest." In the first case, analgesia is provided by intermittent or continuous regional anesthesia until the opiate receptors recover opiate sensitivity.^{21,22} Yaksh observed recovery in opiate-tolerant animals with 2 weeks opiate abstinence.²³ Logistically, this method requires long periods of hospitalization with close monitoring and, in our experience, does not assure complete recovery of the mu receptor-mediated analgesia. Secondly, analgesia could be achieved through stimulation of an alternate nontolerant spinal receptor population subserving antinociception.

Yaksh and Reddy successfully have demonstrated the intrathecal antinociceptive potential of the alpha agonist clonidine in macaque monkeys.² Convincing evidence exists that this effect is mediated through a post-synaptic receptor of a descending inhibitory adrenergic neuron^{2,24-27} with synapses in the dorsal horn. In contrast to morphine, clonidine analgesia is only mediated spinally,²⁸ since it is not influenced by high thoracic spinal cord transection. This clonidine mediated analgesia may be achieved best by intraspinal administration, since at brain stem levels the net effect of such alpha₂ agonists may be analgetic.^{17,26,28,29}

In this patient we observed a marked analgesic effect during initial intrathecal clonidine infusion documented by decreased pain reports and increased mobility, despite a marked reduction in oral narcotic use and a tenfold

reduction in intrathecal morphine use (fig. 1). Analgesia and decreased narcotic use were sustained until clonidine was tapered. During intrathecal clonidine reinitiation, however, analgesia was not obtained at the previously effective morphine and clonidine doses. This may represent adrenergic-opiate cross tolerance. However, differentiation between narcotic tolerance and increasing pain from tumor progression was difficult, in part because substantially higher concentrations of an intrathecal clonidine preparation were not available for use. Alternative explanations for failure of the previously effective clonidine-morphine combination exist. Higher doses of analgesics often are needed to overcome pain that is out of control. Also, abandonment of clonidine may have induced a psychologic "setback." The earlier increased mobility of the patient may have increased painful afferent input. Narcotic withdrawal is an unlikely explanation, since no classic symptoms were observed and both methadone and intrathecal morphine later were stopped acutely following neurolysis without withdrawal symptoms.

Speculatively, this patient might have benefited from higher concentrations of intrathecal clonidine. Yaksh *et al.*, using shock titration in monkeys tolerant to intrathecal morphine injections, observed no waning in analgesia with a daily intrathecal bolus of both clonidine and morphine through 21 days of study.³ In contrast, Paalzow noted that rats made tolerant to intrathecal clonidine demonstrated no analgesic response to intrathecal morphine.³⁰ From this it is logical to conclude that the spinal alpha receptors are "downstream" from the opiate receptor; further, a similar biochemical common denominator effectively must yield tolerance to agonists of both receptors, if tolerance to the alpha agonist exists. We had hoped that intrathecal clonidine might allow the mu receptors to "rest" long enough to recover sensitivity to low-dose intrathecal morphine. Though a substantial reduction in oral and intrathecal narcotic was accomplished temporarily, complete opiate abstinence was not achieved, while subsequent narcotic escalation was rapid. To truly test this hypothesis in future studies, intrathecal morphine will have to be halted prior to intrathecal clonidine initiation.

During studies of bolus clonidine infusion in our patient, hypotension and bradycardia were pronounced and required alpha-adrenergic and chronotropic support. During infusion of lower daily doses (0.3–0.4 mg/day) of the drug, resting bradycardia and hypotension were noted but were absent in the higher dose range (0.4–0.6 mg/day). This hypotension is consistent with the observations of Yasuoka and Yaksh in cats given bolus intrathecal clonidine.³¹ Stable blood pressure at higher infusion rates perhaps results from peripheral alpha receptor effects of clonidine, a partial agonist at both

presynaptic and postsynaptic alpha receptors. At higher intrathecal doses increasing concentrations of clonidine may gain access to the systemic circulation, with vasoconstriction predominating over presynaptic adrenergic effects³²; a similar phenomenon was observed by one of the authors (DWC) during chronic intraspinal clonidine infusions in sheep.‡‡

An alternative to adrenergic receptor mediated antinociception in the spinal cord is delta opiate receptor mediated analgesia. Several authors have reported lack of cross-tolerance between spinal mu and delta opiate receptors, suggesting each receptor system, in the presence of specific agonists, might exert an independent analgesic effect.^{3–5} Therefore, we gave intrathecal DADLE, a specific delta agonist, at a dose exceeding that shown to be analgesic in both animals and humans.^{3,5,33} We observed no analgesia. One explanation for this finding is partial receptor cross-tolerance between DADLE and morphine. Teng has shown that rats tolerant to intrathecal morphine (tail-flick latency test) demonstrate no cross-tolerance with intrathecal DADLE.³⁴ However, rats tolerant to intrathecal DADLE are also tolerant to intrathecal morphine.³⁵ Therefore, DADLE also must activate the mu receptor. In our patient the degree and duration of mu receptor activation by morphine was of a greater magnitude than in these animal models. Further, the patient also had received intrathecal clonidine. Unfortunately, absence of analgesia with intrathecal DADLE in the setting of advanced tolerance to intrathecal morphine and concomitant clonidine suggests that exposure to clonidine may render both DADLE and morphine ineffective as spinal analgesics. The clinical utility of chronically alternating mu, delta, and adrenergic spinal receptor agonists thus becomes suspect. An alternative explanation for lack of analgesia, namely, that DADLE did not gain access to the delta receptor population in the spinal cord, seems unlikely given the period of observation.

Lobato *et al.*⁷ have advocated ICV narcotic administration as a means of overcoming po and intrathecal narcotic tolerance. In their series of patients, 0.5–2 mg ICV morphine, given up to once every 3 h, provided marked analgesia. The bolus dosage of intraventricular morphine administered to our patient exceeded the highest daily ICV morphine dose (16 mg) in the Lobato *et al.*⁷ series. We noted no observable analgesia, respiratory suppression, sedation, or seizure activity. Lobato *et al.* did not define prior narcotic use in their report; thus, it is tempting to conclude that marked opiate tolerance did not exist in their patients. The same is

‡‡ Coombs DW, Allen C, Meier FA, Fratkin JD: Chronic intraspinal clonidine in sheep. *Regional Anesthesia* 9:47–48, 1984.

likely true of the successful results in the series reported by Leavens *et al.*⁸ The tolerance observed in our patient perhaps approaches record levels; presumably, to achieve similar CSF morphine concentrations to that resulting during delivery of 75 mg/day intrathecal morphine and 17.5 mg ICV morphine truly would require astronomical parenteral morphine doses. Under conditions in which both high-dose methadone and intrathecal morphine have been administered, intuitively, a point must be reached when no multiplicative interaction can be obtained between spinal and supraspinal opiate receptors.¹⁷

There is a natural reluctance to use percutaneously exposed intrathecal catheters for fear of infection. In dealing with pain control in terminal phases of malignancy, however, the hazard of meningitis may be of less importance than the expense and inconvenience of implanted systems. Under such circumstances, a chronic lumbar CSF drain may offer a better conduit for analgesic delivery, even when local anesthetic delivery is to be part of the plan. Though the limits of such an approach are unknown, perhaps this route should be considered more frequently for terminal therapy of short or intermediate duration.

In summary, in this complex case we observed continuous intrathecal clonidine infusion to yield temporary pain control, despite advanced opiate tolerance. Limited availability of clonidine led to a trial of both intrathecal DADLE and high-dose ICV morphine; both failed to decrease pain. Following temporary pain control with intrathecal neurolytics (3 months), responsiveness to intrathecal morphine returned. This case suggests that cross-tolerance exists between spinal opiate and adrenergic systems after chronic exposure. Further study of intraspinal delta and alpha-adrenergic agonists as pain relievers are underway to define their analgesic role in this and other settings.

The authors thank Penelope Bowers, M.D., of Boehringer Ingelheim, Ltd., Ridgefield, Connecticut, for her support and supply of clonidine HCl (0.6 mg/ml in saline) through Investigational New Drug application (IND) No. 22,207. DaLa² D-Leu⁵ Enkephalin was a generous gift from Tony Yaksh, Department of Neurosurgery, Mayo Clinic. The authors also thank J. Kresel and E. Rippe of the Pharmacy Department, Dartmouth-Hitchcock Medical Center, for meticulous preparation of the agents used; Patricia Russell, M.D., of the FDA for her counsel and advice; L. H. Maurer M.D., Department of Oncology, Dartmouth-Hitchcock Medical Center; and M. Kamp for manuscript assistance.

REFERENCES

1. Bonica JJ: Cancer pain, Pain. Edited by Bonica JJ. New York, Raven Press, 1980, pp 335-363
2. Reddy SVR, Yaksh TL: Spinal noradrenergic terminal system mediates antinociception. *Brain Res* 189:391-401, 1980
3. Yaksh TL, Reddy SVR: Studies in the primate on the analgetic effects associated with intrathecal actions of opiates, adrenergic agonists and Baclofen. *ANESTHESIOLOGY* 54:451-467, 1981
4. Hynes MD, Frederickson RCA: Cross-tolerance studies distinguish morphine- and metkephamid-induced analgesia. *Life Sci* 31: 1201-1204, 1982
5. Yaksh TL: In vivo studies on spinal opiate receptor systems mediating antinociception. I Mu and Delta receptor profiles in the primate. *J Pharm Ex Ther* 226:303-316, 1983
6. Tung AS, Yaksh TL: In vivo evidence for multiple opiate receptors mediating analgesia in the rat spinal cord. *Brain Res* 247:75-83, 1982
7. Lobato R, Madrid J, Patel AL, Rivas J, Reig E, Lamas E: Intraventricular morphine for control of pain in terminal cancer patients. *J Neurosurg* 59:627-633, 1983
8. Leavens ME, Stratton Hill C, Cech DA, Weyland JB, Weston JS: Intrathecal and intraventricular morphine for pain in cancer patients: initial study. *J Neurosurg* 56:241-245, 1982
9. Coombs DW, Saunders RL, Gaylor MS, Pageau MG: Epidural narcotic infusion reservoir: implantation technique and efficacy. *ANESTHESIOLOGY* 56:469-473, 1982
10. Arndts D, Stahle H, Forster HJ: Development of an RIA for clonidine and its comparison with the reference methods. *J Pharmacol Methods* 6:295-307, 1981
11. Coombs DW, Saunders RL, Gaylor MS, Block A, Colton T, Harbaugh R, Pageau MG, Mroz W: Relief of continuous chronic pain by intraspinal narcotic infusion via an implanted reservoir. *JAMA* 250:2336-2339, 1983
12. Zung W: A self-rating depression scale. *Arch Gen Psychiatry* 12:63-70, 1965
13. Scott J, Huskisson EC: Graphic representation of pain. *Pain* 2:175-184, 1976
14. Gold MS, Pottash AC, Sweeney DR, Kleber HD: Opiate withdrawal using clonidine: A safe, effective, and rapid non-opiate treatment. *JAMA* 243:343-346, 1980
15. Castenfors J, Lindblad LE, Mortasaiwi A: Effect of dihydroergotamine on peripheral circulation during epidural anesthesia in man. *Acta Anesth Scand* 19:79-84, 1975
16. Hanaoka K, Ohtani M, Toyooka H, Dohi S, Ghazisaidi K, Taub A, Kitahata LM: The relative contribution of direct and supraspinal descending effects upon spinal mechanisms of morphine analgesia. *J Pharm Exp Ther* 207:476-484, 1978
17. Yaksh TL: Spinal opiate analgesia: Characteristics and principles of action. *Pain* 2:293-346, 1981
18. Yeung JC, Rudy TA: Multiplicative interaction between narcotic agonists expressed at spinal and supraspinal sites of antinociceptive action as revealed by concurrent intrathecal and intracerebroventricular injections of morphine. *J Pharm Exp Ther* 215:633-642, 1980
19. Woods WA, Cohen SC: High dose epidural morphine in a terminally ill patient. *ANESTHESIOLOGY* 56:311-312, 1982
20. Greenberg HS, Taren J, Ensminger WD, Doan K: Benefit from and tolerance to continuous intrathecal infusion of morphine for intractable cancer pain. *J Neurosurg* 57:360-364, 1982
21. Coombs DW: Mechanism of epidural lidocaine reversal of tachyphylaxis to epidural morphine analgesia. *ANESTHESIOLOGY* 59:486-487, 1983
22. Coombs DW, Pageau MG, Saunders RL, Mroz WT: Intraspinal narcotic tolerance: Preliminary experience with continuous bupivacaine HCl infusion via implanted infusion device. *Int J Art Organs* 5:379-382, 1982
23. Yaksh TL: Multiple spinal opiate receptor systems in analgesia, *Advances in Pain Research and Therapy*, vol 6. Edited by Kruger L, Liebeskind JC. New York, Raven Press, 1984, pp 197-215
24. Spaulding TC, Fielding S, Venafro JJ, Lal H: Antinociceptive activity of clonidine and its potentiation of morphine analgesia. *Eur J Pharmacol* 58:19-25, 1979

25. Zemlan FP, Corrigan SA, Pfaff DW: Noradrenergic and serotonergic mediation of spinal analgesia mechanisms. *Eur J Pharmacol* 61:111-124, 1980
26. Reddy SVR, Maderdrut JL, Yaksh TL: Spinal cord pharmacology of adrenergic agonist-mediated antinociception. *J Pharm Exp Ther* 213:525-533, 1980
27. Fielding S, Spaulding T, Lal H: Antinociceptive action of clonidine. *Psychopharmacology of Clonidine*. New York, Alan R Liss, 1981, pp 225-242
28. Spaulding TC, Venafro JJ, Ma MG, Fielding S: The dissociation of the antinociceptive effect of clonidine from supraspinal structures. *Neuropharmacology* 18:103-105, 1979
29. Timmermans P, Brands A, Van Zweiten PA: Lipophilicity and brain disposition of clonidine and structurally related imidazolines. *Arch Pharm* 300:217-226, 1977
30. Paalzow G: Development of tolerance to the analgesic effect of clonidine in rats cross-tolerant to morphine. *Arch Pharm* 304:1-4, 1978
31. Yasuoka S, Yaksh TL: Effects on nociceptive threshold and blood pressure of intrathecally administered morphine and alpha-adrenergic agonists. *Neuropharmacology* 22:309-315, 1983
32. Kiowski W, Hulthen UL, Ritz R, Buhler FR: Alpha₂ adrenoceptor-mediated vasoconstriction of arteries. *Clin Pharm Ther* 34:565-569, 1983
33. Onofrio BM, Yaksh TL: Intrathecal delta-receptor ligand produces analgesia in man. *Lancet* 1:1386-1387, 1983
34. Teng LF: Partial cross tolerance to D-ala²-D-Leu⁵ Enkephalin after chronic spinal morphine infusion. *Life Sci* 32:2545-2550, 1983
35. Teng LF: Tolerance and cross tolerance to morphine after chronic spinal D-ala²-D-Leu⁵ Enkephalin infusion. *Life Sci* 31:987-992, 1982

Anesthesiology
62:363-365, 1985

Extracorporeal Circulation in a Patient with Heparin-induced Thrombocytopenia

JILL PALMER SMITH, M.D.,* JOSEPH T. WALLS, M.D.,† MARY S. MUSCATO, M.D.,‡
E. SCOTT MCCORD, M.D.,§ EUGENE R. WORTH, M.D.,¶ JACK J. CURTIS, M.D.,† DONALD SILVER, M.D.**

Heparin-induced thrombocytopenia may occur after two to 15 days of heparin therapy. It has been reported after iv and subcutaneous administration with various heparin preparations and is not dose dependent. Effective management requires cessation of heparin therapy, administration of platelet antiaggregating drugs, and, when indicated, the use of another form of anticoagulation. When patients with heparin-induced thrombocytopenia are rechallenged with heparin within 12 months of the initial event, recurrent thrombocytopenia and/or thrombosis may occur.¹⁻³ Alternatively, reinstatement of heparin therapy within 4 months after the initial event has been performed without a decrease in platelets.³ We report a patient with heparin-induced thrombocy-

topenia, documented by aggregation testing,⁴ who required myocardial revascularization. The patient received heparin during coronary artery bypass 14 days after the initial thrombocytopenia had resolved and while aggregation tests indicated the persistence of a heparin-induced antiplatelet antibody.

REPORT OF A CASE

A 57-year-old man was referred for evaluation of unstable angina pectoris. On admission he was given beta-adrenergic receptor blockers, calcium channel blockers, nitrates, and prophylactic subcutaneous beef lung heparin (Upjohn) 5,000 units every 8 h. Platelet count on admission was 300,000/mm³. Prothrombin time and partial thromboplastin time were normal, and there was no splenomegaly. On the fourth hospital day, cardiac catheterization documented severe triple-vessel coronary artery disease. Subcutaneous heparin therapy was continued.

On the eighth hospital day, an acute inferior myocardial infarction was documented, intraaortic balloon pump (IABP) assist was begun, and a temporary transvenous pacemaker inserted to manage an associated atrioventricular conduction abnormality. Heparin anticoagulation was increased with beef lung heparin (Upjohn), 7,600 units iv, followed by a continuous iv infusion of 600 units of heparin per hour. The infusion rate subsequently was increased to 1,000 units per hour due to inadequate anticoagulation. A platelet count 6.5 h after starting iv heparin was 56,000/mm³, and heparin was discontinued. Warfarin then was used for anticoagulation. The platelet count decreased to 32,000/mm³ 14 h after the heparin was discontinued. During this time the fibrinogen was 404 mg/dl, and fibrin degradation products were increased at 50 units. Platelet aggregation testing was positive with both beef and porcine heparin. Heparin was deleted from all solutions used to irrigate vascular cannuli.

* Chief Resident-Instructor in Medicine.

† Assistant Professor of Surgery.

‡ Assistant Professor of Medicine.

§ Associate Professor of Anesthesiology.

¶ Resident in Anesthesiology.

** Professor of Surgery.

Received from the Department of Medicine, Division of Cardiothoracic Surgery, Department of Anesthesiology and the Department of Surgery of the University of Missouri-Columbia, Columbia, Missouri. Accepted for publication September 13, 1984.

Address reprint requests to Dr. Walls: Cardiothoracic Surgery, N507A University of Missouri-Columbia Hospital and Clinics, Columbia, Missouri 65212.

Key words: Blood; anticoagulants, heparin, coagulation. Surgery; cardiac.