

use of nalbuphine as analgesic component of minor and major surgery.\*

However, the situation in the case of partial agonist opioids is complicated by what we take to be kappa-receptor-mediated effects, sedation and amnesia. In the case of pentazocine and nalbuphine, these effects readily are seen to be still increasing as the dosage is increased beyond that causing maximum mu-receptor-mediated respiratory depression (and analgesia?). We have provided anaesthesia in unconscious, spontaneously breathing patients for surgery such as vaginal repair or herniotomy, using pentazocine 3 mg/kg (not to be recommended). Many of our patients who used very large doses of nalbuphine, attempting to treat severe postoperative pain, were unsuccessful, judged by the linear analogue pain scores recorded but spent most of their time sleeping and had no subsequent memory of the period.

It seems obvious that kappa-mediated effects do not necessarily have the same dose-response relationship as mu-mediated effects, and this makes the assessment of analgesia even more complicated. Martin<sup>3</sup> suggests that kappa effects in dogs include "spinal analgesia" along with "sedation and anaesthesia." Such analgesia is not readily apparent in humans, but does kappa-induced narcosis count as analgesia? The question also arises as to the contribution that kappa-induced "anaesthesia"

could make to volatile anaesthetic anaesthesia. MAC is a measurement of only one element of such anaesthesia; perhaps we must develop other methods of assessing narcotic or other elements.

So far as narcotic analgesic agonists are concerned, there is also evidence to support the importance of what may be kappa-receptor-mediated effects. Most anaesthetists who have used opiate "anaesthesia" are aware that patients so treated may be completely analgesic (surely a ceiling effect) but aware and that far greater doses of opiate may be required to ensure unconsciousness, presumably through a less-potent kappa-receptor effect.

DR. B. KAY

Reader in Anaesthesia  
Department of Anaesthesia  
University Hospital of South Manchester  
Withington  
Manchester M20 8LR  
England

#### REFERENCES

1. Eisele JH, Steffey EP: Narcotic analgesia—ceiling effect. *ANESTHESIOLOGY* 60:392, 1984
2. Kay B: On-demand nalbuphine for post operative pain. *Der Anaesthetist* 32(Suppl):366-367, 1983
3. Martin WR: History and development of mixed opioid agonists, partial agonists and antagonists. *Br J Clin Pharmacol* 7:2735-2795, 1975

(Accepted for publication October 12, 1984.)

\* Kay B: Balanced anaesthesia with nalbuphine, Eighth World Congress of Anaesthesiologists, Volume II. Edited by Egay LM, dela Cruz-Odi M. Manila, Philippines, January 22-27, 1984, p A337

### High Oxygen Saturation Does Not Always Indicate Arterial Placement of Catheter during Internal Jugular Venous Cannulation

*To the Editor:*—Catheterization of an internal jugular vein may be complicated by arterial puncture. Such an occurrence may be recognized by observing the force and color of blood flow. More reliable information can be obtained by connecting the catheter directly to a transducer and displaying the typical venous waveform and pressure. Measurement of oxygen content of blood obtained from the catheter should confirm the site of placement.<sup>1</sup> Failure to recognize this event and use of the Seldinger technique may lead to the placement of a large bore cannula in the artery with potentially lethal consequences.<sup>2</sup> We experienced an instance of abnormally high oxygen saturation, compatible with arterial blood, in a sample obtained from a central venous

catheter. A 30-year-old man with end-stage renal disease secondary to insulin-dependent diabetes mellitus underwent kidney transplantation. After induction of anaesthesia, the right internal jugular vein first was located with a 23-Ga exploring needle and then catheterized with an 18-Ga catheter. A syringe connected to a 20-inch extension tube was attached to the catheter, and a column of blood was freely aspirated. On disconnection of the syringe, the tube behaved as a manometer, and free fall of the column of blood was noted. This indicated venous placement of the catheter. The 18-Ga catheter then was exchanged using the Seldinger technique for an 8.5-Ga sheath. A triple-lumen catheter was advanced to a distance of 20 cm through the sheath. During the

intraoperative period, a sample of blood was drawn from the distal port of the triple lumen catheter for measurement of blood glucose. The sample was noted to be bright red in color, and blood-gas analysis revealed a  $P_{O_2}$  of 62 mmHg and an oxygen saturation of 92%, with an  $FI_{O_2}$  of 0.4. A simultaneously drawn venous blood sample from a left antecubital vein had a  $P_{O_2}$  of 49 mmHg and an oxygen saturation of 81%. Concern arose over the possibility that the cannulation of an artery had indeed occurred and that the typical venous pressure wave form obtained from the catheter was perhaps due to a resulting damage to the artery.

We believe this unexpected observation can be explained by the presence of the arteriovenous shunt in the patient's right forearm for his regular hemodialysis therapy. This shunt delivered arterial blood via the axillary and subclavian veins into the superior vena cava distal to the tip of the multilumen catheter, leading to high oxygen saturation of central venous blood. Radiographic study obtained postoperatively confirmed the location of the catheter tip at the junction of the superior vena cava and the right atrium.

In conclusion, the presence of an ipsilateral arteriovenous fistula in a patient receiving regular hemodialysis therapy may result in arterialization of blood obtained from a jugular venous catheter and give rise to concern over possible arterial placement of the catheter.

ALIASGHAR AGHDAMI, M.D.  
*Associate Professor*

ROBERT ELLIS, M.D.  
*Assistant Professor*

*Medical College of Virginia  
Richmond, Virginia 23298*

#### REFERENCES

1. Jobs DR, Schwartz AJ, Greenhow DE, Stephenson LW, Ellison N: Safer jugular vein cannulation: Recognition of arterial puncture and preferential use of the external jugular route. *ANESTHESIOLOGY* 59:353-355, 1983
2. Morgan RNW, Morrell DF: Internal jugular catheterization: A review of a potentially lethal hazard. *Anaesthesia* 36:512-517, 1981

*(Accepted for publication October 12, 1984.)*

Anesthesiology  
62:373-374, 1985

### Securing the Epidural Catheter

*To the Editor:*—The epidural catheter typically is secured to the back with sterile gauze and adhesive tape.<sup>1</sup> Epidural catheter dislodgment, migration, and kinking continue to be management problems.<sup>2</sup> The Tegaderm® (3M) dressing is a clear, sterile gas-permeable

dressing widely used at our institution to secure intravenous and arterial catheters in a sterile field, providing a barrier to infection. Recently, we have extended this practice to our obstetrics service. Rather than coiling epidural catheters under sterile gauze, we place a Tegaderm® dressing over a single loop of catheter and secure it in the customary fashion (fig. 1). To our knowledge, this practice has not been described in the literature. We feel that this practice provides better anchorage, allows direct inspection, and facilitates repositioning of the malpositioned catheter. Further, we feel that this technique may decrease the incidence of dislodged or migrated catheters.

MARTIN BROWN, M.D.  
*Senior Resident*

PAUL REIN, D.O.  
*Assistant Professor and Director of Obstetrical Anesthesia*  
*Department of Anesthesiology  
Medical College of Virginia  
MCV Station Box 695  
Richmond, Virginia 23298*

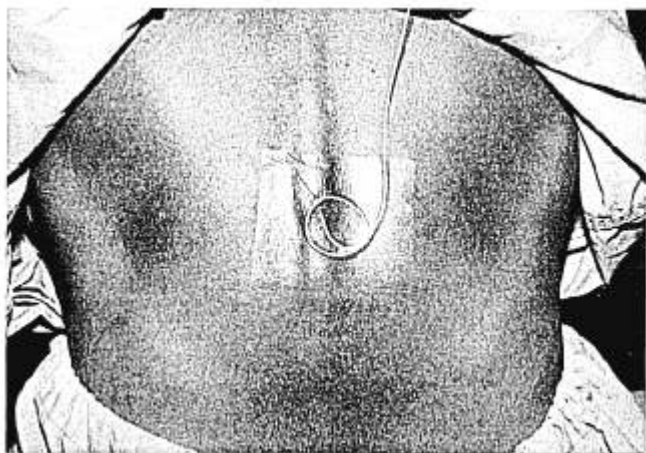


FIG. 1. Tegaderm® dressing covering epidural catheter.