

Aspiration of a Nasal Airway: A Case Report and Principles of Management

JAMES D. HAYES, M.D.,* AND JOHN D. LOCKREM, M.D.†

Nasal airways frequently are used in patients postoperatively and in those needing vigorous pharyngeal suctioning but who do not need tracheotomy or oro/nasotracheal intubation. We describe a disoriented patient who aspirated a nasal airway that relies on an adjustable flange to prevent dislodgement into the patient.

REPORT OF A CASE

A 74-year-old man, 6 days after an abdominal aortic aneurysm repair, was in the intensive care unit recuperating from surgery. The trachea was extubated on the first postoperative day, but vigorous suctioning was required to keep his upper airways clear and to stimulate coughing. The patient had a 28F Rusch® Nasal Airway placed in his right nostril to minimize the trauma of suctioning and to maintain upper airway patency. The adjustable flange was present on the airway when placed, and a comfortable fit was noted but the tube was not secured in any other way.

Immediately after insertion of the airway, it was used to aspirate secretions from the pharynx. Minutes later, his nurse noticed that the airway was missing and that the patient was coughing intermittently but had no gagging or paroxysms of cough. The patient was fully awake but disoriented. In the previous 12 h the patient had received no analgesics, sedatives, or psychotropic medications.

Physical examination revealed no trauma to the nose or oropharynx. The patient's voice was reported as slightly weaker than normal. With the patient in the right lateral decubitus position, lung sounds were normal on the right but diminished on the left. With the patient on his left side, lung sounds were normal on the left but diminished on the right. With the patient supine, the breath sounds were equal bilaterally and not diminished. Arterial blood gases taken at the time of examination revealed: pH_a 7.41; Pa_{O_2} —69.5 mmHg; Pa_{CO_2} —39.5 mmHg; HCO_3^- —24 mEq/l, while breathing 4 l of O_2 by mask. Earlier the same day, pH was 7.49; Pa_{O_2} —62 mmHg; Pa_{CO_2} —33 mmHg; HCO_3^- —24 mEq/l, while breathing 4 l O_2 by mask.

During laryngoscopy the vocal cords and supraglottic structures appeared to be normal. No tube could be seen below the open vocal cords. An anterior-posterior portable chest roentgenogram revealed a very faint shadow in the tracheal lumen, extending from approximately 4 cm below the glottis to just above the carina. Lateral neck films revealed a faint shadow in the tracheal air column, with the top of the shadow again approximately 4 cm below the glottis.

The patient was taken to the operating room, where anesthesia was induced both by the iv and inhalation routes. Laryngoscopy revealed normal vocal cords. A rigid bronchoscope was introduced through the operating laryngoscope and revealed a 28F Rusch® Nasal Airway midline in the trachea approximately 4 cm below the cords. Cup forceps were applied to the airway through the bronchoscope, and the airway and bronchoscope were removed as a unit. Bronchoscopy was immediately repeated, and no injury was noted to the vocal cords, trachea, or carina. The trachea was intubated, and subsequent esophagoscopy revealed no injury or foreign bodies.

The removed nasal airway (fig. 1) did not have the movable flange on it, and the flange was not found on the second bronchoscopy or the esophagoscopy. Repeat chest roentgenogram did not reveal any unusual shadows, and the patient's stools were examined for 5 days without yielding the flange.

The patient awakened from anesthesia and made an uneventful recovery. At the time of discharge, the patient's voice was reported as nearly normal, his gag reflex was normal, and he could produce a brisk cough.

DISCUSSION

Nasotracheal suction is useful in raising secretions from patients unable to clear their tracheobronchial secretions. This technique stimulates coughing and places the suction catheter in an optimum position to remove pharyngeal secretions before they can be inhaled or cause obstruction. The soft, red rubber catheter has been a major advance in minimizing trauma to the nasal mucosa and nasopharynx by providing a conduit to pass the catheter to the point of maximum utility without contact with the nasal mucosa. This maximizes patient comfort and provides the deepest suctioning available in the nonintubated patient. Wanner *et al.*,¹ observed that the suction catheter easily could be advanced through the vocal cords on 34 of 41 attempts in 10 different subjects.

This case report illustrates two features of nasal airways. First, certain models of nasal airways are equipped with moveable flanges that can be adjusted to provide the proper length to maintain the airway tip just above the supraglottic structures in any size patient. It may not be appreciated by many that the flange is not secured to the airway. This allows for the airway to be swallowed or, as in this unusual case, to be aspirated. Howat² reported a similar case of a disposable airway, with a too narrow flange being removed from a patient's nasopharynx after being missed for 5 days.

Secondly, any device placed in the upper airway could

* Resident, Otolaryngology.

† Staff Physician, Department of Anesthesiology.

Received from the Departments of Anesthesiology and Otolaryngology, Cleveland Clinic Foundation, 6500 Euclid Avenue, Cleveland, Ohio 44106. Accepted for publication October 29, 1984.

Address reprint requests to Dr. Hayes.

Key words: Airway; obstruction. Equipment: airway, artificial.

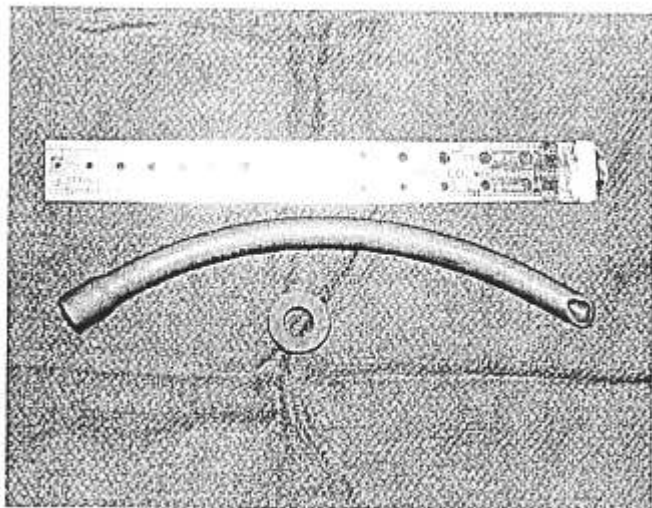


FIG. 1. Rusch® Nasal Airway with flange removed.

be aspirated, and the patient's life may depend on the shape or available lumen of the equipment and the positioning of the patient. It was fortuitous that the tube did not permanently enter one of the main bronchi, producing occlusion of the other.

In selecting equipment for use in patients unable to guard their airways, thought must be given to the dangers of aspiration. Other brands of nasopharyngeal airways have permanent flanges that cannot be removed making aspiration, swallowing, or impaction of the airway into the nose or nasopharynx much more difficult. Also, a radioopaque inclusion in the nasal airway would have made the radiologic diagnosis much easier. Presence of such a radioopaque wire in the missing flange would have completely laid to rest fears that the flange was

deeper in the tracheobronchial tree or in the digestive tract.

Another valuable lesson is that, no matter how unlikely it seems that the equipment could have been aspirated, if the position of the foreign body is not known for certain, the patient should undergo bronchoscopy prior to intubation. Laryngoscopy was performed by experienced anesthesiologists and otolaryngologists, all of whom saw the vocal cords in the open position, and none was able to recognize the nasal airway below the glottis. While preparing the patient for endoscopy, a lively debate took place over the impossibility of this awake, semialert, and only intermittently coughing patient having aspirated an object as large as a nasal airway without more respiratory symptoms. The symptom complex observed in sedated, disoriented, or elderly or very young patients can be an unreliable indicator of the possible aspiration.

Nasal airways with moveable flanges carry a risk of aspiration, since, when lubricated for insertion, the adjustable flange can slip off, permitting aspiration of the tube. Radioopaque inclusions in any equipment used near patients make the diagnosis of foreign body aspiration much easier, but when there is any doubt as to the location of a foreign body, bronchoscopy should be performed prior to intubation to avoid potentially pushing a foreign body further into the tracheobronchial tree.

REFERENCES

1. Wanner A: Nasopharyngeal airway: A facilitated access to the trachea. *Ann Int Med* 75:593-595, 1971
2. Howat DDC: Disposable nasopharyngeal airways—a potential hazard (Letter to the Editor). *Anaesthesia* 37:101, 1982

Anesthesiology
62:535-538, 1985

Compressed Spectral Array EEG Monitoring during Cardiac Arrest and Resuscitation

WILLIAM L. YOUNG, M.D.,* AND EUGENE ORNSTEIN, PH.D., M.D.†

Knowledge of the electrical activity of the brain during cardiac arrest and resuscitation has been gained almost exclusively from animal models of cerebral isch-

emia. Ongoing EEG monitoring in patients who are hemodynamically stable and suffer sudden but reversible cardiac arrest is extremely rare. One such instance of EEG monitoring in a patient suffering an episode of intraoperative ventricular asystole with successful resus-

* Instructor in Clinical Anesthesiology.

† Assistant Professor of Anesthesiology.

Received from the Department of Anesthesiology, College of Physicians and Surgeons, Columbia University, 630 W. 168th St., New York, New York 10032. Accepted for publication October 30, 1984.

Address reprint requests to Dr. Young.

Key words: Complications: arrest, cardiac. Monitoring: Spectral array EEG.