

Anesthesiology  
62:667-669, 1985

## Malposition of Left-sided Double-lumen Endobronchial Tubes

JAY B. BRODSKY, M.D.,\* MARK S. SHULMAN, M.D.,† JAMES B. D. MARK, M.D.‡

Double-lumen endobronchial tubes can be used to selectively collapse and/or ventilate either lung during operations in the thorax. The major complications associated with these tubes are airway trauma and malposition.<sup>1</sup> Laryngeal, tracheal, and bronchial trauma can be caused by bulky, red rubber double-lumen endobronchial tubes. Trauma is less common with the thinner, softer polyvinyl chloride (PVC)§ double-lumen tube.<sup>2</sup> However, tube malposition with subsequent impaired gas exchange or inability to isolate and collapse the lung may occur more frequently when smaller double-lumen tubes, such as the PVC tube, are used.<sup>3</sup>

We have observed a potentially serious problem with malpositioned left PVC double-lumen tubes resulting in partial left lung airway obstruction. Two cases are described.

### REPORT OF A CASE

*Patient 1.* A 66-year-old, 74-kg man was scheduled for left upper lobectomy. Following induction of general anesthesia, his trachea was intubated without difficulty with a 37-F left-sided PVC double-lumen endobronchial tube. The tube was advanced into the left bronchus until moderate resistance to further passage was encountered. The tube's position was confirmed by auscultation.<sup>4</sup> Both the tracheal and endobronchial cuffs were inflated with air, and the patient was ventilated through both lumens. Bilateral chest wall movement was observed visually, and breath sounds appeared to be equal over both lungs. With both cuffs inflated, the right (tracheal) lumen was occluded with a clamp. Breath sounds were heard only over the left lung. When the left (endobronchial) lumen was clamped, breath sounds seemed to be present only over the right lung. General anesthesia was maintained with O<sub>2</sub> and isoflurane. The patient was placed in the right lateral decubitus position, and the tube was rechecked by auscultation and was felt to be positioned correctly. A left thoracotomy was performed. In order to facilitate surgery by selectively collapsing the left lung, the left (endobronchial) lumen of the tube was clamped. The dependent (right) lung was ventilated while the lumen to the nondependent (left) lung was opened to air distal to the clamp. The left lower lobe collapsed immediately, but

the left upper lobe as well as the right lung (as noted by mediastinal movement) continued to be ventilated. The balloon cuffs of the endobronchial and tracheal lumens were deflated, and the tube was withdrawn approximately 2 cm. Both cuffs were reinflated and the left lumen was clamped as before. Following these maneuvers, the entire left lung collapsed, while the right lung was ventilated. Arterial blood gases during right one-lung ventilation were satisfactory, and the procedure continued without further complications. The remaining left lung easily was reinflated at the end of the procedure without changing the position of the double-lumen tube.

*Patient 2.* A 68-year-old, 82-kg man was scheduled for right lower lobectomy. Following induction of general anesthesia, his trachea was intubated without difficulty with a 39-F left-sided PVC double-lumen tube. The tube's position in the left bronchus was confirmed by auscultation using the method described in the first case. The patient was placed in the left lateral decubitus position, and the tube's position was rechecked and appeared to be correct. The endobronchial cuff was deflated. Anesthesia was maintained with O<sub>2</sub> and isoflurane. An arterial blood gas obtained while both lungs were being ventilated with a tidal volume of 850 ml at a rate of 8/min revealed a PaO<sub>2</sub> of 548 mmHg. During the operation, the left cuff was reinflated with air and the right lung was selectively collapsed by clamping the right (tracheal) lumen. The dependent (left) lung was ventilated, while the lumen to the nondependent (right) lung was opened to air distal to the clamp. The ventilator settings were left unchanged following these maneuvers. Fifteen minutes later, PaO<sub>2</sub> was 54 mmHg. Because of our recent experience with the case previously described, we considered the possibility that the tube was too far into the left main stem bronchus with the bronchial cuff obstructing the left upper lobe bronchus, preventing ventilation of that lobe. We deflated both cuffs and withdrew the tube approximately 1.5-2 cm. The right lung again was selectively collapsed, and the ventilator settings were not changed. Fifteen minutes after repositioning the tube, the PaO<sub>2</sub> now was 273 mmHg. There were no further complications, and the remaining right lung was reinflated easily at the completion of surgery.

### DISCUSSION

Although intubation of the bronchus of the nonoperative (dependent) lung with a double-lumen tube has been recommended,<sup>3</sup> many anesthesiologists prefer a left-sided tube for both right and left thoracotomies because obstruction of the right upper lobe bronchus with a right-sided double-lumen tube is relatively common. This occurs because the orifice of the right upper lobe bronchus normally originates from the right main stem bronchus shortly below the carina. The anatomic configuration of the bronchial tree is different on the left side, and the potential for obstruction of the left upper lobe bronchus is reduced, owing to the greater length of the left main stem bronchus. Several reviews

\* Associate Professor (Anesthesia).

† Assistant Professor (Anesthesia).

‡ Professor (Surgery), Head Division of Thoracic Surgery.

Received from the Departments of Anesthesia and Surgery, Stanford University School of Medicine, Stanford, California. Accepted for publication December 13, 1984.

Address reprint requests to Dr. Brodsky: Department of Anesthesia, Stanford University Medical Center, Stanford, California 94305.

Key words: Anesthesia: thoracic. Equipment: tubes, endobronchial. Intubation: complications.

§ Bronco-cath®, National Catheter Company, Argyle, New York.

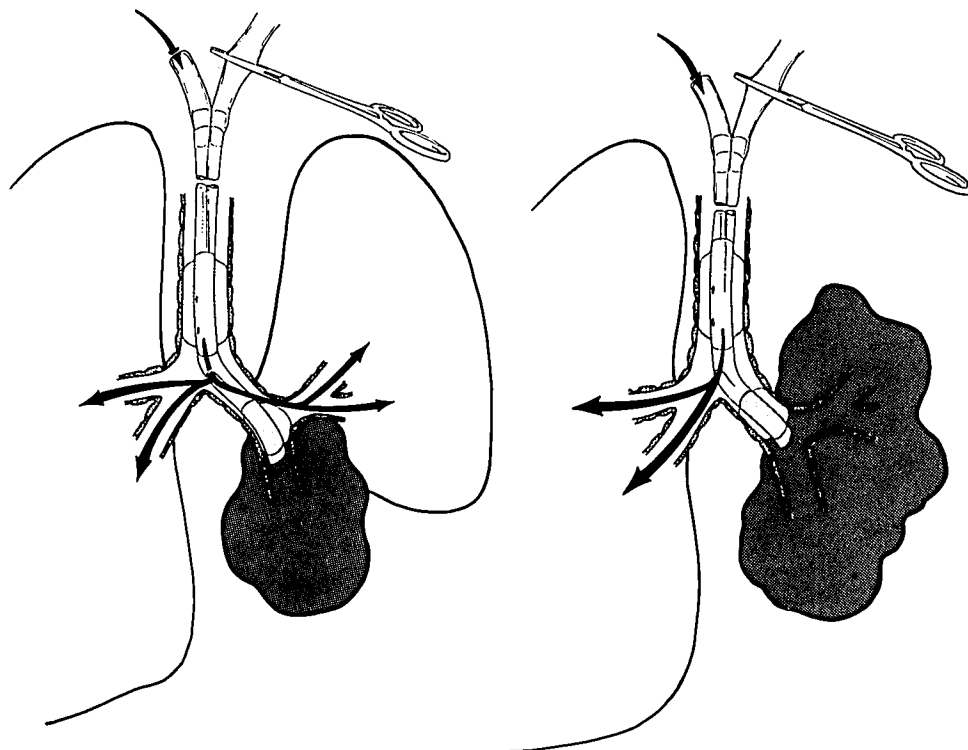


FIG. 1. Using a left double-lumen tube, after clamping the left (endobronchial) lumen, the left upper lobe and entire right lung continued to be ventilated. Withdrawing the tube back 2 cm corrected the problem.

of the complications associated with double-lumen tubes have mentioned the possibility of inserting a left-sided tube too deep into the left main stem bronchus.<sup>1,3</sup> However, obstruction of the left upper lobe bronchus as a cause of hypoxemia during left one-lung anesthesia is not well recognized.

The most common cause for malposition of a double-lumen tube is selection of a tube that is inappropriately small.<sup>3</sup> This is certainly the major factor in allowing an endobronchial tube to be placed too far into a bronchus. This complication is probably rare when bulkier, red rubber left-sided tubes are used. We believe that by using the largest tube possible, the chance of obstruction of the left upper lobe can be reduced.

Other complications associated with double-lumen tubes also can be reduced by using larger tubes. There is less resistance to air flow during one-lung ventilation through a single lumen of a larger tube. With smaller tubes, larger volumes of air are necessary to inflate the bronchial cuff to achieve an airtight seal, and overdistention can produce pressure damage to the bronchial mucosa and even bronchial rupture.<sup>5</sup>

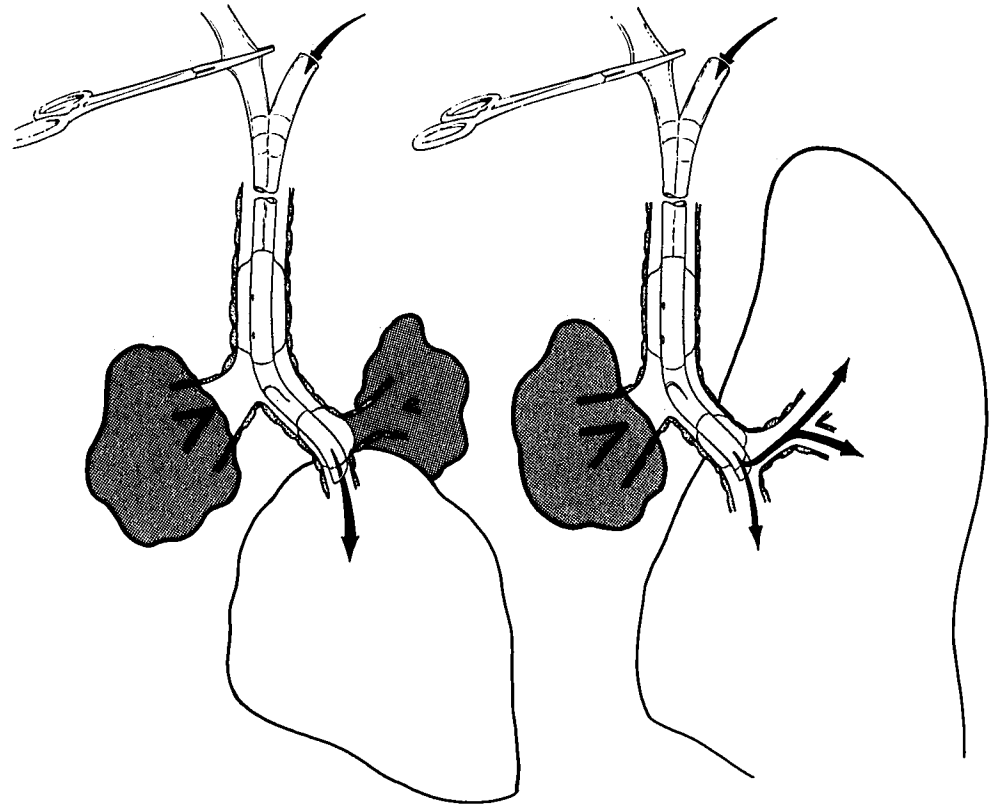
We believe that using small left-sided double-lumen tubes, obstruction of the left upper lobe bronchus occurs more frequently than realized, and that this can be an important cause of hypoxemia during one-lung ventilation during right thoracotomy. Since we have become

aware of this problem, we have noted its occurrence in several patients. We have confirmed this complication during operations when a median sternotomy incision allowed us to visually observe both lungs simultaneously. In one patient, using a left-sided double-lumen tube, after clamping the left lumen of the tube the left upper lobe and the entire right lung continued to be ventilated, as occurred in the first case described (fig. 1). In two other patients intubated with left double-lumen tubes, we observed the collapse of the left upper lobe with continued inflation of the left lower lung after the right lung was selectively collapsed (fig. 2). In all three cases, simply withdrawing the tube 1–2 cm corrected the problem. Although this maneuver may have loosened a mucous plug or uninked the tip of the left lumen, repositioning the obstructing endobronchial cuff away from the upper lobe bronchus is the most likely explanation for the immediate improvement observed.

Several factors often mandate the use of a small tube. These can include inability to introduce a larger tube through the larynx or past the carina, and intrinsic or extrinsic obstruction of the main stem bronchus.

Although fiberoptic bronchoscopy has been recommended for placement of double-lumen tubes,<sup>6</sup> we do not use this technique routinely. Now that we recognize the problem of left upper lobe obstruction with left double-lumen tubes, we carefully auscultate over the

FIG. 2. Using a left double-lumen tube, after clamping the right (tracheal) lumen, the left-upper lobe and entire right lung collapsed. Withdrawing the tube back 2 cm corrected the problem.



area of the upper lung fields to determine if the entire lung is being ventilated appropriately. When auscultation is difficult, fiberoptic bronchoscopy down the tracheal lumen can help the anesthesiologist determine if the double-lumen tube is positioned correctly. If the blue (endobronchial) cuff of the PVC tube is observed just below the carina in the left main bronchus, obstruction of the left upper lobe bronchus will be avoided.

When using a double-lumen tube, the largest tube that can be placed should be used. In instances of severe hypoxemia, while using a left double-lumen tube during right thoracotomy or with the obvious failure to collapse the left upper lobe during left thoracotomy, the tube may be too deep in the left bronchus. Simply withdrawing the tube 1–2 cm may correct the problem while still enabling the anesthesiologist to selectively collapse either lung as needed.

#### REFERENCES

1. Black AMS, Harrison GA: Difficulties with positioning Robertshaw double lumen tubes. *Anaesth Intensive Care* 3:299–311, 1975
2. Burton NA, Watson DC, Brodsky JB, Mark JBD: Advantages of a polyvinyl chloride double-lumen tube over conventional double-lumen tubes in thoracic surgery. *Ann Thorac Surg* 36:78–84, 1983
3. Wilson RS: Endobronchial intubation, *Thoracic Anesthesia*. Edited by Kaplan JA. New York, Churchill Livingstone, 1983, pp 389–402
4. Brodsky JB, Mark JBD: A simple technique for accurate placement of double-lumen endobronchial tubes. *Anesth Rev* 10:26–30, 1983
5. Burton NA, Fall SM, Lyons T, Graeber GM: Rupture of the left main-stem bronchus with a polyvinylchloride double-lumen tube. *Chest* 83:928–929, 1983
6. Benumof JL: Physiology of the open chest and one-lung ventilation, *Thoracic Anesthesia*. Edited by Kaplan JA. New York, Churchill Livingstone, 1983, pp 287–316