

Control of Life-threatening Air Leak after Gastrostomy in an Infant with Respiratory Distress Syndrome and Tracheoesophageal Fistula

HELEN W. KARL, M.D.*

Recent improvements in anesthetic and surgical techniques have allowed almost 100% survival in otherwise healthy term infants born with esophageal atresia and tracheoesophageal fistula (TEF).¹⁻⁵ These patients are candidates for early thoracotomy, division of the fistula, and primary esophageal repair. At the other end of the spectrum are those who weigh less than 1,800 g or have severe pneumonia and congenital anomalies. These high-risk infants constitute at least 25% of the TEF population¹⁻⁷; there is still a 15-60% mortality in this group.^{1-5,7} In moderate and high-risk patients, thoracotomy usually is delayed to stabilize the infants medically and to evaluate them thoroughly. In this group, gastrostomy is performed early to prevent aspiration of gastric contents.

Premature infants with TEF and idiopathic respiratory distress syndrome (RDS) often require endotracheal intubation and positive pressure ventilation shortly after birth. Because of their poor lung compliance, positive-pressure ventilation may be distributed preferentially to the stomach, producing a vicious cycle of abdominal distention, further compromise of ventilation, and an increased risk of aspiration of gastric contents. Extreme gastric dilatation even may lead to perforation⁸ or cardiac arrest.⁹ Performing a gastrostomy will interrupt this cycle, but if the fistula is large, and if the lungs are not compliant, it may produce a life-threatening air leak (fig. 1).

REPORT OF A CASE

A boy weighing 1,270 g was born by vaginal delivery at an estimated gestational age of 30 weeks, with Apgar scores of 2 at 1 min and 5 at 5 min. He remained apneic in the delivery room, and his trachea was intubated with a 2.5-mm endotracheal tube. His

chest radiograph showed air bronchograms and "ground glass" pulmonary infiltrates, consistent with RDS. On arrival at our hospital, FI_{O_2} was 1.0, with a respiratory rate of 60 breaths/minute and peak inspiratory pressures of 25 cmH₂O. Pa_{O_2} was 55 mmHg, Pa_{CO_2} was 62 mmHg, and pH_a 7.20. A nasogastric tube could not be passed into the stomach, his abdomen progressively distended, and the diagnosis of proximal esophageal atresia with tracheoesophageal fistula was made. When he was 12 h old, he underwent gastrostomy under fentanyl-air-oxygen anesthesia. We varied the FI_{O_2} between 0.8 and 1.0, depending on the transcutaneous oxygen tension (Tc_{O_2}). The Pa_{O_2} values obtained from the umbilical arterial line correlated well with the transcutaneous tensions. Opening the gas-

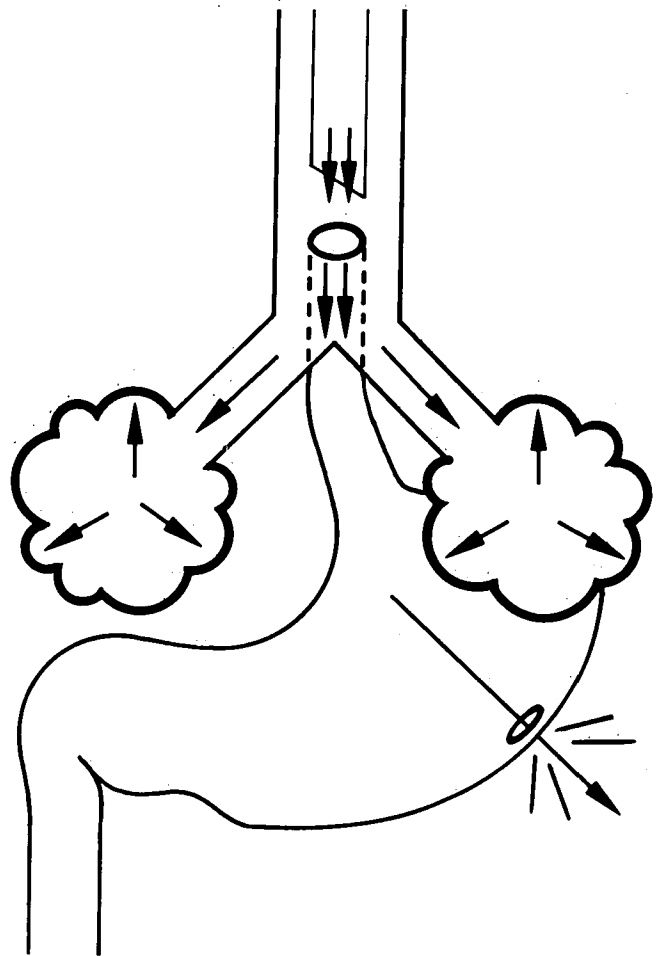


FIG. 1. Mechanics of respiratory compromise: life-threatening air leak despite high fresh gas flow and respiratory rate after gastrostomy in TEF with RDS requiring IPPV.

* Assistant Professor of Anesthesia and Pediatrics.

Received from the Department of Anesthesia, Milton S. Hershey Medical Center, Pennsylvania State University College of Medicine, Hershey, Pennsylvania 17033. Accepted for publication December 13, 1984. Presented at the Section on Anesthesia, American Academy of Pediatrics, Phoenix, Arizona, March 1984.

Address reprint requests to Dr. Karl.

Key words: Anesthesia; pediatric. Lung: respiratory distress syndrome; tracheoesophageal fistula.

trostomy made ventilation and oxygenation markedly worse; there was a large air leak via the gastrostomy tube, and Tc_{O_2} decreased from 91 to 57 mmHg, despite increased ventilation.

We elected to attempt to stop the air leak by occlusion of the lower esophagus with a Fogarty catheter passed retrograde from the stomach. The surgeon reshaped a #14 mushroom gastrostomy catheter, cutting a hole in the tip. Then, using cross-table lateral fluoroscopy, he manipulated a 4-French Fogarty catheter with a 1.5-ml balloon through the mushroom catheter into the distal esophagus. After inflation of the balloon with Renografin®, we could maintain ventilation with lower respiratory rates and fresh gas flows, and Tc_{O_2} tensions immediately improved (fig. 2). The child was returned to the neonatal intensive care unit in stable condition.

The infant's lung disease improved over the next 2 days to the point that he was able to withstand transpleural division of his fistula with primary esophago-esophagostomy. He subsequently recovered, grew well, and was discharged 8 weeks after the operation. The patient had no complications that could be attributed to this technique. Unfortunately, however, 6 months after his initial repair he required closure of a recurrent fistula. His gastroesophageal reflux responded to medical therapy, and he now is doing well.

DISCUSSION

As a result of improvements in many aspects of the care of small neonates, mortality after TEF repair now is associated with the presence of other anomalies and severe RDS rather than size alone.^{4,5} This infant's severe respiratory failure obviously places him in the highest risk group.⁴ Filston *et al.*⁵ report a 90% mortality in infants with an initial room air Pa_{O_2} of less than 60 mmHg. Opening the gastrostomy might have facilitated ventilation by decreasing intraabdominal pressure, as well as by preventing further reflux of gastric contents into the lungs. However, this infant with stiff lungs and a large fistula now had a low resistance path for gas flow, and air flow through the fistula increased dramatically, providing even less pulmonary ventilation. At this point, he clearly was too ill for repair. We hoped that if we could correct the air leak and allow time for improvement of his RDS, he then would be able to tolerate further surgery.

A number of approaches to this problem have been described. Staged repair was proposed by Holder in 1962.¹⁰ The first stage, gastrostomy, is followed by retropleural division of the fistula under local anesthesia to allow enteral nutrition. Finally, esophageal anastomosis is performed when the infant is larger and stronger. We thought that our patient's respiratory status was so precarious that he would not tolerate any thoracotomy, even one limited to retropleural division of the fistula.

In 1973, Salem *et al.*¹¹ described distal positioning of the endotracheal tube, with the bevel facing anteriorly, and the posterior wall of the tube occluding the fistula. This works well in the operating room, while the patient is under close supervision. However, since a small change in tube position would be critical, we thought that this

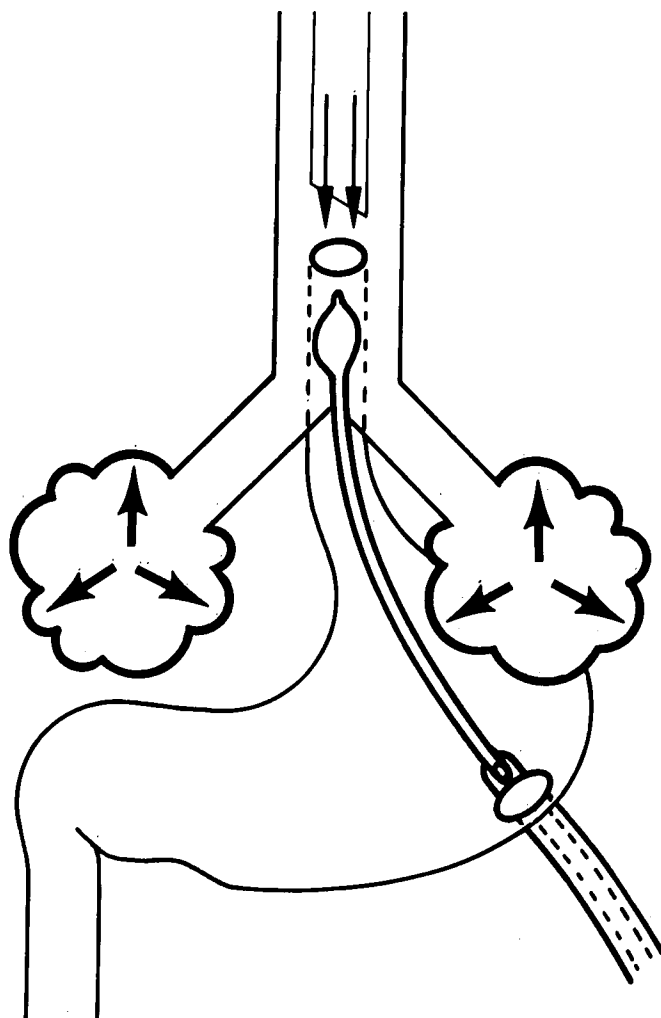


FIG. 2. Retrograde Fogarty balloon occlusion of the distal esophageal segment permits ventilation.

technique would not be reliable for several days of ICU care.

A third possibility was devised by Filston *et al.*¹² They placed a Fogarty balloon catheter through a bronchoscope into the fistula. Their patient also had RDS but was somewhat older, larger, and had less respiratory compromise than ours. We considered bronchoscopy to be unduly dangerous in our patient. Compared with bronchoscopic catheter placement, there are several advantages to our retrograde approach to the distal esophagus. This technique does not require interruption of ventilation and can be combined with Salem's tube-positioning technique to provide maximum ventilation during catheter placement. With bronchoscopic placement, the additional translaryngeal foreign body may increase the risk of subglottic stenosis.

To date, we have identified two potential complica-

tions. The first is accidental displacement: withdrawal again would result in escape of tracheal gas through the gastrostomy and wasted ventilation; advancement of the catheter could cause the balloon to occlude the trachea. If the catheter is displaced, it can be repositioned in the ICU under fluoroscopy. Tracheal occlusion was recognized by Filston *et al.* as a potential complication of withdrawal if the bronchoscopic approach is used.¹² I believe that withdrawal of a soft catheter is more likely than further insertion and that this factor contributes to the safety of the retrograde approach. Whichever approach is used, the consequences of catheter displacement should be clear to all those caring for the infant. The second possible complication is compromise of the circulation to esophageal mucosa in contact with the balloon. We avoided this by intermittently deflating the Fogarty balloon under close observation and transcutaneous oxygen monitoring; there has been no evidence of distal stricture in our patient.

Other authors¹³⁻¹⁵ have reported occlusion of the fistula to allow enteral feeding. Leininger¹³ placed a relatively tight silastic band around the distal fistula. His patient did not require positive-pressure ventilation during the 2-week delay until repair. Hofman¹⁴ and Kadowaki *et al.*¹⁵ placed a transgastric balloon catheter into the distal esophageal segment, keeping it in place with a loose silastic band¹⁴ or absorbable suture material.¹⁵ Kadowaki's group also directly addressed the question of pressure injury to the distal esophagus. In puppies they measured the pressure exerted by the balloon on the esophagus. If less than 3 ml of saline was used for inflation, the lateral pressure did not exceed 10 mmHg; they concluded that compromise of the microcirculation is unlikely at these pressures.

Prematurity and respiratory failure occur frequently with TEF. In infants with poor lung compliance, gastrostomy may make ventilation more difficult by providing a low-resistance pathway for respiratory gases. This case suggests that, although it is not without potential for complications, retrograde Fogarty balloon occlusion of the distal esophagus is a useful and apparently benign short-term solution to this problem.

The author thanks Drs. Thomas V. N. Ballantine and Wayne Richenbacher; without their support and skill this infant would not have survived.

REFERENCES

1. Koop CE, Schnauffer L, Broennele AM: Esophageal atresia and tracheoesophageal fistula: Supportive measures that affect survival. *Pediatrics* 54:558-564, 1974
2. Randolph JG, Altman P, Anderson KD: Selective surgical management based upon clinical status in infants with esophageal atresia. *J Thorac Cardiovasc Surg* 74:335-342, 1977
3. Grosfeld JL, Ballantine TVN: Esophageal atresia and tracheoesophageal fistula: Effect of delayed thoracotomy on survival. *Surgery* 84:394-402, 1978
4. Louhimo I, Lindahl H: Esophageal atresia: Primary results of 500 consecutively treated patients. *J Pediatr Surg* 18:217-229, 1983
5. Filston HC, Rankin JS, Grimm JK: Esophageal atresia: Prognostic factors and contribution of preoperative telescopic endoscopy. *Ann Surg* 199:532-537, 1984
6. Waterston DJ, Bonham-Carter RE, Aberdeen E: Congenital tracheo-oesophageal fistula in association with oesophageal atresia. *Lancet* 2:55-57, 1963
7. Cozzi F, Wilkinson AW: Low birth weight babies with oesophageal atresia or tracheo-oesophageal fistula. *Arch Dis Child* 50: 791-795, 1975
8. Jones TB, Kirchner SG, Lee FA, Heller RM: Stomach rupture associated with esophageal atresia, tracheoesophageal fistula and ventilatory assistance. *AJR* 134:675-677, 1980
9. Baraka A, Slim M: Cardiac arrest during IPPV in a newborn with tracheoesophageal fistula. *ANESTHESIOLOGY* 32:564-565, 1970
10. Holder TM, McDonald VG, Woolley MM: The premature or critically ill infant with esophageal atresia: Increased success with a staged approach. *J Thorac Cardiovasc Surg* 44:344-358, 1962
11. Salem MR, Wong AY, Lin YH, Firor HV, Bennett EJ: Prevention of gastric distention during anesthesia for newborns with tracheoesophageal fistulas. *ANESTHESIOLOGY* 38:82-83, 1973
12. Filston HC, Chitwood WR Jr, Schkolne B, Blackmon LR: The fogarty balloon catheter as an aid to management of the infant with esophageal atresia and tracheoesophageal fistula complicated by severe RDS or pneumonia. *J Pediatr Surg* 17:149-151, 1982
13. Leininger BJ: Silastic banding of esophagus with subsequent repair of esophageal atresia and tracheoesophageal fistula. *J Pediatr Surg* 7:404-407, 1972
14. Hofmann S: Emergency repair of esophageal atresia with lower fistula and segment elongation in cases with a large gap between segments. *J Pediatr Surg* 11:257-259, 1976
15. Kadowaki H, Nakahira M, Umeda K, Yamada C, Takeuchi S, Tamate S: A method of delayed esophageal anastomosis for high-risk congenital esophageal atresia with additional intraabdominal anomalies; Transgastric balloon "fistulectomy." *J Pediatr Surg* 17:230-233, 1982