

Anesthesiology
62:683-684, 1985

Macroglossia in a 16-month-old Child after a Craniotomy

JAMES F. MAYHEW, M.D.,* MICHAEL MINER, M.D., PH.D.,† JEFFREY KATZ, M.B., CH.B.‡

Massive swelling of the tongue has been reported following surgery in the sitting position.^{1,2} In both cases the authors identified either an oral airway or a bite block as a mechanical obstruction that impaired venous and lymphatic drainage. Our report describes a case of massive swelling of the tongue and airway obstruction in a 16-month-old achondroplastic dwarf following suboccipital craniectomy and cervical laminectomy in the sitting position where no oral device was used.

REPORT OF A CASE

A 16-month-old male achondroplastic dwarf underwent a suboccipital craniectomy and cervical laminectomy in the sitting position. He was having eight to ten apneic episodes associated with cyanosis per week. Computed tomography scan showed compression of the foramen magnum. His weight was 8.5 kg. Apart from his current problems, his medical history was unremarkable.

Anesthesia was induced with nitrous oxide-oxygen-halothane, and the trachea was intubated with a 4.5 uncuffed endotracheal tube without difficulty. An oral esophageal stethoscope was inserted. No bite block or oral airway was used. He was positioned in a Mayfield three-point head holder using pediatric bolts. The intraoperative course was incident free. Following the 5-h procedure, he was awake, and the trachea was extubated in the operating room. At that time the patient's tongue was noted to be slightly larger than normal but was not protruding from his mouth or causing respiratory difficulty. After 20 min, his tongue had swollen markedly and was protruding from his mouth. He developed increasing respiratory difficulty necessitating orotracheal intubation (uncuffed 4.5 mm I.D. tube). We elected to change to a nasotracheal tube of the same size (fig. 1). Following intubation he was given 6 mg dexamethasone iv. Over the next 24 h we provided mechanical ventilation with intermittent mandatory ventilation (IMV) (4/min) and positive end-expiratory pressure (PEEP) (3 cmH₂O). Repeated injections of dexamethasone (6 mg iv) failed to decrease the lingual swelling. The child's tongue continued to swell, and on the third postoperative day he underwent lingual debridement and a tracheostomy. The swelling has receded slowly over a 12-week period. He now is decannulated with no airway obstruction.

DISCUSSION

The etiology of macroglossia following surgery in the sitting position is unknown. Some have suggested¹⁻³ that the macroglossia is caused by obstruction to venous and

lymphatic drainage, but no studies have been done to substantiate this view.

Two pathophysiologic questions arise from this case. First, what is the etiology of macroglossia following surgery in the sitting position? Obstruction to venous and lymphatic drainage was the suggested mechanism in the previous case reports.¹⁻³ Munshi *et al.*³ do not mention any oral airway or bite block, whereas the other authors^{1,2} suggest that these devices may have exacerbated the obstruction of venous and lymphatic drainage of the tongue. In our case no extrinsic mechanical obstruction was present. Either the endotracheal tube or esophageal stethoscope could have been responsible for obstruction to lymphatic or venous drainage, but in view of the number of endotracheal tubes and esophageal stethoscopes placed daily without complication, this seems unlikely. Secondly, does extreme flexion of the neck lead to such severe obstruction of venous and lymphatic outflow that massive edema of the tongue results? Our patient had thrombosed veins on the underside of the tongue on the third postoperative day. Whether this occurred prior to or is the result of the tongue edema is unclear.

An important consideration in determining the etiology of the swelling is the abnormal neck anatomy of our patient. Achondroplastic dwarfs have short necks and excess subcutaneous tissue. This, coupled with the extreme flexion, may have contributed to the development of venous and lymphatic obstruction of the tongue. A similar case in a normal adult was attributed to prolonged flexion of the neck.⁴ However, this incident may have been related to the technique of securing the tube.

Another consideration in this case is the delayed onset of the severe swelling. The tracheas of our patient and the patient of Munshi *et al.*³ were extubated immediately upon awakening from anesthesia, having been moved from the sitting to a modified Fowler's position. Although we attempted to relieve the subsequent swelling by returning the patient to a sitting position, the swelling continued, necessitating reintubation (fig. 1). Did the change from sitting to supine aggravate the swelling, and would placing the patient to a head-up position have prevented or at least lessened the degree of tongue edema?

This case emphasizes the need for attention to anatomic considerations when patients are in the sitting position with the neck flexed. In such cases, thorough

* Assistant Professor, Director, Pediatric Anesthesiology.

† Associate Professor, Neurosurgery.

‡ Assistant Professor, Director, Neurosurgical Anesthesiology.

Received from the Departments of Pediatric Anesthesiology, Neurosurgery, and Neurosurgical Anesthesiology, The University of Texas Medical School, 6431 Fannin, MSMB 5.020, Houston, Texas 77030. Accepted for publication December 21, 1984.

Address reprint requests to Dr. Mayhew.

Key words: Anesthesia; neurosurgical. Complications: macroglossia.

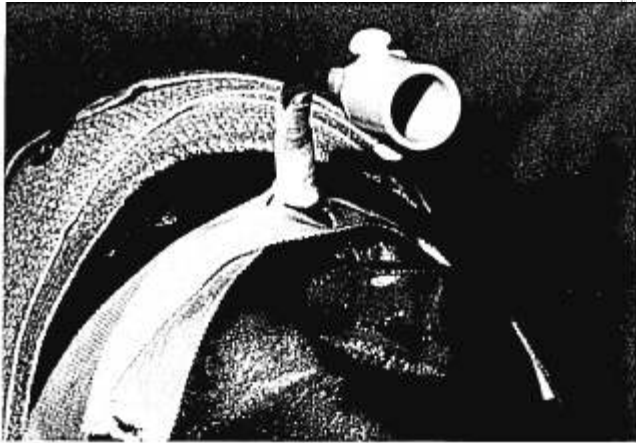


FIG. 1. Patient in recovery room after nasal intubation. Note markedly swollen tongue extruding from mouth.

Anesthesiology
62:684-687, 1985

Major Errors in Thermodilution Cardiac Output Measurement during Rapid Volume Infusion

RANDALL C. WETZEL, M.D.,* AND TERRY W. LATSON, M.D.†

Thermodilution measurement of cardiac output has become a cornerstone of hemodynamic monitoring in anesthesia and critical care medicine.^{1,2} Understanding the theory of the thermodilution technique and the assumptions underlying this theory is necessary to avoid several sources of error inherent in this technique. For example, thermodilution cardiac output measurements can be influenced by respiratory variations,^{2,3} the volume and temperature of injectate,^{4,5} the patient's temperature,^{6,7} and other physical characteristics of the measurement system.^{2,3,8,9} Recently, we observed marked variations in thermodilution cardiac output measurements in patients following open heart surgery while they were receiving intermittent rapid iv fluid infusions via a peripheral iv catheter. Whereas alterations in the volume or temperature of the injectate obviously influence the accuracy of thermodilution measurement of cardiac output,^{2,4,5} the effect of concurrent peripheral iv volume infusions has not been reported previously.

assessment of the airway should be made before extubation of the trachea is considered to ensure that facial or tongue edema has not occurred. Furthermore, our case demonstrates that despite these measures, postanesthetic lingual swelling with airway obstruction still can occur.

REFERENCES

1. McAllister RG: Macroglossia—positional complication. *ANESTHESIOLOGY* 40:199-200, 1974
2. Ellis SC, Bryan-Brown CW, Hyderally H: Massive swelling of the head and neck. *ANESTHESIOLOGY* 42:102-103, 1975
3. Munshi CA, Dhamre MS, Gandhi SK: Postoperative unilateral facial oedema: A complication of acute flexion of the neck. *Can Anaesth Soc J* 31:197-199, 1984
4. Tattersall MP: Massive swelling of the face and tongue. A complication of posterior cranial fossa surgery in the sitting position. *Anaesthesia* 39:1015-1017, 1984

Theoretically, small fluctuations in blood temperature caused by peripheral infusions could cause major errors in cardiac output measurements. The following protocol was designed to determine if rapid volume infusion into a peripheral vein altered the accuracy of thermodilution measurement of cardiac output and to quantitate the magnitude of this error in a clinically relevant situation.

METHODS

Fourteen patients, ages 42-76 yr, prospectively were studied following discontinuation of cardiopulmonary bypass for cardiac surgery. Approval of our Committee on Clinical Investigation and informed consent of individual patients was obtained prior to surgery. Routine monitoring required for the operative management of these patients included insertion of an arterial cannula and a triple-lumen Swan-Ganz® catheter for the determination of thermodilution cardiac outputs. The patient's monitoring or management was not altered for the purpose of this study.

The thermodilution cardiac output was determined in the standard fashion using a Lyons® (Electronics for Medicine Model #TCCO-04) cardiac output computer while simultaneously recording the analog output of the thermodilution curve. The computer was calibrated at the beginning of the case and prior to discontinuing cardiopulmonary bypass. Cardiac outputs were determined in the standard fashion with the injection of 10

* Resident, Anesthesiology/Critical Care Medicine.

† Instructor, Anesthesiology/Critical Care Medicine.

Received from the Department of Anesthesiology/Critical Care Medicine, The Johns Hopkins Medical Institutions, 600 N. Wolfe Street, Baltimore, Maryland 21205. Accepted for publication December 21, 1984.

Address reprint requests to Dr. Wetzel.

Key words: Measurement techniques: thermodilution cardiac output.