

Anesthesiology  
63:195-197, 1985

## Perioperative Hypothyroidism: An Unusual Postanesthetic Diagnosis

J. PATRICK LEVELLE, M.D.,\* MICHAEL W. JOPLING, M.D.,† GARRY S. SKLAR, M.D.‡

Severe hypothyroidism may manifest during and after anesthesia. We report a case of undiagnosed hypothyroidism and describe its manifestations, the unusual manner in which it was diagnosed, and its treatment.

### REPORT OF A CASE

A 59-year-old, 105-kg woman was scheduled for emergency open reduction and internal fixation of a left hip fracture, secondary to metastatic breast cancer. Medication included analgesia with codeine and tamoxifen, 10 mg twice daily. Significant medical history included morbid obesity and benign right parotid mass present for greater than 20 years without change; otherwise, physical examination was unremarkable. Significant laboratory findings included hemoglobin, 11.1 g/dl; hematocrit, 34%; glucose, 171 mg/dl; cholesterol, 380 mg/dl; alkaline phosphatase, 175  $\mu$ g/ml; lactic dehydrogenase, 400  $\mu$ g/ml; and serum glutamic oxaloacetic transaminase, 35  $\mu$ g/ml. ASA physical status III-E was assigned.

Preoperative arterial blood pressure was 120/90 mmHg. ECG revealed normal sinus rhythm at a rate of 90 bpm and chest roentgenogram was normal. The patient had been NPO for greater than 8 h, and no preoperative medications were given. Because of the neck mass and obesity, an awake oral endotracheal intubation was performed with the help of topical lidocaine. Intubation of the trachea was easily accomplished and immediately followed by iv administration of sodium thiopental, 200 mg, and fentanyl, 100  $\mu$ g. Sixty per cent N<sub>2</sub>O in O<sub>2</sub> was introduced into the breathing circuit with controlled ventilation. The patient was positioned in the right lateral decubitus position, after which no arterial blood pressure could be obtained from the arm, but a weak temporal pulse was palpated and the ECG revealed sinus rhythm at a rate of 90 bpm. Heart sounds still could be heard by esophageal stethoscope. N<sub>2</sub>O was discontinued, and the patient was put in the supine position, which had no effect on arterial blood pressure. Ephedrine, 20 mg, and crystalloid, 500 ml, were rapidly infused iv, which produced an

arterial systolic blood pressure of 50 mmHg, as measured by Doppler ultrasound. The heart rate and rhythm remained unchanged. Crystalloid administration was continued, and the systolic blood pressure rose to 90 mmHg. Surgery then started. Pancuronium, 4 mg, and diazepam, 2.5 mg, were administered iv; vital signs remained stable, and 30 min later 50% N<sub>2</sub>O was reintroduced. Surgery lasted 85 min, after which neuromuscular blockade was adequately reversed with neostigmine, 3.0 mg, and atropine, 1.2 mg iv. The patient awakened, followed commands, and was breathing adequate tidal volume; the trachea was extubated.

Immediately after arrival to the recovery room, the patient became dyspneic and tachypneic, and the upper airway appeared partially obstructed. This could not be relieved by assisted mask ventilation with an FI<sub>O<sub>2</sub></sub> of 1.0 through nasal or oral airway. The trachea was immediately reintubated and suctioned, but no aspirate was detected. After assisted ventilation with an FI<sub>O<sub>2</sub></sub> of 1.0, the patient resumed spontaneous breathing with an FI<sub>O<sub>2</sub></sub> of 0.5; Pa<sub>O<sub>2</sub></sub> was 36 mmHg, Pa<sub>CO<sub>2</sub></sub> was 43 mmHg, and pH was 7.40. Repeat analysis of arterial blood gases was similar, and the FI<sub>O<sub>2</sub></sub> was increased again to 1.0. Chest roentgenogram revealed bilateral infiltrates, and aspiration of gastric contents was suspected. Ventilation was controlled with an FI<sub>O<sub>2</sub></sub> of 0.6 and 10 cmH<sub>2</sub>O of positive end-expiratory pressure.

Six hours later, arterial blood pressure decreased to 70/40 mmHg and a pulmonary artery catheter was inserted; initial readings were blood pressure, 25/11 mmHg; pulmonary capillary wedge pressure, 7 mmHg; central venous pressure, 8 mmHg, and cardiac output, 2.8 l/min. Dopamine and intravascular fluids were administered with hemodynamic improvement.

Over the next 6 days the patient continued to be hemodynamically stable but was lethargic and could not be weaned from mechanical ventilation. O<sub>2</sub> consumption index, determined from the difference between arterial and mixed venous O<sub>2</sub> content and from cardiac index, was noted to be quite low, about 80 ml O<sub>2</sub> · min<sup>-1</sup> · (m<sup>2</sup>)<sup>-1</sup> (fig. 1). From these data, hypothyroidism was suspected and confirmed by serum thyroxine (T<sub>4</sub>) level, 0.4  $\mu$ g/ml (normal = 5.5–11.3  $\mu$ g/ml); thyroid stimulating hormone (TSH) level, 32  $\mu$ g/ml (normal = 0–10  $\mu$ g/ml); and tri-iodothyronine resin uptake (T<sub>3</sub>RU), 30% (normal = 25–35%).

L-thyroxine, 200  $\mu$ g, was administered iv and prednisone, 10 mg, via nasogastric tube every 12 h. Over the next 48 h the patient's respiratory status and O<sub>2</sub> consumption dramatically improved (fig. 1); 72 h after thyroid replacement was started, the patient was weaned from mechanical ventilation and the trachea extubated. L-thyroxine was continued at a dose of 200  $\mu$ g daily. The patient progressed uneventfully and was discharged from the hospital 21 days after surgery.

### DISCUSSION

There are reports of severe cardiovascular depression in hypothyroid patients during general anesthesia<sup>1-3</sup> as well as ventilatory failure associated with this disease.<sup>4</sup>

\* Resident in Anesthesiology. Current address: Department of Anesthesiology (Resident in Obstetric Anesthesia), University of Florida College of Medicine, Gainesville, Florida.

† Assistant Professor of Anesthesiology.

‡ Associate Professor of Anesthesiology. Current address: Albert Einstein College of Medicine and Bronx-Lebanon Hospital Center (Director of Anesthesiology), Bronx, New York.

Received from the Department of Anesthesiology, West Virginia University Medical Center, Morgantown, West Virginia. Accepted for publication March 5, 1985.

Address reprint requests to Dr. Levelle: Department of Anesthesiology, Box J-254, Hillis Miller Health Center, Gainesville, Florida 32610.

Key words: Complications: hypotension. Hormones: thyroid. Lung: respiratory failure. Oxygen: consumption.

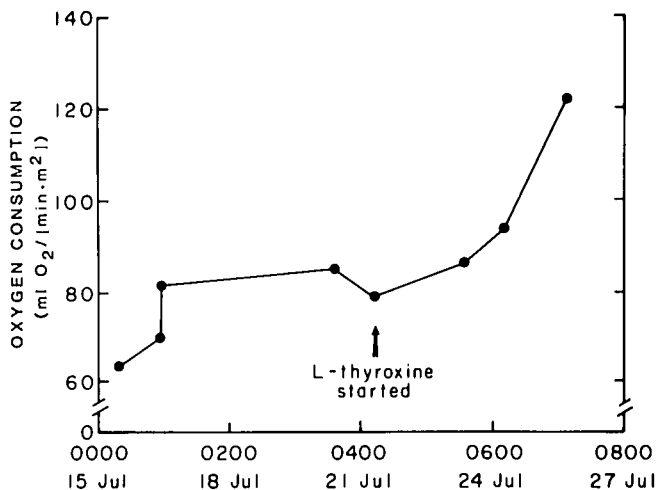


FIG. 1. Response of oxygen consumption to thyroid replacement in a patient with hypotension and respiratory failure postoperatively.

The intraoperative hypotension and postoperative respiratory failure in our patient were most likely produced by the interaction of general anesthesia, the acute stress of surgery, and hypothyroidism.

Hypovolemia could account for the initial intraoperative hypotension. Excessive bleeding can occur with a fractured hip and can result in serious intravascular fluid depletion, especially in older, chronically debilitated patients. Although the preoperative hemoglobin and hematocrit in our patient indicated mild anemia, this was considered secondary to anemia caused by chronic disease rather than acute bleeding because the hemoglobin and hematocrit values were not changed from those obtained preoperatively over several months. There were also no preoperative physical signs or symptoms of acute intravascular hypovolemia.

The combination of marked obesity and the right lateral decubitus position could have obstructed venous return from the lower body and, thus, caused hypotension.<sup>5</sup> This may have been an initial factor; however, arterial blood pressure was unaffected when the patient was returned to the supine position. Additionally, heart rate did not increase as would occur with profound hypotension caused by acute intravascular hypovolemia.

The presence of bilateral infiltrates immediately postoperatively on the chest roentgenogram suggested pulmonary aspiration of gastric contents. Although the patient did not vomit at any time postoperatively, reflux could not be ruled out. However, the patient was awake enough to follow commands and to communicate verbally en route from the operating room to the recovery room. Also, paralysis was adequately reversed, therefore, protective airway reflexes would have been intact and would have made aspiration unlikely. At the first sign of respiratory difficulty in the recovery room, laryngos-

copy and tracheal intubation revealed no signs of aspiration, and ventilatory failure continued although the chest roentgenogram improved and hypoxemia dissipated, which also made the diagnosis of aspiration of gastric contents more unlikely.

The dramatic respiratory improvement seen after thyroid replacement was started supports the diagnosis of ventilatory failure secondary to hypothyroidism. A previous study demonstrated hypoventilation associated with hypothyroidism, which was responsive to thyroid replacement.<sup>4</sup> Suspecting the diagnosis from O<sub>2</sub> consumption data is similar to the former use of basal metabolic rate to diagnose thyroid dysfunction, which is now diagnosed by direct measurement of thyroid and thyroid-stimulating hormones.<sup>6</sup>

In primary hypothyroidism, the serum T<sub>4</sub> and T<sub>3</sub> should be lower than normal and the TSH increased. Measurement of T<sub>4</sub> and TSH confirms the diagnosis in 90% of cases.<sup>7</sup> In cases of secondary hypothyroidism, the TSH may be normal or low. In these cases the thyroid-releasing hormone (TRH) stimulation test, which evaluates the pituitary response to exogenously administered TRH, will confirm the diagnosis.<sup>8</sup> In critically ill patients, the diagnosis cannot be confirmed by T<sub>4</sub> alone because it is often low and the patient is clinically euthyroid. In these cases, serum T<sub>4</sub> can appear to be decreased because of either a low level of thyroid binding globulin (TBG) or a decreased number of TBG binding sites. Therefore, the T<sub>3</sub>RU should be measured to assess TBG status. Our patient had primary hypothyroidism with low T<sub>4</sub> (0.4 µg/ml), elevated TSH (32 µg/ml), and normal T<sub>3</sub>RU (30%), which indicates normal TBG.

The hypothyroidism in this patient, *i.e.*, intraoperative hypotension and postoperative cardiovascular instability with respiratory failure, probably represents the interaction of general anesthesia and hypothyroidism. Any chronically obese and debilitated patient who requires surgery should be evaluated carefully for insidious hypothyroidism, and when any cardiovascular or respiratory instability occurs in such patients decreased thyroid function should be considered.

#### REFERENCES

1. Abbott TR: Anaesthesia in untreated myxoedema. Report of two cases. *Br J Anaesth* 39:510-514, 1967
2. Kim JM, Hackman L: Anesthesia for untreated hypothyroidism: report of three cases. *Anesth Analg* 56:299-302, 1977
3. Murkin JM: Anesthesia and hypothyroidism: A review of thyroxine physiology, pharmacology, and anesthetic implications. *Anesth Analg* 61:371-383, 1982
4. Zwillich CW, Pierson DJ, Hofeldt FD, Lufkin EG, Weil JV: Ventilatory control in myxedema and hypothyroidism. *N Engl J Med* 292:662-665, 1975
5. Thomas AN: The lateral decubitus position. Surgical require-

- ments, Positioning in Anesthesia and Surgery. Edited by Martin JT. Philadelphia, WB Saunders, 1978, pp 116-141
6. DeVisscher M, Burger A: Evaluation of thyroid function: Diagnostic procedures in thyroid diseases, The Thyroid Gland. Edited by DeVisscher M. New York, Raven Press, 1980, pp 206-207

7. Homburger HA, Hewan-Lowe K: Predictive values of thyroxine, thyrotropin, and triiodothyronine concentrations in serum. *Clin Chem* 25:669-674, 1979
8. Lamberg BA, Gordin A: Abnormalities of thyrotrophin secretion and clinical implications of the thyrotrophin releasing hormone stimulation test. *Ann Clin Res* 10:171-183, 1978

Anesthesiology  
63:197-199, 1985

## Anesthesia and the Lesch-Nyhan Syndrome

LAWRENCE O. LARSON, M.D., F.A.C.S.,\* AND ROBERT G. WILKINS, M.B., CH.B., F.F.A.R.C.S.†

The Lesch-Nyhan syndrome, a genetically determined disorder of purine metabolism, was first definitively described in 1964.<sup>1</sup> It is an X-linked recessive disorder that occurs exclusively in males. Biochemically the primary defect is almost entire absence of hypoxanthine-guanine-phosphoribosyltransferase (HGPRT) activity, leading to excess purine production, and elevation of uric acid concentrations throughout the body. Clinically, patients are usually mentally subnormal, with a characteristic pattern of compulsive self-mutilation, spasticity, and choreoathetosis. The hyperuricemia is associated with nephropathy, urinary tract calculi, arthritis, and tophi. Comprehensive reviews of the syndrome have been published.<sup>2,3</sup> The incidence is in excess of 5.2 cases per million male births, and life expectancy is shortened, with many patients dying of renal failure within 20 years.<sup>3</sup> Because of the high incidence of calculi, patients may present for surgery of the urinary tract, orthopedic surgery, or other unrelated surgical problems. There are no reports describing anesthetic management. We describe such a case and discuss the potential anesthetic problems, which include major abnormalities of cardiorespiratory, renal, and nervous system function.

### REPORT OF A CASE

A 23-year-old man with Lesch-Nyhan syndrome diagnosed at one year of age was admitted for treatment of partial right ureteral obstruction due to calculi in the right renal pelvis. The history obtained was poor but notably included recurrent chest infections with the last documented occurrence 6 months before admission and an absence of any seizure disorder. A cystoscopy and right retrograde

pyelogram had been performed 2 weeks before admission at another hospital, and total dental extraction had been performed at age nine to prevent further self-mutilation. No information about these anesthetics was available: they were apparently uneventful. Physical examination revealed subnormal mentation and evidence of previous self-mutilation of the upper lip and hands. Although the patient would not cooperate with a detailed examination of his oro-pharynx, we were able to note the absence of a substantial portion of his upper lip, areas of perioral scarring, the absence of dentition, and a large scarred tongue that appeared to fill his entire oral cavity when the mouth was closed and also appeared to partially occlude the airway when the patient was supine. Vital signs on admission were heart rate 80 bpm, arterial blood pressure 120/80 mmHg, temperature 37° C, and respirations of 12 breaths/min. Chest roentgenogram revealed no cardiopulmonary abnormalities, and electrocardiogram showed only a sinus tachycardia. Laboratory tests revealed: hematocrit 40%, hemoglobin concentration 14 g/dl, uric acid 0.38 mmol/l (6.4 mg/dl) (normal 0.16-0.47 mmol/l), and potassium 5.1 mmol/l. Creatinine clearance was 69 ml/min (normal 75-125 ml/min). Medication taken by the patient prior to admission included diazepam 5 mg three times a day. He was scheduled for percutaneous renal stone removal and cystoscopy under general anesthesia.

The patient was brought to the operating room 90 min after receiving diazepam 10 mg, po. An inhalation induction with isoflurane and oxygen was accomplished with spontaneous ventilation. After it was established that a satisfactory airway could be maintained via mask ventilation, tracheal intubation was performed following administration of atracurium 30 mg iv. Anesthesia was maintained with isoflurane in a mixture of 70% N<sub>2</sub>O and 30% O<sub>2</sub>, while paralysis was maintained with intermittent iv injections of atracurium. During the 4 h of anesthesia, the patient's condition was stable with arterial blood pressure, ranging between 90-110 mmHg systolic and 40-50 mmHg diastolic. Heart rate ranged from 80 to 90 bpm. At the end of the procedure, neuromuscular blockade was reversed with atropine 1.2 mg and neostigmine 2.5 mg iv, and the inhaled anesthetics were discontinued. Adequate spontaneous respirations resumed, and the trachea was extubated. The patient was transferred to the recovery room, where his recovery from anesthesia was uneventful. He was discharged after 10 days without evidence of anesthetic complications.

### DISCUSSION

Patients with Lesch-Nyhan syndrome present three types of problems of concern to the anesthesiologist. First, there are the functional disturbances created by

\* Department of Anesthesiology.

† Instructor of Anesthesiology.

Received from the University of Michigan Medical Center, Department of Anesthesiology, Ann Arbor, Michigan 48109. Accepted for publication March 5, 1985.

Address reprint requests to Dr. Larson.

Key words: Anesthesia; pediatrics. Lesch-Nyhan syndrome.