

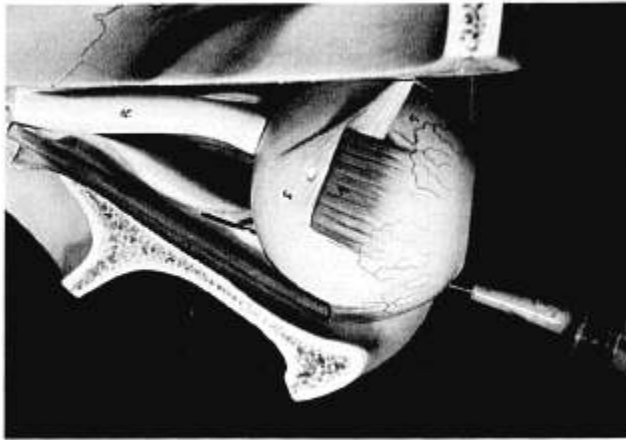FIG. 4. Photograph of model of right orbit as seen from above. The roof of the orbit and the belly of the superior rectus muscle have been removed. 1. Insertion of superior rectus muscle. 5. Insertion of superior oblique muscle. 16. Optic nerve. The needle is seen lying inferior to the globe, its tip within the extraocular muscle cone, medial to the lateral rectus muscle and well away from contact with the optic nerve.

complication. In 1,000 subsequent cases of retrobulbar blockade, this author has used a modified technique and has not had the complication of brain stem anesthesia. Figure 4 illustrates the modified technique; the needle enters the inferior orbit in the sagittal plane of the lateral limbus and remains at all times in that plane. The final position of the needle tip is within the extraocular muscle

cone, medial to the lateral rectus muscle and well away from the optic nerve.

The author acknowledges the assistance of Professors Thomas J. Harrison and Ian C. Roddie.

REFERENCES

1. Backer CL, Tinker JH, Robertson DM, Vlietstra RE: Myocardial reinfarction following local anesthesia for ophthalmic surgery. *Anesth Analg* 59:257-262, 1980
2. Kepes ER, Foldes FF: Transient abducens paralysis following therapeutic nerve blocks of head and neck. *ANESTHESIOLOGY* 38:393-394, 1973
3. Whitehurst L, Harrelson J: Brain stem anesthesia: An unusual complication of stellate ganglion block. *J Bone Joint Surg* 59A: 541-542, 1977
4. Rosenblatt RM, May DR, Barsoumian K: Cardiopulmonary arrest after retrobulbar block. *Am J Ophthalmol* 90:425-427, 1980
5. Nique TA, Bennett CR: Inadvertent brain stem anesthesia following extra-oral trigeminal V₂-V₃ blocks. *Oral Surg* 51:468-470, 1981
6. Smith JL: Retrobulbar marcaine can cause respiratory arrest. *J Clin Neuroophthalmology* 1:171-172, 1981
7. Chang J-L, Gonzalez-Abola E, Larson CE, Lobes L: Brain stem anesthesia following retrobulbar block. *ANESTHESIOLOGY* 61: 789-790, 1984
8. Atkinson WS: Observations on anesthesia for ocular surgery. *Trans Am Acad Ophthalmol Otolaryngol* 60:376-378, 1956
9. Wood-Smith FG, Vickers MD, Stewart HC: *Drugs in anaesthetic practice*, fourth edition. London, Butterworths, 1973, p 465
10. Lombardi G: *Radiology in neuroophthalmology*. Baltimore, Williams and Wilkins, 1967, pp 6-8
11. Griffiths HWC, Gillies J: Total spinal analgesia. *Anaesthesia* 3: 134-145, 1948

Anesthesiology
63:690-692, 1985

Nebulized Anesthesia for Awake Endotracheal Intubation

DENIS L. BOURKE, M.D.,* JEFFREY KATZ, M.B., Ch.B.,† ALAN TONNESON, M.D.‡

Awake endotracheal intubation is frequently the safest approach for patients with problems such as unusual air-

way anatomy, facial or neck trauma, or cardiovascular instability. Several authors have described methods to anesthetize the airway for awake intubation.¹⁻³ Most of these methods require several steps and can be uncomfortable for the patient. We describe a single technique that requires the use of an aerosol of local anesthetic for anesthetizing the entire nasotracheal airway and illustrate its usefulness with a case presentation. Our technique provides complete anesthesia for nasotracheal intubation and is painless, reliable, and simple to perform.

REPORT OF A CASE

A 32-year-old woman was involved in a motor vehicle accident that resulted in an open laceration of the right eye, a right zygomatic fracture, and a left femoral fracture. Cervical spine roentgenograms could not rule out a C-5 fracture. A cervical collar was applied, and the patient was scheduled for emergency surgery. Our preoperative ex-

* Associate Professor of Anesthesiology, Boston University Medical School.

† Assistant Professor of Anesthesiology, University of Texas Medical School at Houston.

‡ Associate Professor of Anesthesiology, University of Texas Medical School at Houston.

Received from the Department of Anesthesiology, Boston University Medical School, Boston, Massachusetts, and the Department of Anesthesiology, University of Texas Medical School at Houston, Houston, Texas. Accepted for publication July 1, 1985.

Address reprint requests to Dr. Bourke: Department of Anesthesiology, University Hospital, 75 East Newton Street, Boston, Massachusetts 02118.

Key words: Anesthetics, local: lidocaine. Intubation, endotracheal: technique.

amination revealed an alert, oriented, obese woman whose height was 160 cm and weight was 102 kg.

We administered glycopyrolate 0.4 mg iv and diazepam 5 mg iv. We then sprayed phenylephrine 0.25% into each nostril. After several minutes the patient could breathe easily through her nose. We then strapped a disposable nebulizer face mask over her mouth and nose. A nebulizer filled with 4 ml of 4% lidocaine and 1 ml of 1% phenylephrine was attached, and 5 l/min O₂ was delivered to the nebulizer; the patient was instructed to breathe through her nose. While the nebulizer solution was being dispensed during the next 5 min, we administered 2.5 mg of diazepam and 100 µg fentanyl iv. The face mask was then removed and several successively larger nasal airways were passed down her left nostril. A fiberoptic bronchoscope (Olympus) facilitated intubation with an 8.5 mm nasotracheal tube, and anesthesia was maintained with nitrous oxide and enflurane. The patient did not cough during either nebulization or intubation of the trachea.

DISCUSSION

This technique can be used whenever an awake endotracheal intubation is required. Moreover, it can be particularly valuable when a cervical collar or vest-halo device limit access to the neck; when suspected neck or other injuries prevent extension of the neck; when landmarks are difficult to identify, as in obese patients or scarred or burned patients; when a superior laryngeal block may cause an infection; or when coughing could be dangerous, as with an open eye injury or with increased intracranial pressure.

We believe several details are important to the success of this technique. The patient should be premedicated with an effective dose of antisialogogue long enough before the procedure to ensure that secretions do not impede the use of a fiberoptic device, should it become necessary. Additionally, the absence of secretions improves contact between the anesthetic and the mucosa. The patient should be sedated either as part of the premedication or intravenously at the time of the procedure. Diazepam is a good choice not only because of its sedative properties but also because it provides an extra margin of safety because it raises the threshold for local-anesthetic-induced seizures.⁴ When a patient's condition permits small doses of iv narcotics are helpful, since topical anesthesia seldom prevents discomfort completely when an endotracheal tube is passed through the nose. Additionally, narcotics help prevent coughing.

Aerosol administration of the topical anesthetic is best accomplished with the patient in the sitting or semisitting position. However, it can be accomplished with the patient supine. The equipment required is available in any respiratory therapy department. Oxygen can be provided by any source that will deliver between 4 and 8 l/min. The oxygen tubing is attached to a disposable aerosol nebulizer,[§] and the nebulizer then is attached to the dis-

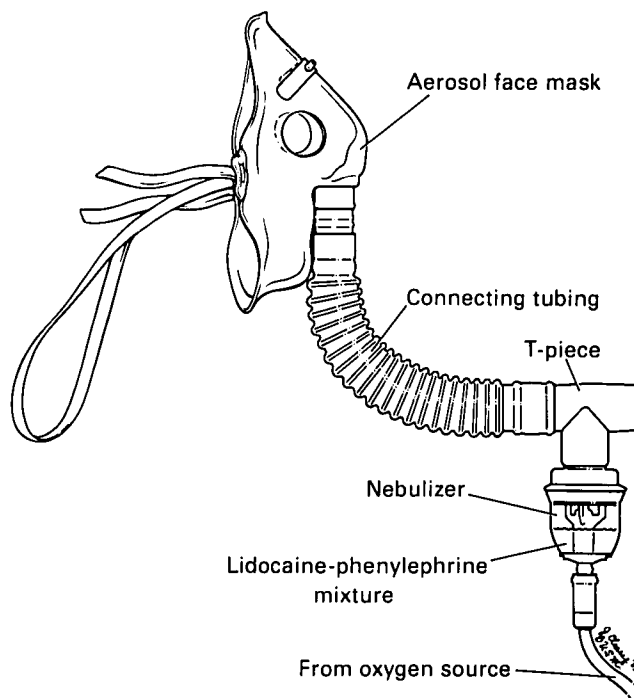


FIG. 1. Diagram of apparatus required for nebulization and delivery of lidocaine-phenylephrine solution. Connecting tubing allows the nebulizer to remain in the required vertical position regardless of the patient's position.

posable aerosol mask[¶] (fig. 1). The patient is instructed to breathe normally, through his nose if possible. Usually, 5 min is sufficient to anesthetize the nasal, pharyngeal, laryngeal, and upper tracheal mucosa.

Typical nebulizers produce droplets that range in size from as small as 1 µm to as large as 20 µm.⁵ The smaller particles (<5 µm) can be carried to the terminal bronchioles, while the larger particles will impact and be deposited on nasal and pharyngeal mucosa. The drug we use is a mixture of 4 ml of 4% lidocaine with 1 ml of 1% phenylephrine, which results in a 3.2% lidocaine and 0.2% phenylephrine aerosol. This mixture is effective in providing both topical anesthesia and shrinking the nasal mucosa.⁶ If necessary, spraying several drops of 0.25% neosynephrine in each nostril before beginning the aerosol treatment will facilitate nasal breathing. Although the total dose of lidocaine is 160 mg, only a portion of it actually is inhaled. Other reports indicate that topical administration results in lower peak plasma levels than iv administration of similar doses.^{7,8} Further, diazepam protects against toxic reactions, and phenylephrine may slow systemic absorption. If the patient will not breathe through the nose, nasal anesthesia can be obtained by inserting

§ Disposable hand-held nebulizer system. Diverse Respiratory Air Products, Inc., San Dimas, California 91773.

¶ Adult aerosol mask. Inspiron Corporation. Roncho Cucamonga, California 91730.

into one nostril cotton-tipped applicators soaked in either the above solution or 4% cocaine. Cocaine provides both the necessary anesthesia and vasoconstriction to facilitate nasotracheal intubation.

Once the aerosol administration is completed, the nostril is dilated by successively inserting well-lubricated soft nasal airways, usually starting with a 6.5 mm OD airway and increasing by 0.5 mm. This procedure tests analgesia, clears secretions, dilates the nasal passage, thus reducing the possibility of the endotracheal tube causing bleeding, and gives a good indication of how large an endotracheal tube can be used. After dilation with the nasal airways, either blind or fiberoptic controlled intubation can be performed in the usual manner.

We have used this technique without incident in more than 70 patients. Anesthesia has been uniformly adequate. We have not observed evidence of systemic toxicity from the lidocaine nor have arterial blood pressure or heart rate changes indicated undesirable systemic effects of the phenylephrine. However, caution should be exercised in patients who have recently eaten, since sedation and topical anesthetization of the airway may obtund protective reflexes.

This method of anesthetizing the airway does not take longer than most other techniques and has several ad-

vantages. The patient does not cough either during the anesthetization or during the intubation, and access to the neck and identification of anatomic structures is not required for successful anesthesia.

REFERENCES

1. Duncan JAT: Intubation of the trachea in the conscious patient. *Br J Anaesth* 49:619-623, 1977
2. Thomas JL: Awake intubation. Indications, techniques and a review of twenty-five patients. *Anaesthesia* 24:28-35, 1969
3. Gotta AW, Sullivan CA: Superior laryngeal nerve block: an aid to intubating the patient with fractured mandible. *J Trauma* 24:83-85, 1984
4. DeJong RH, Bonin JD: Benzodiazepines protect mice from local anesthetic convulsions and deaths. *Anesth Analg* 60:385-389, 1981
5. Allan D: Humidification and mist therapy: An introduction, Humidification and Mist Therapy. Edited by Allan D. Boston, Little, Brown, 1970, pp 511-517
6. Hertigon ML, Cleary JL, Gross JB, Schaffer DW: Is nasal cocaine superior to a lidocaine-phenylephrine mixture for blind nasotracheal intubation? *Anesth Analg* 63:227, 1984
7. Chu SS, Rah KH, Brennan MD, Cohen JL: Plasma concentration of lidocaine after endotracheal spray. *Anesth Analg* 54:438-441, 1981
8. Gal TJ: Airway responses in normal subjects following topical anesthesia with ultrasonic aerosols. *Anesth Analg* 59:123-129, 1980

Anesthesiology
63:692-693, 1985

Fatal Intraoperative Tumor Embolism in a Child with Hepatoblastoma

F. DORMAN, F.F.A.R.C.S.,* E. SUMNER, F.F.A.R.C.S.,† L. SPITZ, Ph.D., F.R.C.S.‡

Despite use of chemotherapy and radiotherapy,¹ complete surgical resection continues to represent important therapy for hepatoblastoma. In one series, survival rate was 69% when complete resection was achieved, compared with a 16% survival when microscopic disease remained following surgery.² The intraoperative mortality rate for major hepatic resection can be as high as 33%,^{3,4} mainly because of excessive hemorrhage. Fatal intraoperative tumor embolism during hepatic surgery in a child has not been reported previously, although its occurrence has been documented during surgery for neph-

roblastoma,⁵ suprarenal carcinoma,⁶ and in an adult with a primary liver tumor.⁷ We describe a fatal pulmonary tumor embolism during an extended left hemihepatectomy for hepatoblastoma in a child.

REPORT OF A CASE

A two-year-old boy weighing 11.5 kg presented with a 2-week history of general malaise and an enormous upper abdominal mass. He was anemic, with a hemoglobin of 7.8 g/dl and a platelet count of 701,000 per mm³. Blood coagulation studies and liver function tests were normal. Serum alpha-fetoprotein was grossly elevated at 110,000 µg/l. A large tumor arising from the left lobe of the liver was demonstrated on ultrasonography, isotope liver scan, and computerized tomography scan. Selective hepatic arteriography confirmed apparent resectability of the tumor and defined the arterial anatomy of the liver. A chest radiograph and computerized tomography scan of the lungs failed to demonstrate any evidence of secondary spread. The anemia was corrected preoperatively, and the child was scheduled for surgery.

Anesthesia was induced with cyclopropane following im atropine with meperidine 0.07 ml·kg⁻¹ premedication. Anesthesia was maintained by inhalation of nitrous oxide, oxygen, and halothane with iv fentanyl following succinylcholine iv and intubation of the trachea.

* Anaesthetic Registrar.

† Consultant Anaesthetist.

‡ Professor of Paediatric Surgery.

Received from the Departments of Anaesthesia and Surgery, Hospital for Sick Children, Great Ormond Street, London, WC1N 3JH, England. Accepted for publication July 1, 1985.

Address reprint requests to Dr. Spitz.

Key words: Anesthesia: pediatric; hepatoblastoma. Complications: embolism.