

in close proximity to the pericardial reflections of the great vessels, which allowed air already present in the perivascular sheaths to enter the pericardium. Although maximum airway pressures used during the procedure were no higher than those used preoperatively (PIP 35 cmH<sub>2</sub>O), these pressures were probably sufficient to cause further air dissection, especially when the right lung was dependent and the left lung retracted.

The tendency toward recurrence after initial relief of air tamponade often makes treatment ultimately unsuccessful. Placement of an anterior pericardial drainage tube under direct vision is the treatment of choice, but maintenance of long-term patency is difficult.<sup>7</sup> Recurrence is frequent because further barotrauma is generated by the underlying lung pathologic features and resultant prolonged ventilatory support.

Tension pneumopericardium occurs in association with pneumothorax, pneumomediastinum, and subcutaneous emphysema after very high airway pressures, and signs of these complications may obscure those of tension pneumopericardium. In our case, there were no excessive airway pressures, and only tension pneumopericardium occurred. Previous cases involved multiple complications and high airway pressures during positive pressure ventilation produced by prolonged occlusion of the open arm of Ayer's t-piece.<sup>2</sup> This directly exposes the airway to the pressures flowing from the anesthesia machine. Because of the absence of a pop-off valve and reservoir bag, continuous vigilance is needed with Ayer's t-piece to avoid inadvertent high airway pressures. Modern anesthesia circuits, such as the Mapleson D system we used, incorporate both pop-off valves and reservoir bags to modulate airway pressures. Although modern systems have markedly reduced the incidence of high airway pressures, prolonged occlusion of the expiratory limb (analogous to the

open arm of Ayer's t-piece) or complete closure of the pop-off valve can still result in very high airway pressures and barotrauma.

This case report illustrates that in infants with lung disease, especially in those with pulmonary interstitial emphysema, intraoperative pneumopericardium with tamponade may develop despite careful control and monitoring of airway pressures. In these patients, tension pneumopericardium as well as pneumothorax must be considered when abrupt intraoperative cardiovascular collapse occurs. Pneumopericardium with tamponade is signaled by bradycardia, cyanosis, hypotension, and distant heart sounds. Although properly used modern anesthesia circuits markedly reduce the possibilities of barotrauma, they do not entirely prevent it in infants with diseased lungs. When modern circuits are used improperly, high airway pressures in any patient may produce tension pneumopericardium along with pneumothorax, pneumomediastinum, or subcutaneous emphysema.

#### REFERENCES

1. Lawson EE, Gould JB, Taesch HW: Neonatal pneumopericardium: Current management. *J Pediatr Surg* 15:181-185, 1980
2. Loftis JW, Susen AF, Marcy JH, Sherman FE: Pneumopericardium in infancy. *Am J Dis Child* 103:93-97, 1962
3. Cummings RG, Wesly RLR, Adams DH, Lowe JE: Pneumopericardium resulting in cardiac tamponade. *Ann Thorac Surg* 37: 511-518, 1984
4. Reppert SM, Ment LR, Todres ID: The treatment of pneumopericardium in the newborn infant. *J Pediatr* 90:115-117, 1977
5. Reed JR, Thomas WP: Hemodynamics of progressive pneumopericardium in the dog. *Am J Vet Res* 45:301-307, 1984
6. Cohen DJ, Baumgart S, Stephenson LW: Pneumopericardium in neonates: Is it PEEP or is it PIP? *Ann Thorac Surg* 35:179-183, 1983
7. Emery RW, Foker J, Thompson TR: Neonatal pneumopericardium: A surgical emergency. *Ann Thorac Surg* 37:128-132, 1984

Anesthesiology  
64:643-644, 1986

## An Alternative Method to Secure an Endotracheal Tube in Infants with Midline Facial Defects

DAVID R. JOBES, M.D.,\* AND SUSAN CRAIG NICOLSON, M.D.†

Small infants with large midline facial defects pose difficulty in securing an endotracheal tube. We describe a method that solved this problem in our patient. We believe it may be useful in similar cases.

\* Associate Professor of Anesthesia, University of Pennsylvania School of Medicine, and Senior Anesthesiologist, The Children's Hospital of Philadelphia.

† Assistant Professor of Anesthesia, University of Pennsylvania School of Medicine, and Assistant Anesthesiologist, The Children's Hospital of Philadelphia.

Received from the Department of Anesthesia and Critical Care,

#### REPORT OF A CASE

The patient was an 11-week-old, 2.6-kg female infant with Wolf-Hirschhorn syndrome (deletion of the short arm of chromosome 4). With her trachea intubated, she was transported from the intensive

The Children's Hospital of Philadelphia, Philadelphia, Pennsylvania. Accepted for publication December 17, 1985.

Address reprint requests to Dr. Nicolson: Department of Anesthesia and Critical Care, Children's Hospital of Philadelphia, 34th Street and Civic Center Boulevard, Philadelphia, Pennsylvania 19104.

Key words: Anesthesia; pediatric. Intubation, endotracheal; technique.

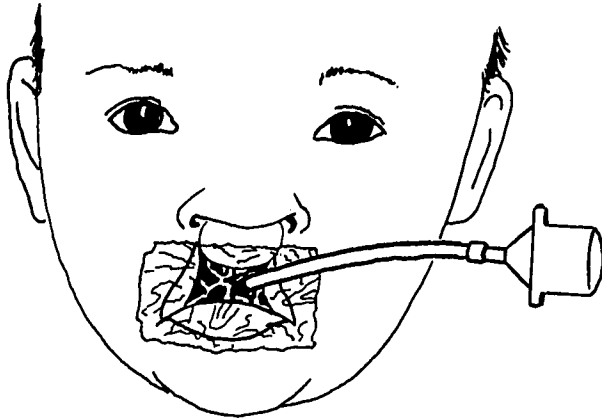


FIG. 1. Triple-thickness plastic wrap passed over an indwelling endotracheal tube to form a mold of the infant's oral-nasal cavities.

care unit for closure of a ventricular septal defect and subclavian flap angioplasty repair of coarctation of the aorta. The infant was dysmorphic, with a prominent nasal bridge, beaked nose, and bilateral cleft lip and palate (fig. 1). Before coming for surgery, the trachea had been intubated many times for cardiorespiratory failure. With the use of conventional means to secure the endotracheal tube, frequent reapplication of tape, attempts to minimize head movement, and arm restraints were required to prevent dislodgement of the tube. Despite all precautions, accidental extubation occurred twice within 72 hours. Anesthesia was induced with pancuronium, 0.2 mg/kg, and fentanyl 1, 50  $\mu$ g/kg iv. The trachea was reintubated with a clean 3.0 oral uncuffed endotracheal tube. A hole, the diameter of the endotracheal tube connector, was created in the center of a 5"  $\times$  5" piece of triple-thickness standard kitchen plastic wrap. After sliding the plastic wrap over the indwelling tube, the plastic wrap was advanced to the posterior aspect

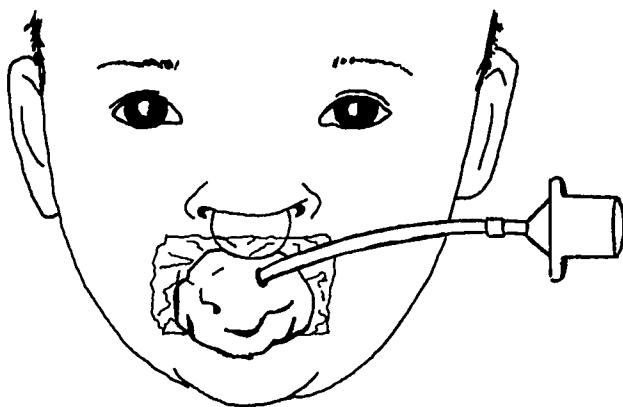


FIG. 2. Endotracheal tube encased in a soft foam case, with rim of plastic wrap.

of the tongue. With the use of a blunt instrument, the wrap was pushed into the crevices of the oral and nasal cavities, leaving a rim of wrap external to the mouth (fig. 1). Liquid silicone foam (Dow Corning Q 7-4290, Prosthetic Foam<sup>®</sup>) was directed into the plastic wrap mold. Over the next several minutes the foam solidified, resulting in the endotracheal tube being encased in a soft foam cast of the oral-nasal cavity (fig. 2). Benzoin was applied to the tube and skin. The tube was taped over the foam in the conventional fashion. The trachea was extubated, removing the foam and tube in block, by lifting the external portion of the plastic wrap.

## DISCUSSION

This infant was critically ill with an abnormal facial configuration. The preoperative experience with endotracheal intubation proved that conventional taping methods to secure the airway resulted in accidental extubation. Recognizing that the infant would not tolerate accidental extubation in the perioperative period and that intubation would be likely for several days after surgery, we sought a more reliable means to secure the endotracheal tube. An alternative method of taping, placing tape around the tube and then circumferentially around the head, was considered. This was felt to be unacceptable because the placement of ice bags for head-surface cooling was likely to result in the head becoming wet and the tape loose. The urologists at our institution use liquid silicone foam to create a dressing to cover the penis after hypospadias repair. This dressing is durable, withstands moisture, is not irritating to the skin or mucous membrane, and is easily removed. These desirable properties of the substance prompted our attempting to use it to support the endotracheal tube. Plastic wrap was used to create a mold of the oral-nasal cavity and to prevent more distal migration of the foam when it was in the liquid state. In its final form, the foam, in addition to supporting the tube, provided a smooth surface to which tape could be applied. As the foam filled the oral cavity, secretions were blocked from reaching the tape. The endotracheal tube was secure intraoperatively and postoperatively. The intensive care nurses and the infant's mother found it more acceptable than the preoperative configuration. With extubation of the trachea, the foam was removed by lifting of the external plastic wrap. No evidence of irritation was noted.

Having successfully used the technique in only a single infant, we can only suggest that it be considered for use where conventional techniques are proven inadequate, as in the described case.