

Anesthesiology  
64:823-826, 1986

## Guided Orotracheal Intubation in the Operating Room Using a Lighted Stylet: A Comparison with Direct Laryngoscopic Technique

DAVID G. ELLIS, M.D.,\* ANDREW JAKYMEC, M.D.,† RICHARD M. KAPLAN, M.S.,‡  
RONALD D. STEWART, M.D.,§ JUDITH A. FREEMAN, M.D.,¶  
ACHIEL BLEYAERT, M.D.,\*\* PAUL E. BERKEBILE, M.D.††

Orotracheal intubation using transillumination of neck tissues to guide tube placement was mentioned first in the literature in 1959.<sup>1</sup> Most reports of this method are anecdotal,<sup>2-4</sup> and only one report documents success rates and complications in a group of patients.<sup>5</sup> No study has yet documented the success of this method in the setting of the operating room, and none compares this procedure with conventional, direct-vision laryngoscopy for oro-tracheal intubation. The purpose of this randomized, prospective study was to compare the success and complication rates of oro-tracheal intubation performed by direct laryngoscopic and lighted stylet methods in the controlled setting of the operating room.

### PATIENTS AND METHODS

The study included ASA Class I-III patients between the ages of 18 and 65 who were scheduled for elective operative procedures. Those undergoing major cardiovascular, gastrointestinal, neurosurgical, or transplantation surgery were excluded. The study was approved by the Institutional Review Board for Biomedical Research of the University of Pittsburgh.

Patients were visited the evening prior to surgery, when the nature of the study was explained and a consent form was signed. All patients were told that they would be interviewed 24 h after their surgery but the content of the interview was not disclosed.

Immediately prior to intubation, a standard randomization chart was used to determine the technique (lighted stylet *vs.* laryngoscope) and the intubator (anesthesiologist *vs.* emergency physician). An automatic blood pressure recording device (Dinamap<sup>™</sup>, Critikon Corp., Tampa, FL) in a "stat" mode (q 20 s) was used to record blood pressure and was synchronized to removal of the mask just prior to intubation. A standard oscilloscopic monitor registered heart rate and ECG. Induction was standardized for all patients. Patients were oxygenated and then given a priming dose of a nondepolarizing muscle relaxant. Induction was accomplished using sodium pentothal (four in the laryngoscopic group received diazepam) and a paralyzing dose of succinylcholine (93 patients) or pancuronium (seven patients).

Three attempts at intubation were permitted and the patient was reoxygenated by mask between each attempt. Patients were included only if intubations were completed by one intubator using only one method. Laryngoscopic intubation was accomplished with a #3 MacIntosh blade, a stylet in the endotracheal tube, and with the patient's head in the "sniffing position." Endotracheal tubes in both groups were of one make (American<sup>™</sup>, Mallinckrodt, Inc., Argyle, NY) and a jelly lubricant (Surgilube<sup>™</sup>, E. Fougera & Company, Melville, NY) was applied in all cases.

Lighted stylet intubations were performed using the Tube-Stat<sup>®</sup> intubation stylet (Concept Corp., Clearwater, FL) with the endotracheal tube cut to a length of 25 cm (fig. 1). In the lighted-stylet group, the patient's head was maintained in a neutral or slightly elevated head position (fig. 2). The tongue was then grasped and pulled forward out of the mouth. At the time of intubation with the lighted stylet, overhead room lights were turned down, but indirect lighting from hallways, scrubrooms, and x-ray viewboxes was permitted and maintained illumination sufficient to observe the patient and carry out procedures. The stylet and tube (bent as in figs. 1 and 2) were inserted

\* Clinical Faculty, Affiliated Residency in Emergency Medicine, Center for Emergency Medicine.

† Assistant Professor of Anesthesiology/Critical Care Medicine, University of Pittsburgh School of Medicine.

‡ Research Coordinator, Center for Emergency Medicine.

§ Associate Professor of Surgery and Assistant Professor of Anesthesiology/Critical Care Medicine, University of Pittsburgh School of Medicine.

¶ Assistant Professor of Anesthesiology/Critical Care Medicine, University of Pittsburgh School of Medicine.

\*\* Professor of Anesthesiology/Critical Care Medicine, University of Pittsburgh School of Medicine.

†† Clinical Associate Professor of Anesthesiology/Critical Care Medicine, University of Pittsburgh School of Medicine.

Received from The Department of Anesthesiology, Presbyterian-University Hospital, The University of Pittsburgh School of Medicine and The Center for Emergency Medicine, Pittsburgh, Pennsylvania. Accepted for publication January 21, 1986.

Address reprint requests to Dr. Stewart: Center for Emergency Medicine, 190 Lothrop Street, Pittsburgh, Pennsylvania 15213.

Key words: Anesthetic techniques: endotracheal; lighted stylet; oro-tracheal. Intubation: complications; sore throat; hoarseness; technique.

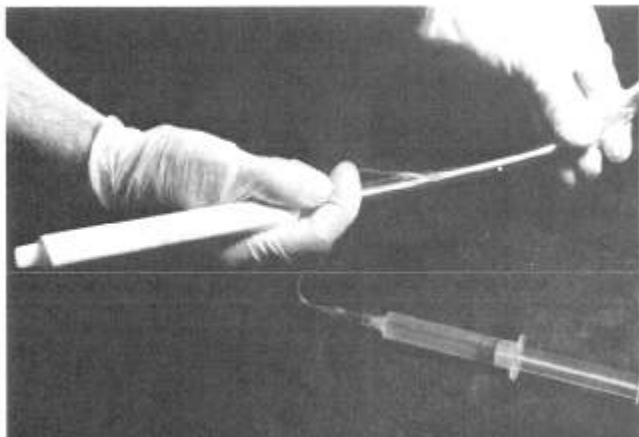


FIG. 1. The Tube-Stat<sup>®</sup> intubation stylet, after lubrication, is slid into a 25 cm endotracheal tube and bent to slightly less than 90°.

into the oropharynx and the transilluminated light was visualized in the neck (fig. 2). Once positioned in the trachea, as indicated by the bright midline glow, the tube was slid off the stylet and into position in the manner previously described,<sup>5</sup> and the overhead lights were turned on.

One independent nonphysician observer was responsible for recording the following: 1) the duration of each intubation attempt (measured from time of removal of ventilation mask to connection to ventilation tubing); 2) the mechanics and ease of intubation; 3) any evidence of trauma to the teeth or soft tissues; 4) any patient motor response, such as bucking following induction of anesthesia and during intubation; and 5) the presence of any arrhythmias noted by observing the ECG monitor.

Patients were observed in the recovery room by an anesthesiologist who was unaware of the intubation technique used. Patients were extubated following standard procedure and the presence of any complications was noted. At the interview carried out approximately 24 h after the completion of the surgical procedure, patients were asked general, then specific, questions about the presence of throat discomfort,odynophagia, dysphonia, bleeding, or cough. The presence or absence of these problems was noted, but the degree of the patient's discomfort was not measured. Patients who were unable to respond to questions or who had had a nasogastric tube placed were not included in the interview portion of the study. At the time of the interview, neither interviewer nor patient knew which procedure had been used for intubation.

The incidence of side effects was compared using the statistical test of proportions and a Student's *t* test of probability applied for analysis of the success and time of intubation attempts. A *P* value of <0.05 was accepted as denoting statistical significance.

## RESULTS

One hundred and two patients were randomized and intubated using either technique. One patient was excluded from each group because the second attempt at intubation was carried out by a different intubator. The two patient groups were similar as to ASA status, age, gender, weight, body surface area, height-to-weight ratio, surgical procedure, and duration of intubation.

All patients in both groups were successfully intubated.

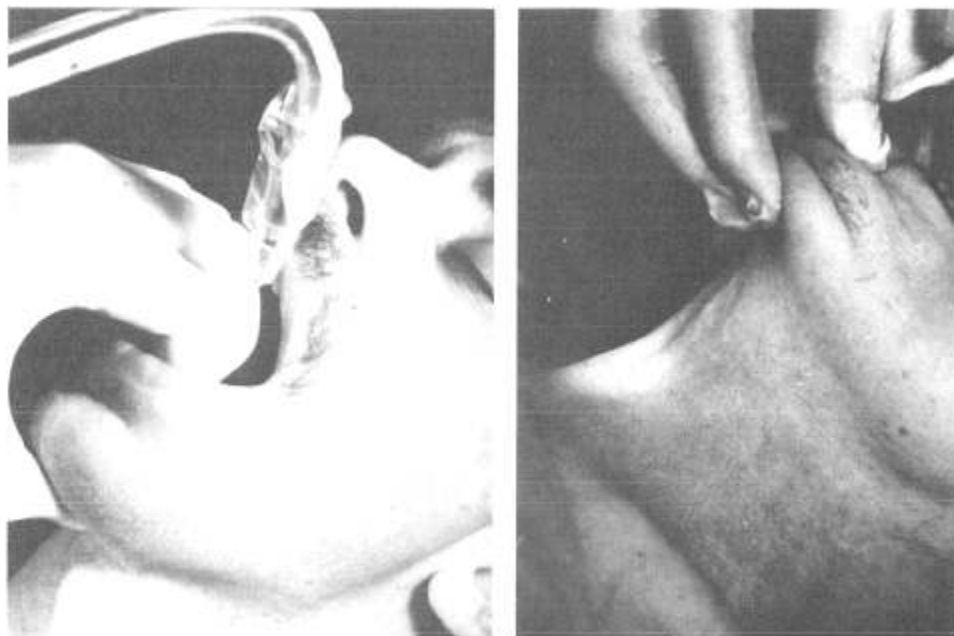


FIG. 2. The patient's tongue (or tongue and jaw) is drawn gently forward (*left*) and the stylet and tube is advanced until a circumscribed light is seen midline, at the level of the laryngeal prominence (*right*).

In the lighted-stylet (LS) group, 36 of 50 (72%) were intubated on the first attempt, whereas 11 (22%) patients required a second attempt, and three (6%) required a third attempt. In the laryngoscopic intubation group, only one patient (2%) was not intubated on the first attempt and required a second.

The time required for intubations ranged from 11–72 s in the lighted-stylet group and 15–57 seconds in the laryngoscopic group, with an average of  $37 \pm 13$  and  $33 \pm 9$  s, respectively. This did not reach statistical significance over the course of the study ( $P > 0.05$ ).

Eleven patients could not be interviewed because of an inability to cooperate at the time of interview or were excluded because of other manipulation of the nasopharynx or oropharynx (e.g., nasogastric tube, reintubation).

Of the remaining 89 patients, 18 (20%) complained of sore throat on direct questioning. Of these, ten were in the group of 44 (23%) lighted-stylet patients and 8 (18%) in the 45 patients intubated by direct laryngoscopy ( $P > 0.05$ ). Twenty-four (37%) and these 89 patients complained of hoarseness on direct questioning, 13 in the lighted-stylet group (30%) and 11 (24%) in the laryngoscopic group ( $P > 0.05$ ).

Seven of the 50 patients (14%) intubated with the lighted stylet had an arrhythmia during intubation while in only one of the laryngoscopic cases (2%) was an arrhythmia noted. All arrhythmias were short-lived and were not considered a threat to the patient. The duration of the intubation attempt did not appear to be a factor in the type or frequency of arrhythmias seen when the lighted stylet was used.

Observations for moving, coughing, or bucking during intubation were recorded in 81 patients. Thirty-nine lighted-stylet records had this information provided and 42 in the laryngoscopic group. Of the 39 lighted-stylet patients, ten (26%) were reported to have moved, coughed, or bucked, while 17 (41%) of the 42 laryngoscopic patients were reported to have done so ( $P < 0.05$ ).

No major complications and no soft tissue or dental trauma were seen in either group.

## DISCUSSION

While the technique of guided-lighted-stylet ("lightwand") orotracheal intubation gradually developed in the 1950s,<sup>1,6,7</sup> no prospective evaluation of this technique has yet been reported. With the exception of our small field trial<sup>5</sup> and reports of individual cases,<sup>2-4</sup> the technique has remained relatively obscure and has not been closely studied or compared with conventional methods of orotracheal intubation.

Our study demonstrates that this can be an effective and safe method of orotracheal intubation that under conditions of this study carries no significantly increased

incidence of major or minor complications. All patients were successfully intubated with the stylet, and no significantly greater time was required when compared with intubation using the laryngoscope. While more patients in the lighted-stylet group needed a second or third attempt at tube placement, the time taken for intubation improved steadily throughout the study, probably reflecting the increased skill of the intubators. The study used only five physicians: three anesthesiologists (all attending faculty) and two emergency physicians (one resident and one attending faculty). Although the latter were initially more experienced and successful with the technique of lighted-stylet intubation, the skill of each physician improved throughout the study period. The skill level of the intubators appeared to us to be related to their participation in a practical lab session in which cadavers were used to demonstrate the technique.

Descriptions of the procedure provided to the patient in the preoperative interview and consent form did not appear to bias the patient toward greater awareness of potential throat discomfort. Our incidence of postoperative sore throat following laryngoscopic intubation was within the reported ranges of 5–50%.<sup>8-11</sup> In our previous clinical trial of this technique in the rather adverse emergency medical service field environment, lighted-stylet intubation appeared effective and without an increased complication rate.<sup>5</sup>

A recent report describes the disconnection of the bulb from the stylet with consequent loss into the trachea.<sup>12</sup> We experienced a similar case 2 yr ago and were able to avoid the problem by coating all our stylets with a shrinkable plastic tubing that encases the stylet from the distal end of the bulb and holds it solidly in place. The manufacturer has redesigned this surgical light as a stylet, and has encased the bulb and wire in a firm plastic coating (Tube-Stat<sup>®</sup>, Concept Corp., Clearwater, FL). We now use only this new device for all lighted-stylet intubations. Further versions of the stylet are planned, including one designed specifically for nasotracheal intubation.

Although we did not assess it directly, the fact that most of our lighted-stylet intubations were performed without having to flex the patient's neck or extend the patient's head presents the possibility that this technique might be preferable in cases of suspected or known cervical spine injury.<sup>4</sup> A comparison of changes in intracranial pressure and cardiovascular parameters during both laryngoscopic and lighted-stylet intubation would require further study with appropriate monitoring.

In short, our study shows that orotracheal intubation using guided placement by transillumination of the neck with a lighted stylet can be easily accomplished in anesthetized, paralyzed patients. No major complications were seen in these patients and no soft tissue or dental trauma was evident with either technique. In the groups studied

there was no difference in the trauma caused by either procedure, as reflected by a similar incidence of sore throat or hoarseness. Further study should be done to document movement of the cervical spine as well as changes in cardiovascular and intracranial pressure measurements occurring during both techniques.

The authors gratefully acknowledge the participation of the operating room staff of Presbyterian-University hospital and the work of their medical student interviewers, Diane Deely and Walt Schradling. The Concept Corporation, Clearwater, Florida, supplied the Tube-Stat<sup>®</sup> lighted stylets.

#### REFERENCES

1. Yamamura H, Yamamoto T, Kamiyama M: Device for blind nasal intubation. *ANESTHESIOLOGY* 20:221-222, 1959
2. Foster CA: An aid to blind nasal intubation in children (letter). *Anaesthesia* 32:1038, 1977
3. Ducrow M: Throwing light on blind intubation. *Anaesthesia* 33: 827-829, 1978

4. Rayburn RL: "Light wand" intubation (letter). *Anaesthesia* 34: 677-678, 1979
5. Vollmer TP, Stewart RD, Paris PM, Ellis DG, Berkebile PE: Use of the lighted stylet for guided orotracheal intubation in the prehospital setting. *Ann Emerg Med* 14:324-328, 1985
6. MacIntosh R, Richards H: Illuminated introducer for endotracheal tubes. *Anaesthesia* 12:223-225, 1957
7. Berman RA: Lighted stylet. *ANESTHESIOLOGY* 20:382-383, 1959
8. Hartsell CJ, Stephen CR: Incidence of sore throat following endotracheal intubation. *Can Anaesth Soc J* 11:307-312, 1964
9. Wolfson B: Mino: laryngeal sequelae of endotracheal intubation. *Br J Anaesth* 30:326-332, 1958
10. Stengvist O, Nilsson K: Postoperative sore throat related to tracheal tube cuff design. *Can Anaesth Soc J* 29:384-386, 1982
11. Loeser EA, Kaminsky A, Diaz A, Stanley TH, Pace NL: The influence of endotracheal tube cuff design and cuff lubrication on postoperative sore throat. *ANESTHESIOLOGY* 58:376-379, 1983
12. Stone DJ, Stirt JA, Kaplan MJ, McLean WC: A complication of lightwand-guided nasotracheal intubation. *ANESTHESIOLOGY* 61:780-781, 1984

Anesthesiology  
64:826-828, 1986

## Transesophageal Echocardiographic Observations in a Patient Undergoing Closed-chest Massage

FIONA M. CLEMENTS, M.D.,\* NORBERT P. DE BRUIJN, M.D.,† AND JOSEPH A. KISSLO, M.D.‡

#### REPORT OF A CASE

The mechanism by which chest compression generates forward blood flow has not been clarified. Some authors believe that ventricular compression with normal valvular competence is responsible,<sup>1</sup> and others believe that only a generalized increase in intrathoracic pressure is necessary, with the heart acting merely as a passive conduit.<sup>2,3</sup> A few cineangiographic<sup>4</sup> and echocardiographic<sup>5</sup> studies of human subjects undergoing cardiopulmonary resuscitation (CPR) generally support the belief that the mitral valve does not move in response to chest compression; quantitative analysis of wall motion has not been described.

We report the echocardiographic and hemodynamic findings using transesophageal 2-D echocardiography (TEE) in a patient undergoing CPR. As part of an ongoing investigation of TEE as an intraoperative monitor of myocardial function, this patient gave informed consent for the use of TEE during surgery for coronary artery bypass grafting (CABG). Prior to surgery, a Diasonics<sup>®</sup> echoscope incorporating a 3.5 MHz phased-array transducer was positioned in the esophagus immediately posterior to the left ventricle (LV) to provide a short-axis view of the LV at the mitral valve level. At several stages of the operation images were recorded on videotape and analyzed later for short-axis fractional area change (FAC) and segmental wall motion, using a center of mass model for wall motion analysis with the Franklin Quantic 1200<sup>®</sup> computer. This analysis corrects for translational movement of the heart by superimposing the cavitory centers of mass in end-diastolic and end-systolic frames. The TEE transducer provided good quality, high-resolution images of the LV endocardial outline and mitral valve motion while CPR was completely unimpeded. Concomitant systemic and pulmonary arterial pressures and electrocardiogram were continuously recorded on a strip chart at a paper speed of 5 mm/s during CPR.

The patient, a 71-yr-old man with a 15-yr history of angina pectoris, had suffered three previous myocardial infarctions. Resting ejection fraction by mutigated radionuclide angiography was 31% and by cardiac catheterization, 26%. He was considered New York Heart Association (NYHA) angina Class IV. There was generalized, moderate hypokinesia of the LV. The mitral valve appeared normal and competent. After uneventful induction of anesthesia and a stable course before cardiopulmonary bypass, the patient underwent saphenous vein grafting to the left anterior descending, circumflex marginal, and right coronary

\* Assistant Professor of Anesthesia.

† Assistant Professor of Anesthesia and Surgery.

‡ Associate Professor of Medicine.

Received from the Department of Anesthesiology, Division of Cardiac Anesthesiology and the Department of Internal Medicine, Division of Cardiology, Duke University Medical Center, Durham, North Carolina. Accepted for publication January 23, 1986. Supported in part by USPHS Grants HL-12715, CA-3-7586, HL-07063, and GM-30820.

Address reprint requests to Dr. de Bruijn: Department of Anesthesiology, Box 3075, Duke University Medical Center, Durham, NC 27710.

Key words: Heart: massage. Monitoring: transesophageal echocardiography.