

## LABORATORY REPORTS

Anesthesiology  
65:418-421, 1986

# Validation of Quantitative Intraoperative Transesophageal Echocardiography

Steven N. Konstadt, M.D.,\* Daniel Thys, M.D.,† Bruce P. Mindich, M.D.,‡  
Joel A. Kaplan, M.D.,§ Martin Goldman, M.D.¶

Transesophageal echocardiography (TEE) is a new monitoring technique that images the heart and provides information on regional wall motion and left ventricular filling. However, despite its potential for inaccuracy due to its retrocardiac position and angulation, TEE has not been validated by another imaging technique. Using direct on-heart echocardiography (OHE) as a standard, the authors evaluated the ability of TEE to measure accurately left ventricular end-diastolic area ( $ED_a$ ), end-systolic area ( $ES_a$ ), and ejection fraction area ( $EF_a$ ). Ten patients with coronary artery disease without evidence of valvular dysfunction undergoing myocardial revascularization were studied. A Dasonics® 3.5 MHz two-dimensional TEE probe was introduced into each patient's esophagus and positioned to obtain a view equivalent to the parasternal short-axis projection. A similar view was obtained by OHE using a sterilely prepared 3 MHz ATL® probe placed on either the pericardium or epicardium. In each patient, immediately prior to and after pericardiotomy, both transesophageal and on-heart short-axis views at the level of the papillary muscles were obtained. Using a dedicated Dasonics® computer echoanalyzer,  $ED_a$  and  $ES_a$  from four consecutive cardiac cycles were outlined with a light pen and averaged.  $EF_a$  was calculated by the formula  $EF_a = (ED_a - ES_a)/ED_a$ . Seventeen comparable transesophageal and on-heart echocardiograms were obtained.  $ES_a$  by TEE correlated well with  $ES_a$  by OHE ( $15.13 \pm 9.62 \text{ cm}^2$  vs.  $14.92 \pm 10.53 \text{ cm}^2$ ;  $r = 0.94$ ). Similar results were obtained for  $ED_a$  ( $27.75 \pm 9.88 \text{ cm}^2$  vs.  $30.40 \pm 13.99 \text{ cm}^2$ ;  $r = 0.88$ ) and  $EF_a$  ( $0.49 \pm 0.17$  vs.  $0.54 \pm 0.13$ ;  $r = 0.92$ ). TEE can accurately assess left ventricular filling and ejection. (Key words: Heart: echocardiography, ventricular performance. Measurement techniques: transesophageal echocardiography. Monitoring: echocardiography.)

PRESENT METHODS OF intraoperative cardiac monitoring (hemodynamic and electrocardiographic) are indirect and potentially inaccurate. Two-dimensional transesophageal echocardiography (TEE) is a monitoring technique that may be capable of direct, continuous intraoperative assessment of left ventricular function. Although several centers have reported TEE-derived measurements of myocardial function, it has never been demonstrated that the results obtained with TEE correlate with other echocardiographic, radiographic, or nuclear techniques.<sup>1,2</sup>

\* Assistant Professor of Anesthesiology.

† Associate Professor of Anesthesiology.

‡ Associate Professor of Surgery.

§ Professor and Chairman of Anesthesiology.

¶ Assistant Professor of Medicine.

Received from The Departments of Anesthesiology, Medicine, and Surgery, The Mount Sinai Medical Center, One Gustave L. Levy Place, New York, New York 10029. Accepted for publication April 21, 1986.

Address reprint requests to Dr. Konstadt.

Because TEE is positioned blindly and views the heart from a retrocardiac position, with a different orientation and possibly a more oblique angulation than routine echocardiography, measurements derived by the TEE method may be inaccurate. In contrast, ejection fraction area ( $EF_a$ ) determined by direct on-heart echocardiography (OHE) has previously been shown to correlate well ( $r = .85$ ) with ventriculographic data.<sup>3</sup> The purpose of this study was to obtain TEE and OHE views under identical hemodynamic conditions to determine if TEE is an accurate monitoring tool in the assessment of end-diastolic area ( $ED_a$ ), end-systolic area ( $ES_a$ ), and  $EF_a$ .

### Methods

Ten patients with coronary artery disease undergoing elective myocardial revascularization of two to five vessels were studied. Written, informed consent was obtained from each patient, and the protocol was approved by the Mount Sinai Hospital Research Administration Committee. Five patients had a prior history of myocardial infarction, and two had signs and symptoms of left ventricular failure. Eight patients were receiving nitrates; six beta-adrenergic blocking drugs; seven slow channel calcium entry blocking drugs; and one was receiving digoxin. Patients with a history of laryngeal or esophageal disease were excluded from the study, as were patients with coagulation abnormalities. Patients with a history of severe hepatic failure were also excluded because of the risk of occult esophageal varices.

Patients were premedicated with lorazepam 1-2 mg orally the evening prior to surgery, and morphine 0.15 mg/kg and scopolamine 0.005 mg/kg intramuscularly 1 h prior to surgery. All cardiac medications were continued until the time of surgery.

On arrival in the operating room, peripheral venous, radial arterial, and thermodilution pulmonary arterial catheters were inserted. Electrocardiographic leads II and  $V_5$  were also monitored.

Anesthesia was induced with fentanyl 100  $\mu\text{g}/\text{kg}$ , and pancuronium 0.025-0.1 mg/kg and/or metocurine 0.1-0.4 mg/kg provided muscle relaxation. Ventilation with 100% oxygen was controlled to maintain normocarbica. Prior to sternotomy, an additional 15  $\mu\text{g}/\text{kg}$  of fentanyl

was administered. In three patients, intravenous nitroglycerin was infused for blood pressure control at a constant infusion rate throughout the study period.

After endotracheal intubation, a 3.5 MHz phased-array two-dimensional transesophageal echocardiographic probe (Diasonics®, Milpitas, CA) was introduced into the patient's esophagus. The probe was attached to an ultrasonograph (Diasonics® 3400 R). On-heart echocardiograms were obtained using a sterilely prepared 3 MHz probe (ATL®) placed directly on the heart. Immediately prior to and after pericardiectomy, consecutive transesophageal and on-heart short-axis views at the level of the papillary muscles were sequentially obtained, maintaining the maximal spherical ventricular view. In addition to using identical landmarks for each pair of echocardiograms, *i.e.*, spherical midpapillary muscle view, an echocardiographer was present to verify that the level of the cross-section and degree of angulation of the two views were as close as possible during the recording period. Each pair of echocardiograms (TEE and OHE) took less than 2 min to record on videotape for later analysis. The hemodynamic parameters during each pair of echocardiograms were recorded and were constant.

Using an electronic pen and activated grid system on a Diasonics® Cardio Revue center that was calibrated for each recording, ED<sub>a</sub> and ES<sub>a</sub> from four consecutive cardiac cycles were traced by outlining the endocardial image with exclusion of the papillary muscles. A single blinded observer, unaware of the pairings, traced all of the images. Interobserver variability was assessed by comparing measurements of EF<sub>a</sub> in eight random recordings blindly and independently analyzed by a cardiologist echocardiographer (M.G.) to those obtained by an anesthesiologist (S.K.).

EF<sub>a</sub> was calculated by the formula:  $EF_a = (ED_a - ES_a) / ED_a$ . The data available for analysis were ED<sub>a</sub>, ES<sub>a</sub>, and EF<sub>a</sub> by both OHE and TEE. To test the validity of transesophageal measurements, ED<sub>a</sub>, ES<sub>a</sub>, and EF<sub>a</sub> obtained by TEE were compared with the corresponding OHE-derived values. The data obtained by two different methods were correlated by linear regression analysis and the standard error of the estimate (SEE) was calculated. The data were also compared by analysis of the distribution of the differences between the two techniques. The mean and SD of the difference were calculated. To evaluate the adequacy of the sample size, a power analysis was performed. It was determined that 17 observations were statistically adequate to allow detection of a difference of three-fourths of an SD with a power of 0.8 and a level of significance of 0.05.<sup>4</sup>

### Results

The transesophageal echocardiographic probe was easily positioned in each patient. Of the 20 possible data

TABLE 1. Hemodynamics at the Time of Echocardiography

	Prepericardiectomy	Postpericardiectomy
Heart rate (beats/min)	63 ± 11	61 ± 8
Systolic pressure (mmHg)	127 ± 16	125 ± 16
Diastolic pressure (mmHg)	66 ± 5	61 ± 6
MAP (mmHg)	86 ± 7	82 ± 10
PAP (mmHg)	17 ± 4	16 ± 4
PCWP (mmHg)	10 ± 3	12 ± 5
CO (l/min)	4.35 ± 1.0	4.49 ± 0.8

HR = heart rate; MAP = mean arterial pressure; PAP = mean pulmonary artery pressure; PCWP = pulmonary capillary wedge pressure; CO = cardiac output.

collection points, 17 comparable TEE and OHE were obtained. Three data points had to be excluded from the study; one because the endocardium was difficult to define on the OHE, a second due to acute myocardial ischemia during the echocardiogram, and a third because of a recording failure. The hemodynamics at the time of the echocardiograms are presented in table 1 as the mean ± 1 SD.

Throughout a wide range, ES<sub>a</sub>s as measured by TEE correlated closely with those values obtained by OHE ( $15.13 \pm 9.62 \text{ cm}^2$  vs.  $14.92 \pm 10.53 \text{ cm}^2$ ;  $r = 0.94$ ;  $P < 0.001$ ) (fig. 1). There was a mean difference between the TEE- and OHE-derived ES<sub>a</sub> of  $0.21 \text{ cm}^2 \pm 3.53 \text{ cm}^2$ , and thus TEE tended minimally to overestimate the ES<sub>a</sub>.

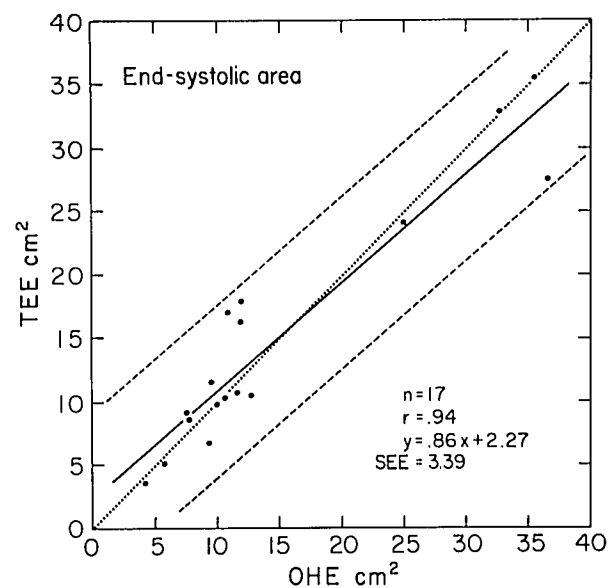


FIG. 1. End-systolic area measured by transesophageal echocardiography (TEE) plotted vs. values obtained by on-heart echocardiography (OHE). In this figure and figures 2-4, the solid line represents the slope derived by correlation coefficient analysis, and the dashed lines represent two standard errors of the estimate above and below the slope. The line of identity is represented by a dotted line.

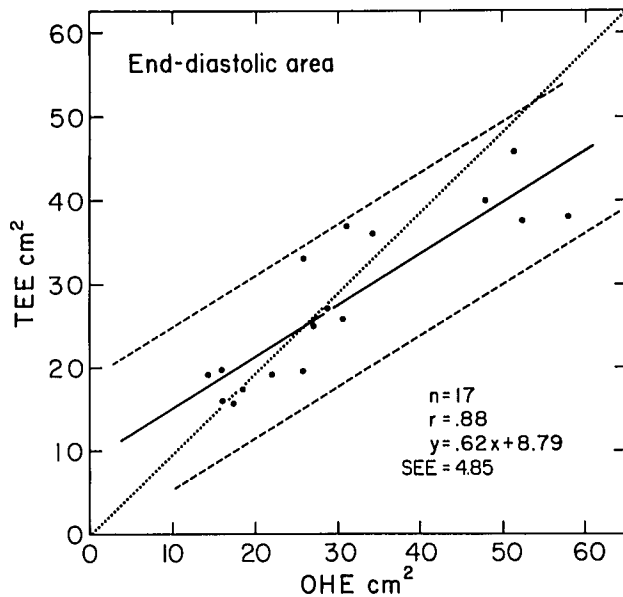


FIG. 2. End-diastolic area measured by transesophageal echocardiography (TEE) plotted against end-diastolic area measured by on-heart echocardiography (OHE) (see fig. 1 legend).

The comparison of the two techniques could detect a difference of at least  $2.65 \text{ cm}^2$ .

$\text{ED}_a$  measurements also closely correlated ( $27.75 \pm 9.88 \text{ cm}^2$  vs.  $30.40 \pm 13.99 \text{ cm}^2$ ;  $r = 0.88$ ;  $P < 0.001$ ) (fig. 2) between the two techniques. The mean difference between TEE and OHE in the determination of  $\text{ED}_a$  was  $-2.65 \text{ cm}^2 \pm 7.0 \text{ cm}^2$ . Therefore, in this patient population TEE tended, in clinically insignificant fashion, to

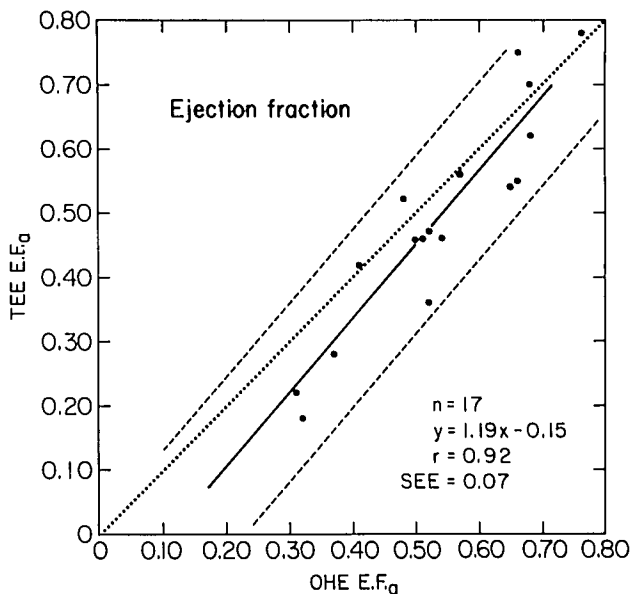


FIG. 3. Ejection fraction area ( $\text{EF}_a$ ) calculated by transesophageal echocardiography (TEE) plotted against ejection fraction area measured by on-heart echocardiography (OHE) (see fig. 1 legend).

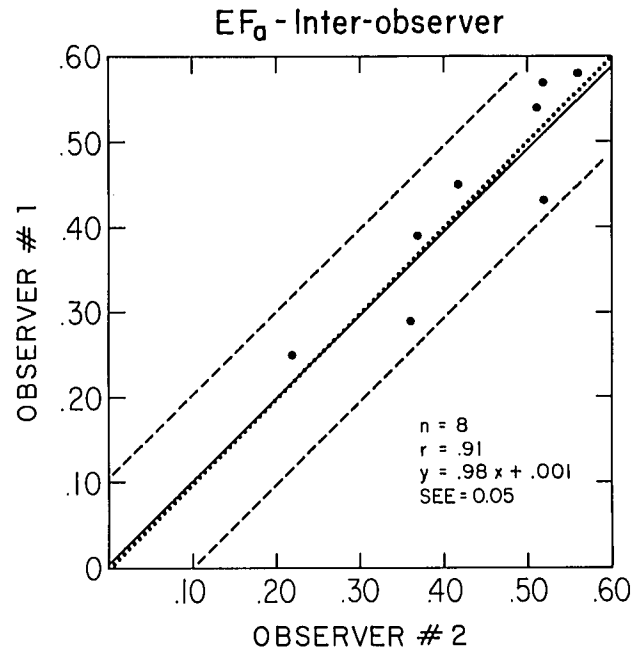


FIG. 4. A plot of ejection fraction area obtained by observer no. 1 vs. observer no. 2 (see fig. 1 legend).

underestimate the  $\text{ED}_a$ . Examination of the linear regression line in comparison with the line of identity shows that this underestimation occurs at the larger  $\text{ED}_a$ s. These 17 observations allow detection of a difference of at least  $5.26 \text{ cm}^2$ .

Using the measurements of  $\text{ED}_a$  and  $\text{ES}_a$ , the  $\text{EF}_a$  was calculated. Ejection fractions derived by TEE correlated well with those obtained with OHE ( $0.49 \pm 0.17$  vs.  $0.54 \pm 0.13$ ;  $r = 0.92$ ;  $P < 0.001$ ) (fig. 3). The mean difference between TEE and OHE in the calculation of  $\text{EF}_a$  was  $-0.05 \pm 0.07$ . Therefore, although TEE minimally underestimated the  $\text{EF}_a$ , the difference is clinically insignificant. Examination of the linear regression line and the line of identity shows that TEE underestimates the low  $\text{EF}_a$ s and overestimates the high  $\text{EF}_a$ s. The 17 observations allow detection of a difference of at least 0.05. This difference is of minimal significance for either clinical or research purposes.

Independent calculation of TEE and OHE  $\text{EF}_a$  blindly performed by a cardiologist (M.G.) and an anesthesiologist (S.K.) showed a close correlation between the two observers ( $0.44 \pm 0.12$  vs.  $0.44 \pm 0.11$ ;  $r = 0.91$ ;  $P < 0.002$ ) (fig. 4). The mean difference in the calculation of  $\text{EF}_a$  by the two blinded observers was  $2.5 \times 10^{-3} \pm 0.05$ . This is a negligible difference, and when the line of identity is compared with the linear regression line, the two are nearly identical. Thus, there appears to be minimal interobserver variability.

Prior to heparin administration, the transesophageal echocardiographic probe was removed and examined for evidence of esophageal bleeding. No case of hemorrhage

was noted. Postoperative follow-up revealed no clinical evidence of pharyngeal, laryngeal, or esophageal injury after the study.

### Discussion

In 1982, Schluter *et al.* introduced TEE as a new monitoring technique that images the heart and provides information on regional wall motion and left ventricular filling.<sup>5</sup> Since then, several studies on TEE have been performed. Cahalan *et al.* obtained high resolution echocardiograms in 90 out of 108 patients and reproducibly calculated ED<sub>a</sub>, ES<sub>a</sub>, and ejection fraction.<sup>2</sup> Recently, Topol *et al.* analyzed systolic wall thickening obtained with TEE before and after myocardial revascularization, demonstrating that following bypass grafting, regional wall thickening often improved.<sup>1</sup> Kremer *et al.* compared transthoracic echocardiographic measurements prior to induction with postinduction transesophageal echocardiographic measurements of left ventricular diameter.<sup>6</sup> They found a good correlation ( $r = 0.89$ ), but the hemodynamic conditions were not identical at the time of the two measurements, and thus the implications of their results are limited. Although these investigators and others report high-resolution echocardiograms by TEE, the measurements derived from these echocardiograms have not been verified by standard clinically accepted techniques.<sup>7,8</sup>

This study, using an adequate sample size to detect clinically significant differences between the TEE and OHE, shows that two-dimensional TEE provides accurate measurements of ED<sub>a</sub>, ES<sub>a</sub>, and EF<sub>a</sub> in hearts varying widely in size and performance. There is, however, some difference between TEE and OHE, particularly in the measurement of ED<sub>a</sub> in larger hearts and, therefore, in the calculation of EF<sub>a</sub> in larger hearts. This disparity may be due to the posterior orientation and oblique angulation of the TEE transducer, which may, despite attempts to idealize the view, distort the ventricular dimensions. In patients with large hearts, these problems may be magnified, and the altered anatomic relationship between the heart and the esophagus may impede proper probe positioning. Additionally, the anatomic relationship between the heart and the esophagus constantly changes during each cardiac and respiratory cycle, and this may also cause distortion of the ventricular images obtained by the relatively fixed TEE probe. In contrast, because the OHE transducer is hand-held directly on the heart, cardiac motion artifact is minimized. For practical purposes, however, TEE correlates quite well with OHE.

This is the first study to validate quantitative TEE. In comparison to OHE, TEE offers several advantages: 1) the transducer is not in the surgical field; 2) there is no risk of contamination; 3) surgery may proceed unimpeded; and 4) continuous monitoring is possible. In addition, TEE, as opposed to OHE, is not limited to patients undergoing median sternotomy and can be used in all patients under general endotracheal anesthesia. With these proven capabilities and widespread applicability, TEE may become a useful qualitative clinical tool in the management of patients with, or at risk of developing, ventricular dysfunction (*i.e.*, patients with coronary artery disease or those undergoing aortic cross-clamping).<sup>9</sup> TEE may also be of use as a quantitative research tool to study the effects of anesthetic agents, vasodilators, and inotropic drugs on cardiac function.

The authors express their appreciation to Dr. John Thornton of the Biostatistics Department of Mt. Sinai Hospital for his statistical assistance.

### References

1. Topol EJ, Weiss JL, Guzman PA, Dorsey-Lima S, Blanck T, Humphrey L, Baumgartner W, Flaherty J, Reitz B: Immediate improvement of dysfunctional myocardial segments after coronary revascularization: Detection by intraoperative transesophageal echocardiography. *J Am Coll Cardiol* 4:1123-1134, 1984
2. Cahalan MK, Kremer PF, Beaupre PN, Lurz F, Roizen M, Cronelly R, Robinson S, Hamilton W, Eger E, Schiller N: Consistency and reproducibility of transesophageal two-dimensional echocardiography (abstract). *Anesth Analg* 63:194, 1984
3. Dubroff JM, Clark MB, Wong CYH, Spotnitz A, Collins R, Spotnitz H: Left ventricular ejection fraction during cardiac surgery: A two-dimensional echocardiographic study. *Circulation* 68:95-103, 1983
4. Ostle B, Bensing R: *Statistics in Research*. Ames, Iowa State University Press, 1975
5. Schluter M, Langenstein BA, Ploster J, Kremer P, Souquet J, Engel S, Hanrath P: Transesophageal cross-sectional echocardiography with a phased array transducer system. *Br Heart J* 48:67-72, 1982
6. Kremer P, Schwartz L, Cahalan MK, Gutman J, Schiller N: Intraoperative monitoring of left ventricular performance by two-dimensional transesophageal echocardiography (abstract). *Am J Cardiol* 49:956, 1982
7. Hanrath P, Bleifeld W, Souquet J: *Cardiovascular Diagnosis by Ultrasound*. Boston, Martinus Nijhoff, 1982
8. Schluter M, Hinrichs A, Thier W, Kremer P, Schroder S, Cahalan M, Hanrath P: Transesophageal two-dimensional echocardiography: Comparison of ultrasonic and anatomic sections. *Am J Cardiol* 53:1173-1178, 1984
9. Roizen MF, Beaupre PN, Alpert RA, Kremer P, Cahalan M, Schiller N, Sohn Y, Cronelly R, Lurz F, Ehrenfeld W, Stoney R: Monitoring with two-dimensional transesophageal echocardiography. *J Vasc Surg* 1:300-305, 1984