

Excessive Airway Pressure due to a Malfunctioning Anesthesia Ventilator

STEVEN ROTH, M.D.,* ERIC TWEEDIE, M.D.,† RICHARD M. SOMMER, M.D.‡

A case is described wherein high airway pressures and circulatory collapse occurred due to an anesthesia ventilator malfunction. The problem was traced to the ventilator muffler of the Drager Narkomed® 2A anesthesia machine.

REPORT OF A CASE

A 55-yr-old, 75 kg man was scheduled for elective cholecystectomy. One year earlier, a successful aortic valve replacement was performed, and the patient was discharged taking digoxin 0.25 mg daily. There were no complaints of dyspnea or edema, and his lung fields were clear. No heart murmurs were audible. Due to his past history, a 7F balloon-tipped, triple-lumen Swan-Ganz catheter was placed easily *via*




FIG. 1. View of a Drager Narkomed® 2A from the rear. The muffler (arrow) is in the upper right corner of the machine.

* Fellow in Anesthesiology.

† Resident, Dalhousie University.

‡ Instructor in Anesthesiology.

Received from the *Division of Anesthesiology, Cleveland Clinic Foundation, Cleveland, Ohio; the †Department of Anesthesiology, Victoria General Hospital, Halifax, Nova Scotia; and the ‡Department of Anesthesiology, New York University Medical Center, New York, New York. Accepted for publication June 10, 1986.

Address reprint requests to Dr. Roth: Assistant Professor, Department of Anesthesia and Critical Care, University of Chicago, 5841 South Maryland Avenue, Chicago, Illinois 60637.

Key words: Airway: high pressure. Equipment: anesthesia machines; ventilators.




FIG. 2 A (upper). Muffler viewed from below. The foam rubber material inside (arrow) became saturated with water. B (lower). Muffler viewed from above (machine side).

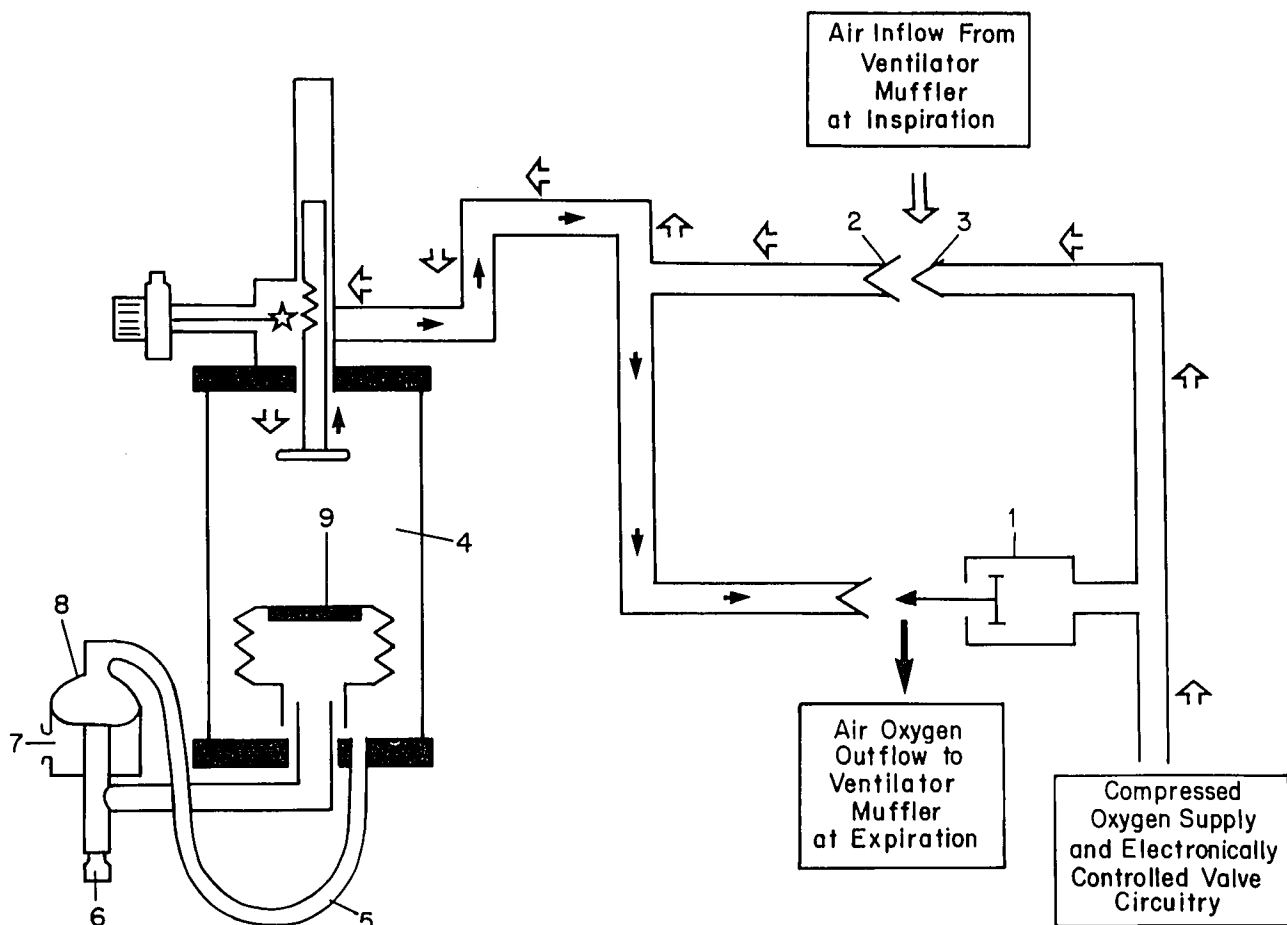


FIG. 3. 1 = compressed gas relief valve. 2 = Venturi. 3 = Venturi intake opening. 4 = bellows chamber. 5 = breathing system relief valve pilot line. 6 = breathing system connector. 7 = connection to scavenging system. 8 = breathing system relief valve. 9 = bellows. *Open arrows* indicate flow of compressing gas during inhalation. *Closed arrows* indicate gas flow during exhalation.

the left internal jugular vein. The cardiac output was 6.0 l/min, and pulmonary artery diastolic pressure 12 mmHg. No pneumothorax was detectable on chest roentgenogram. The surgical course and anesthesia, with fentanyl 500 μ g iv, pancuronium 10 mg iv, nitrous oxide 60%, and oxygen 40%, were uneventful. Six hours postoperatively, tachycardia and a decrease in hematocrit from 35 to 25% prompted return to the operating room for laparotomy for suspicion of intraabdominal hemorrhage. Anesthesia was induced and maintained with fentanyl 500 μ g iv, pancuronium 10 mg iv, nitrous oxide 60%, oxygen 40%, and isoflurane 0.5% inspired. The patient was monitored with an ECG, arterial catheter, Swan-Ganz catheter, and a Biochem[®] (Biochem Corporation, Waukesha, WI) CO₂ monitor attached between the Y-piece and endotracheal tube. The identical anesthesia machine as in the first procedure, a Drager Narkomed[®] 2A (North American Drager, Telford, PA), was employed. The ventilator, a standing bellows model, Drager AV-E, was set for a 650-ml tidal volume at a rate of 10 breaths/min. Two hours postinduction the heart rate suddenly decreased to 40 beats/min, and the arterial blood pressure became unobtainable. The P_{CO₂} sampled between the Y-piece and endotracheal tube was 0 mmHg. Pulmonary artery diastolic pressure increased from 10 mmHg to greater than 40 mmHg. Airway pressure was 70 cmH₂O, and the continuing and high pressure alarms sounded on the machine. The ventilator was immediately turned off, and the lungs ventilated manually

with the reservoir bag. This allowed airway pressures to return to normal. Within 10 s of restoration of normal airway pressure the blood pressure returned to 110/80 mmHg and heart rate to 70 beats/min. A different anesthesia machine was used allowing uneventful completion of the procedure. An intraabdominal hematoma was evacuated, the patient was brought to the recovery room, and the trachea was extubated several hours later. No signs of barotrauma were detected, and his postoperative course was uncomplicated.

After surgery, the same ventilator and anesthesia machine were used with a reservoir bag as a model lung. The same high airway pressures and ventilator malfunction occurred, but could be relieved by removal of the ventilator muffer (figs. 1 and 2A and B), which is distal to the compressed gas exhaust. The muffer was examined and found to be saturated with water. It was dried, placed back on the machine, and subsequently functioned normally.

DISCUSSION

Numerous case reports have described barotrauma due to ventilator malfunction. Causes include failure of an expiratory valve,^{1,2,5} misplacement of an expiratory valve,³

incorrect assembly of an anesthetic circuit,⁴ closed ventilator port,⁶ and defective ventilator gas evacuation outlet valve.⁷ This is the first case report of high airway pressure due to a malfunction of the compressed gas exhaust system of a ventilator.

The ventilator muffler (fig. 2A and B) of the Drager Narkomed® 2A is designed to silence the exhaust of driving gas from the ventilator. It is located in the rear of the anesthesia machine (fig. 1). The breathing system of the Drager Narkomed® 2A is shown diagrammatically in figure 3. The valve numbered 1 is the compressed gas relief valve. At expiration the pressure inside the bellows chamber (4) is released through valve 1, and the bellows (9) is allowed to ascend. Because of the obstruction to outflow at the muffler, which is located distal to valve 1, gas failed to exit at valve 1, and the pressure inside the bellows chamber exceeded that of the patient's airway. The bellows remained in the fully descended end-inspiratory position. This prevented exhalation from occurring (patient-circuit relief valve 8 failed to open), and high airway pressures resulted as gas continued to flow into the system at 6 l/min. That the muffler was the cause of the malfunction was proven by normal ventilator function after its removal and/or drying, and recurrence when the wet muffler was placed back on the ventilator. There are two plausible explanations for why the muffler became wet and produced a sudden obstruction to exhalation. The muffler may have been cleaned and then added to the system immediately before the event occurred. To our knowledge, however, the muffler was in place from the start of the operation. The most plausible explanation is that the muffler became saturated with water during the anes-

thetic. Perhaps the fluids were accidentally sprayed on it or water entered from an unknown source, which was unlikely to be the compressed gas because it is dry.

Our patient suffered no harmful effects due to rapid recognition of the problem and implementation of corrective action. Simultaneous continuing pressure and high pressure alarms that sound when the pressure exceeds 15 cmH₂O for 10 s and 65 cmH₂O for any period of time⁸ assist one in recognizing this ventilator malfunction. Because of the potential danger from the ventilator muffler, we recommend either removing it from the machine or making certain it is kept dry.

REFERENCES

1. Newton NI, Adams AP: Excessive airway pressure during anesthesia. *Anaesthesia* 33:689-699, 1978
2. Thompson PW: Prevention of the hazard of excessive airway pressure. *Anaesthesia* 34:393-394, 1979
3. Dean HN, Parsons DE, Raphaely RC: Case report: Bilateral tension pneumothorax from mechanical failure of an anesthesia machine due to misplaced expiratory valve. *Anesth Analg Curr Res* 50:195-198, 1971
4. Sellery GR: Hazards of artificial ventilation in the operating room. *Can Med Assoc J* 107:421-424, 1972
5. Norry HT: A pressure limiting valve for anaesthetic and respirator circuits. *Can Anaesth Soc J* 19:583-588, 1972
6. Sears BE, Bocar ND: Pneumothorax resulting from a closed anesthesia ventilator port. *ANESTHESIOLOGY* 47:311-313, 1977
7. Henzig D: Insidious PEEP from a defective ventilator gas evacuation outlet valve. *ANESTHESIOLOGY* 57:251-252, 1982
8. Schrieber P: Safety guidelines for anesthesia systems. Boston, Merchants Press, 1985, p 82

Anesthesiology
65:534-536, 1986

Hypoxia Caused by an Esophageal Stethoscope

WAYNE A. PICKARD, M.D.,* LARRY REID, M.D.†

The esophageal stethoscope is a relatively noninvasive monitor that provides extremely useful information. Mis-

placement of this device into the trachea has been described^{1,2} and is probably not regarded as potentially life-threatening. We describe such a misplacement that resulted in serious hypoxemia and probably would have gone undetected except for the use of a hemoglobin saturation monitor.

REPORT OF A CASE

The patient was a 19-yr-old man with cerebral palsy, who was chronically bedridden and severely retarded. At the age of 16 yr, he had suffered a spontaneous intracranial hemorrhage that had left him with chronic obstructive hydrocephalus, for which a ventriculoperi-

* Clinical Assistant Professor.

† Resident.

Received from the Department of Anesthesiology, University of South Florida School of Medicine and Tampa General Hospital, Tampa, Florida. Accepted for publication June 10, 1986.

Address reprint requests to Dr. Pickard: Department of Anesthesiology, Tampa General Hospital, Tampa, Florida 33606.

Key words: Complication: hypoxia. Monitor: esophageal stethoscope: pulse oximetry.