

incorrect assembly of an anesthetic circuit,<sup>4</sup> closed ventilator port,<sup>6</sup> and defective ventilator gas evacuation outlet valve.<sup>7</sup> This is the first case report of high airway pressure due to a malfunction of the compressed gas exhaust system of a ventilator.

The ventilator muffler (fig. 2A and B) of the Drager Narkomed® 2A is designed to silence the exhaust of driving gas from the ventilator. It is located in the rear of the anesthesia machine (fig. 1). The breathing system of the Drager Narkomed® 2A is shown diagrammatically in figure 3. The valve numbered 1 is the compressed gas relief valve. At expiration the pressure inside the bellows chamber (4) is released through valve 1, and the bellows (9) is allowed to ascend. Because of the obstruction to outflow at the muffler, which is located distal to valve 1, gas failed to exit at valve 1, and the pressure inside the bellows chamber exceeded that of the patient's airway. The bellows remained in the fully descended end-inspiratory position. This prevented exhalation from occurring (patient-circuit relief valve 8 failed to open), and high airway pressures resulted as gas continued to flow into the system at 6 l/min. That the muffler was the cause of the malfunction was proven by normal ventilator function after its removal and/or drying, and recurrence when the wet muffler was placed back on the ventilator. There are two plausible explanations for why the muffler became wet and produced a sudden obstruction to exhalation. The muffler may have been cleaned and then added to the system immediately before the event occurred. To our knowledge, however, the muffler was in place from the start of the operation. The most plausible explanation is that the muffler became saturated with water during the anes-

thetic. Perhaps the fluids were accidentally sprayed on it or water entered from an unknown source, which was unlikely to be the compressed gas because it is dry.

Our patient suffered no harmful effects due to rapid recognition of the problem and implementation of corrective action. Simultaneous continuing pressure and high pressure alarms that sound when the pressure exceeds 15 cmH<sub>2</sub>O for 10 s and 65 cmH<sub>2</sub>O for any period of time<sup>8</sup> assist one in recognizing this ventilator malfunction. Because of the potential danger from the ventilator muffler, we recommend either removing it from the machine or making certain it is kept dry.

#### REFERENCES

1. Newton NI, Adams AP: Excessive airway pressure during anesthesia. *Anaesthesia* 33:689-699, 1978
2. Thompson PW: Prevention of the hazard of excessive airway pressure. *Anaesthesia* 34:393-394, 1979
3. Dean HN, Parsons DE, Raphaely RC: Case report: Bilateral tension pneumothorax from mechanical failure of an anesthesia machine due to misplaced expiratory valve. *Anesth Analg Curr Res* 50:195-198, 1971
4. Sellery GR: Hazards of artificial ventilation in the operating room. *Can Med Assoc J* 107:421-424, 1972
5. Norry HT: A pressure limiting valve for anaesthetic and respirator circuits. *Can Anaesth Soc J* 19:583-588, 1972
6. Sears BE, Bocar ND: Pneumothorax resulting from a closed anesthesia ventilator port. *ANESTHESIOLOGY* 47:311-313, 1977
7. Henzig D: Insidious PEEP from a defective ventilator gas evacuation outlet valve. *ANESTHESIOLOGY* 57:251-252, 1982
8. Schrieber P: Safety guidelines for anesthesia systems. Boston, Merchants Press, 1985, p 82

Anesthesiology  
65:534-536, 1986

## Hypoxia Caused by an Esophageal Stethoscope

WAYNE A. PICKARD, M.D.,\* LARRY REID, M.D.†

The esophageal stethoscope is a relatively noninvasive monitor that provides extremely useful information. Mis-

placement of this device into the trachea has been described<sup>1,2</sup> and is probably not regarded as potentially life-threatening. We describe such a misplacement that resulted in serious hypoxemia and probably would have gone undetected except for the use of a hemoglobin saturation monitor.

#### REPORT OF A CASE

The patient was a 19-yr-old man with cerebral palsy, who was chronically bedridden and severely retarded. At the age of 16 yr, he had suffered a spontaneous intracranial hemorrhage that had left him with chronic obstructive hydrocephalus, for which a ventriculoperi-

\* Clinical Assistant Professor.

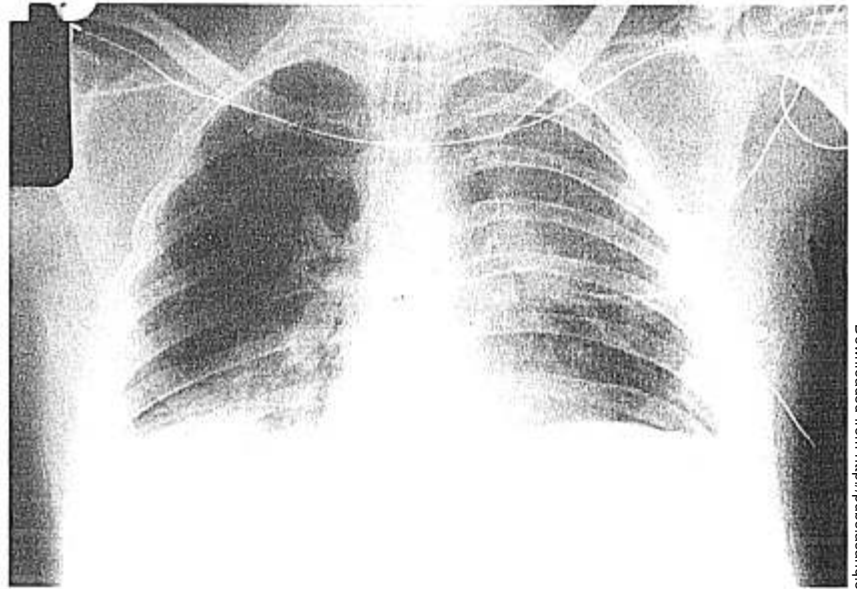
† Resident.

Received from the Department of Anesthesiology, University of South Florida School of Medicine and Tampa General Hospital, Tampa, Florida. Accepted for publication June 10, 1986.

Address reprint requests to Dr. Pickard: Department of Anesthesiology, Tampa General Hospital, Tampa, Florida 33606.

Key words: Complication: hypoxia. Monitor: esophageal stethoscope: pulse oximetry.

FIG. 1. Intraoperative chest roentgenogram showing the endotracheal tube positioned above the carina and the esophageal stethoscope extending beyond it into the right lower lobe bronchus. There is right lower lobe collapse and right upper lobe hyperinflation.



toneal shunt had been inserted. He was hospitalized this time because of deteriorating mental status that was diagnosed as being the result of shunt failure. During the preoperative evaluation, the patient was also noted to have increased upper airway secretions due to tracheobronchitis, and resting hypoxemia ( $P_{aO_2}$  61 mmHg,  $P_{aCO_2}$  43 mmHg,  $pH_a$  7.46) while breathing 1.0 l/min of  $O_2$  via a nasal cannula. Because of the urgent nature of the shunt failure, it was decided to proceed despite the presence of pulmonary problems.

Induction of anesthesia proceeded uneventfully, with the usual precautions being taken against increasing intracranial pressure. Laryngoscopy and endotracheal intubation were accomplished without difficulty, the cuff was inflated, and the tube was secured. An esophageal stethoscope (Hi-Lo Temp<sup>®</sup>, 18 French, Mallinckrodt, Glens Falls, NY) was inserted blindly through the mouth.

Soon after induction and endotracheal intubation, a pulse oximeter (Nellcor<sup>®</sup>) was attached and the hemoglobin saturation was 93% with a Fractional inspired  $O_2$  concentration ( $FI_{O_2}$ ) of 1.0, but soon decreased to 87%. The lungs were being ventilated, both sides of the chest were noted to be moving, and bilateral equal breath sounds (rhonchi present, no other abnormal sounds) were confirmed several times. The endotracheal tube position was rechecked by palpating the cuff in the suprasternal notch and by direct laryngoscopy. A moderate amount of secretions was suctioned from the tracheal tube, with no definite improvement in hemoglobin saturation. PEEP 10 cm was added, and within seconds, the saturation decreased to 81% and the PEEP was then discontinued.

The saturation continued to fluctuate between the high 80s and low 90s. A blood gas analysis taken at this time confirmed the presence of hypoxemia ( $P_{aO_2}$  55 mmHg,  $P_{aCO_2}$  41 mmHg,  $pH_a$  7.46). Soon thereafter, the head was turned for the surgical prep, and the saturation promptly decreased to 82%. It was decided to aspirate the shunt to relieve acutely the intracranial hypertension and abandon the definitive procedure. A chest roentgenogram (fig. 1) was obtained to rule out an intrathoracic catastrophe, and the patient was taken to the intensive care unit for management of his respiratory impairment.

With the esophageal stethoscope removed, the patient's pulmonary status gradually improved during the next 24 h. He has subsequently had his shunt revised under general anesthesia without incident and has returned to his baseline mental status.

## DISCUSSION

Accidental tracheal misplacement of an esophageal stethoscope has been described.<sup>1,2</sup> However, in none of these reports was hypoxemia noted. The use of an esophageal stethoscope is considered routine and almost risk free, and therefore tracheal insertion was not considered in the differential diagnosis of this case of dangerous hypoxemia. This case demonstrates that tracheal misplacement of esophageal stethoscopes not only can occur but can be life-threatening as well, especially in patients with preexisting pulmonary disease.

The signs of tracheal insertion of an esophageal probe—difficulty of insertion, movement of the endotracheal tube on insertion, diminished heart sounds, lower-than-expected temperature readings, and a higher-than-expected cuff pressure required to seal the tracheal tube—may be subtle and missed if its possibility is not considered. Breath sounds may be equal and bilateral. Although healthy lungs may be expected to tolerate this impediment to ventilation and misplacement can go undiscovered, it imposes the additional hazards of aspiration of pharyngeal material past an imperfect cuff seal and inadequate ventilation due to leakage of gases out of the trachea due to an imperfect cuff seal. In patients with impaired lung function, atelectasis resulting directly from misplacement may be poorly tolerated, and attempts to treat the resulting hypoxemia with higher inflation pressures or PEEP can result in redistribution of blood flow to the poorly ventilated portions of the lungs, resulting in markedly worsened hypoxemia, as occurred in this case.

It is noteworthy that this patient's hypoxemia was discovered through the use of pulse oximetry. There was

no cyanosis, change in breath sounds, or hemodynamic instability. If the pulse oximeter had not been in use, the case could easily have proceeded to the point of anesthetic disaster before any sign of trouble was detected.

In summary, we have described a case of accidental bronchial insertion of an esophageal stethoscope, resulting in hypoxemia which was discovered in a timely fashion through the use of pulse oximetry. We recommend a heightened awareness of the possibility of misplacement

of esophageal probes and suggest that the use of pulse oximetry may have been life-saving in this case.

## REFERENCES

1. Sweatman AJ, Tomasello PA, Loughhead MG, Orr M, Datta T: Misplacement of nasogastric tubes and oesophageal monitoring devices. *Br J Anaesth* 50:389-392, 1978
2. Goto H, Hackman LT, Arakawa K: Tracheal insertion of an esophageal stethoscope. *Anesth Analg* 56:584-585, 1977

Anesthesiology  
65:536-538, 1986

## The Pharmacokinetics of Rectal Midazolam for Premedication in Children

C. SAINT-MAURICE, M.D.,\* C. MEISTELMAN, M.D.,† E. REY, M.D.,‡ C. ESTEVE, M.D.,†  
D. DE LAUTURE, M.D.,‡ G. OLIVE, M.D.§

Midazolam, a short-acting, water-soluble benzodiazepine with a short elimination half-life in adults,<sup>1,2</sup> has been recommended as an intramuscular preanesthetic sedative in children.<sup>3</sup> Rectal administration of benzodiazepines may offer similar sedation and relief of anxiety without the discomfort and fear associated with intramuscular injections in children.<sup>4</sup> Thus, we sought to determine whether a rectal solution of midazolam could be used in children and to characterize the pharmacokinetics of midazolam following rectal administration.

## METHODS

Sixteen healthy children (ASA I), ranging in age from 3 to 9 yr and undergoing minor genitourinary surgery, were studied. The protocol was approved by our Human Ethics Committee and informed consent was obtained from the parents. All the children were premedicated with midazolam 0.3 mg/kg diluted in 5 ml of saline solution and administered per rectum. Sedation was evaluated using two criteria: the child's behavior and the acceptance of both the mask and anesthetic vapors. Behavior was

evaluated by the same investigator. It was rated by one of the following five categories: 1) agitated; 2) awake but with spontaneous body movements; 3) calm and motionless; 4) drowsy; and 5) asleep. Acceptance of the mask at induction of anesthesia was assessed 30 min after midazolam administration by the same investigator. Anesthesia was induced with halothane, nitrous oxide, and oxygen.

Plasma concentration time course of midazolam following rectal administration was studied in nine of the children. Venous blood samples (2 ml) were drawn 3, 5, 10, 15, 20, 30, 60, 90, 120, 180, 240, and 300 min after rectal administration. Plasma was separated by centrifugation and stored at  $-20^{\circ}\text{C}$  until analyzed. Plasma concentrations were determined by gas-liquid chromatography with electron capture detection.<sup>5</sup> This method has a sensitivity of 2.0 ng/ml and a coefficient of variation of 2.8-4% at the plasma concentrations studied. The main metabolite of midazolam,  $\alpha$ -hydroxymidazolam, is not detected by the assay. Midazolam plasma concentration decay curve was analyzed by a nonlinear least-squares regression technique. Pharmacokinetic parameters were determined from the coefficients and exponents obtained by analysis of the plasma concentrations. They included maximum plasma concentration ( $C_{p_{\max}}$ ), time to  $C_{p_{\max}}$  ( $t_{\max}$ ), terminal half-life ( $T_{1/2\beta}$ ), and apparent clearance (Cl). The area under the plasma concentration time curve ( $AUC_0^{\infty}$ ,  $\int_0^{\infty} c.t.dt$ ) was calculated by the trapezoidal rule and the unknown area to infinity calculated from the slope  $\beta$  and the last measured midazolam plasma concentration. The mean residence time (MRT) was determined by non-compartmental techniques<sup>6</sup> and calculated as the ratio:

$$MRT = \frac{AUMC}{AUC} = \frac{\int_0^{\infty} c.t.dt}{\int_0^{\infty} c.dt}$$

\* Professor and Head, Department of Anesthesia.

† Assistant in Anesthesia.

‡ Assistant in Pharmacology.

§ Professor and Head, Department of Pharmacology.

Received from the Departments of Anesthesia and Pharmacology, Hôpital Saint Vincent de Paul, 74, avenue Denfert-Rochereau, 75674 Paris Cedex 14, France. Accepted for publication June 17, 1986. Presented at the annual meeting of the American Society of Anesthesiologists, San Francisco, California, October 1985.

Address reprint requests to Dr. Meistelman, Department of Anesthesia, Hôpital Saint Vincent de Paul 74, avenue Denfert-Rochereau 75674 Paris Cedex 14-France.

Key words: Anesthesia; pediatrics. Pharmacokinetics: midazolam. Premedication: midazolam.