

Evaluation of Intraoperative Transesophageal Two-dimensional Echocardiography

Martin D. Abel, M.D.,* Rick A. Nishimura, M.D.,† Mark J. Callahan, M.D.† Kai Rehder, M.D.,‡
Duane M. Ilstrup, M.S.,§ A. Jamil Tajik, M.D.¶

Transesophageal two-dimensional echocardiography (TEE) was evaluated in 11 patients who underwent myocardial revascularization. The TEE transducer was positioned to view the left ventricular (LV) short-axis at the level of the papillary muscles (midcavity). Good quality echocardiographic images were obtainable in ten of 11 patients. Global LV function was assessed by measuring LV end-diastolic and end-systolic area and computing the fractional area change (FAC). Measurements of LV areas and FAC had excellent intraobserver reproducibility. Regional LV function was analyzed in two ways after dividing the short-axis view of the LV into four or five anatomic segments. Systolic wall thickening (SWT) of the myocardium was measured in each of four segments by digitization of the endocardial and epicardial borders of the LV and determining the fractional wall thickening. Measurements of SWT were not reproducible, primarily because of a difficulty in delineating the epicardial border of the LV accurately. In the second method, regional wall motion (RWM) in each of five segments was graded according to a previously developed scoring system. RWM analysis proved to be a measurement with excellent interobserver and intraobserver reproducibility. TEE was performed without complication and found to be a reproducible method for assessing global and regional LV function. Quantitative analysis is tedious and, therefore, currently not available on-line in the operating room. (Key words: Heart; myocardial function, ventricles; myocardial revascularization. Monitoring; transesophageal two-dimensional echocardiography.)

THE ADVENT OF transesophageal two-dimensional echocardiography (TEE) has made continuous echocardiographic monitoring possible during an entire operative procedure.¹ Abnormal left ventricular (LV) regional wall motion (RWM) or systolic wall thickening (SWT) observed echocardiographically are sensitive and early indicators of myocardial ischemia.²⁻⁴ In a recent article, Smith *et al.* compared simultaneous recordings of the transesophageal echocardiogram and 7-lead electrocardiogram obtained intraoperatively and showed that the development of new RWM abnormalities was a more sensitive and earlier marker of myocardial ischemia than electrocardiographic changes.⁵ Regional LV function may be assessed by an-

alyzing either RWM or SWT of the LV. The assessment of global LV function from two-dimensional echocardiography may be determined by deriving the fractional area change (FAC) or area ejection fraction from measurements of LV end-systolic and end-diastolic area. This study evaluated the reproducibility of several of these measurements of global and regional LV function obtained with TEE during myocardial revascularization.

Materials and Methods

PATIENT POPULATION

The study protocol was approved by the Mayo Clinic Institutional Review Board and written, informed consent was obtained from each patient. Eleven patients who underwent myocardial revascularization were studied: ten men and one woman (mean age, 65 yr). The indications for operation were class III-IV angina in all patients. Eight patients had a previous history of myocardial infarction. One patient had coexistent valvular aortic stenosis. This patient was not excluded because the focus of this study was to evaluate the reproducibility of TEE indices of LV function rather than to assess changes that might occur in individual patients.

Six patients had three-vessel disease, four had two-vessel disease, and one had single-vessel disease. Left ventriculograms were obtained in all but one patient; seven patients had ejection fractions > 50%, and the remaining four patients had ejection fractions < 50%.

ANESTHETIC TECHNIQUE

Patients were premedicated with either oral lorazepam (2-3 mg) or diazepam (10 mg). Anesthesia was induced with a combination of either diazepam (10 mg) or etomidate (0.15 mg·kg⁻¹) and a narcotic: fentanyl (50 µg·kg⁻¹), morphine (1 mg·kg⁻¹), or oxymorphone (0.2 mg·kg⁻¹). Muscle paralysis was obtained with pancuronium (0.1 mg·kg⁻¹), and anesthesia was maintained with either isoflurane or enflurane vaporized in 60-100% oxygen, the balance consisting of nitrogen. Hemodynamic variables were monitored by using radial artery and triple-lumen thermodilution pulmonary artery catheters connected to appropriate transducers. These measurements were used as a guide in caring for patients because no treatment was initiated based on TEE monitoring. No attempt was made to standardize the anesthetic man-

* Assistant Professor of Anesthesiology, Mayo Medical School.

† Assistant Professor of Medicine, Mayo Medical School.

‡ Professor of Anesthesiology and of Physiology, Mayo Medical School.

§ Associate, Section of Medical Research Statistics.

¶ Professor of Medicine, Mayo Medical School.

Received from the Departments of Anesthesiology and Physiology and Biophysics, the Division of Cardiovascular Diseases and Internal Medicine, and the Section of Medical Research Statistics, Mayo Clinic and Mayo Foundation, Rochester, Minnesota 55905. Accepted for publication August 5, 1986.

Address reprint requests to Dr. Abel: Anesthesia Department, Mayo Clinic, 200 First Street SW, Rochester, Minnesota 55905.

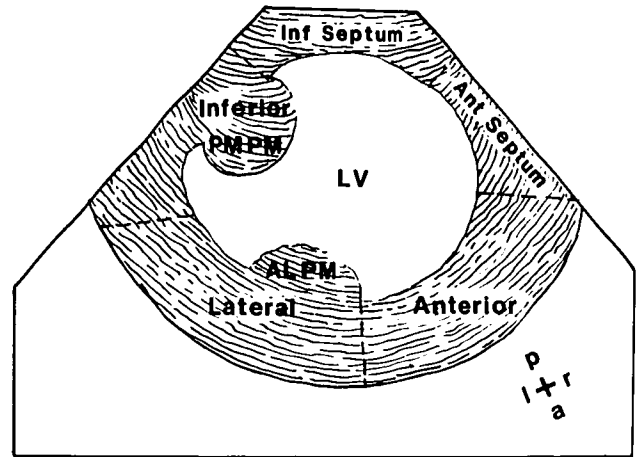
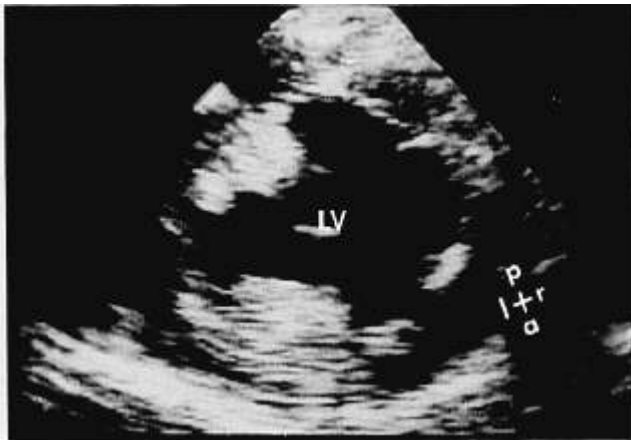


FIG. 1. Short-axis view of the left ventricle (LV) during diastole at the level of the papillary muscles with a stillframe of the two-dimensional echocardiogram (left panel) and an artist's rendition (right panel), demonstrating the LV cavity with the segments of myocardium used in the analysis of regional wall motion (RWM) and systolic wall thickening (SWT). PMPM = posteromedial papillary muscle and ALPM = anterolateral papillary muscle. *a* = anterior; *p* = posterior; *r* = right; and *l* = left.

agement because we felt this would have little bearing on the reproducibility of measurements of LV function from TEE.

OPERATIVE TECHNIQUE

Patients were cooled on cardiopulmonary bypass to a nasopharyngeal temperature of 25–28° C. Blood flow was maintained at 2.4 l · min⁻¹ · m⁻². Myocardial protection during the period of aortic cross-clamping was obtained by the topical application of iced saline to the heart and by the infusion of cold blood mixed with cardioplegic solution. Saphenous vein bypass grafts were used in all patients. Three patients also had internal mammary artery grafts to the left anterior descending coronary artery, and one patient had an aortic valve replacement.

ECHOCARDIOGRAPHIC RECORDING

A 3.5-MHz transducer mounted on a 9-mm endoscopic shaft (Diasonics, Inc., Milpitas, CA) was connected to a phased-array ultrasonograph (Diasonics 3400). After induction of anesthesia and intubation of the trachea, the TEE transducer was positioned in the esophagus approximately 35–40 cm from the incisor teeth. The transducer was directed so as to obtain a long-axis view in order to identify the mitral and aortic valve and LV. The transducer was then advanced slowly and flexed anteriorly to obtain an LV short-axis view at the level of the papillary muscles (fig. 1). In this view of the LV, the cavity has a nearly circular shape, and the anterolateral and posteromedial papillary muscles are equal in size. The probe was fixed in position, and small positional adjustments were made during the operation to maintain the same relative size of the papillary muscles. The two-dimensional echo-

cardiogram was monitored throughout the entire procedure, and video recordings were obtained at different times for later analysis. These included recordings: 1) before sternotomy; 2) after sternotomy; 3) 5–10 min after cardiopulmonary bypass was discontinued, prior to protamine administration; and 4) at skin closure.

ANALYSIS

At a later time, after reviewing the entire video recording, a representative cardiac cycle of the short-axis view at each of the four periods was transferred to an echocardiographic computer system (Microsonics, Inc., Indianapolis, IN) that allowed a cardiac cycle to be digitized on a 512 × 512 pixel display at 67 ms intervals starting from the onset of the R-wave of the electrocardiogram.

LV AREA AND FAC

Endocardial and epicardial borders at end-diastole and end-systole were traced.⁶ End-diastole was indicated by the peak of the R-wave, and end-systole was defined as the smallest systolic endocardial area. The outlines of the papillary muscles were excluded from the tracings. FAC was defined as:

$$FAC(\%) = \frac{\text{End-diastolic area} - \text{End-systolic area}}{\text{End-diastolic area}} \times 100$$

End-diastolic area and FAC provide an assessment of relative LV end-diastolic volume⁷ and global LV function, respectively.

RWM

The myocardium was divided into five segments, starting clockwise immediately adjacent to the posteromedial

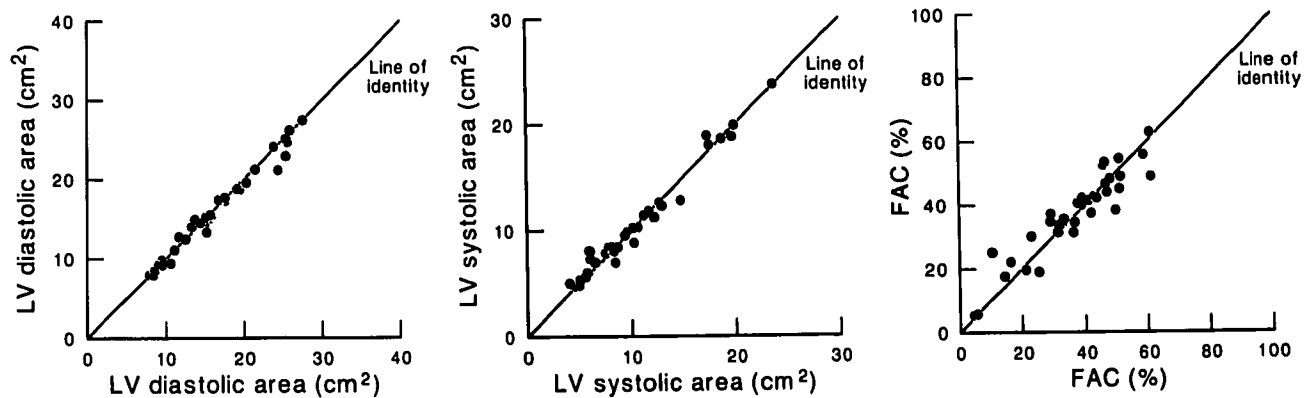


FIG. 2. Intraobserver variability performed by the same observer at a 2-week interval in measurements of left ventricular end-diastolic area (left panel), end-systolic area (middle panel), and fractional area change (FAC) (right panel), demonstrating the high degree of reproducibility of these measurements.

papillary muscle: inferoseptal, anteroseptal, anterior, lateral, and inferior⁸ (fig. 1). Each of the five segments of the LV short-axis view were graded according to a visual assessment of wall motion (0 = hyperkinetic; 1 = normal; 2 = hypokinetic; 3 = akinetic; 4 = dyskinetic; and 5 = aneurysm). The grading was done for the four different periods of the operation, a process that was facilitated by simultaneously displaying images on a quad screen.

SWT

A total of four segments was analyzed for SWT by combining the inferoseptal and anteroseptal segments used in the RWM analysis into a single septal segment. Using a fixed external frame of reference, SWT for each of the four quadrants was defined as:

$$\text{SWT}(\%) = \frac{\text{End-systolic wall thickness} - \text{End-diastolic wall thickness}}{\text{End-diastolic wall thickness}} \times 100$$

STATISTICAL ANALYSIS

Intraobserver variability in estimation of the end-diastolic area, end-systolic area, and FAC were described by estimating the median and 75th percentile of the distribution of the absolute value of the differences in two readings by the same observer with a 2-week interval between readings. Interobserver variability in the estimation of RWM was determined by two echocardiographers (R.N. and M.C.) working independently. Both interobserver and intraobserver analyses were performed on data obtained during the four periods of the study.

Results

TECHNICAL ASPECTS

There were no complications associated with TEE monitoring. Adequate transesophageal echocardiograms

were obtained in ten of 11 patients. In the remaining patient, although the long-axis view could be imaged, the transducer could not be positioned to obtain a true short-axis view, resulting in an oblique cut. Data from this patient were excluded from this report. Although sternotomy had little effect on the position of the heart in the chest, some manipulation of the transducer was commonly required to obtain the same short-axis view at the end of cardiopulmonary bypass.

LV AREA AND FAC

Intraobserver variability in the measurement of the LV areas was small, with a median absolute difference of 0.4 cm² and 0.3 cm² and a 75th percentile of 0.9 cm² and 0.7 cm² for end-diastolic and end-systolic areas, respectively (fig. 2, left and middle panels). The intraobserver variability in measurements of FAC had a median absolute difference of 3% and a 75th percentile of 5.75% (fig. 2, right panel).

RWM

A comparison of RWM scores obtained before sternotomy with those obtained at skin closure showed that 54% of segments remained unchanged, 26% of segments deteriorated, and 20% of segments showed an improvement. The change in RWM score of a segment was not dependent on its location. Analysis of interobserver (fig. 3, left panel) and intraobserver (fig. 3, right panel) variability demonstrated complete agreement on RWM score in 84% and 78% of segments, respectively; disagreement by two or more categories occurred in 1.1% and 2.5% of the segments, respectively.

SWT

The calculated SWT correlated poorly with the analysis of RWM. Intraobserver variability demonstrated a marked degree of random error (fig. 4). Because of the

	Normal	Hypo-kinetic	Akinetic	Dyskinetic
Normal	103	7	0	0
Hypokinetic	8	24	5	0
Akinetic	2	6	23	0
Dyskinetic	0	0	0	0

	Normal	Hypo-kinetic	Akinetic	Dyskinetic
Normal	111	20	5	0
Hypokinetic	5	25	11	0
Akinetic	0	2	21	0
Dyskinetic	0	0	0	0

FIG. 3. Interobserver (left panel) and intraobserver (right panel) variability in RWM scores, demonstrating complete agreement on RWM score in 84% and 78% of cases (shaded boxes) and disagreement by more than two categories in 1.1% and 2.5%, respectively. The interobserver analysis contains 178 out of a possible 200 paired observations because 22 segments with inferior image quality could not be scored by one of the observers (M.C.).

extremely poor reproducibility of this measure, further analysis was not done.

Discussion

TEE is a relatively new tool for evaluating LV function intraoperatively. In ten of 11 patients satisfactory echocardiograms were successfully obtained and no complications related to TEE occurred in any patient. LV end-diastolic and end-systolic areas as well as the FAC, indices of global LV function, could be measured with a high degree of reliability. Two indices of regional LV function were also analyzed. RWM was a highly reproducible measurement, whereas SWT could not be reliably determined. This was due to a difficulty in delineating the epicardial border of the LV. It is likely that future technological improvements will overcome the relatively inadequate resolution of the echocardiographic image. Additional technical considerations that may have affected the results of our analysis but not the conclusions are addressed in the following.

We used a single short-axis view of the LV at the mid-cavity because the five major segments (anteroseptal, anterior, lateral, inferior, and inferoseptal) of the LV are represented in this view. In addition, because the right, left anterior descending, and circumflex coronary arteries supply these segments, the effects on RWM of a coronary artery stenosis producing ischemia should be visible in this single view. We, therefore, believe that the short-axis view of the LV at the level of the papillary muscles provides the most information about global and regional LV function that can be obtained from a single view of the heart. On the other hand, LV ischemia producing RWM abnormalities at the apex or base might go undetected.

The transducer required some repositioning to maintain the same view of the LV for the duration of the operative procedure. This was particularly true after the heart had been manipulated. Positional adjustments of the TEE transducer were made based on the relative sizes of the papillary muscles. Comparison of data obtained from different LV cross-sections at different times could

lead to erroneous conclusions about changes in global or regional LV function.

In this study a single cardiac cycle was used to represent LV function at a designated time period. We analyzed five cardiac cycles at the four designated study periods in two patients to determine the error introduced by the use of only one cardiac cycle. The low coefficient of variation of these measurements of end-diastolic area, end-systolic area, and FAC of 5.0%, 6.5%, and 8.4%, respectively, led us to use a single cardiac cycle for successive patients. Because no attempt was made to choose a particular phase of the respiratory cycle to make these measurements, it is unlikely that variations associated with respiration significantly influenced our results. However, it would seem prudent that when comparing changes in LV function that occur over time, measurements should

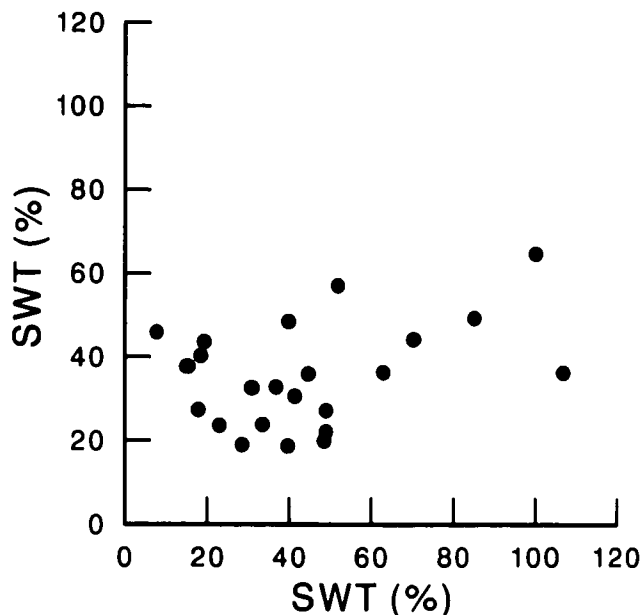


FIG. 4. Intraobserver variability in measurements of SWT from four patients. This analysis was discontinued because of the poor reproducibility of these measurements.

be obtained at the same phase of the respiratory cycle, e.g., end-expiration.

Measurement of RWM and SWT provide an excellent measure of myocardial ischemia.²⁻⁴ Topol *et al.* used SWT obtained from TEE to follow changes in regional LV function occurring intraoperatively during coronary artery bypass grafting.⁹ However, measurement of SWT in our study was unreliable because of difficulty we encountered in identifying the epicardial border of the LV because of poor image resolution. The visual assessment of RWM, although qualitative, is a well-documented method for diagnosing myocardial ischemia.¹⁰ This visual assessment of RWM takes into account wall thickening, endocardial motion, and motion of the heart within the chest cavity that occur during the cardiac cycle. Low interobserver and intraobserver variations in RWM were documented in this study. We believe that the simultaneous display of the different periods of the operation on a quad screen enhanced the detection of changes in wall motion. The visual analysis of RWM in this study is in agreement with the study of Topol *et al.* that demonstrated the variable effects of myocardial revascularization on RWM.⁹

In summary, measurements of LV area, FAC, and RWM obtained intraoperatively with TEE were highly reproducible. SWT, a sensitive marker of regional myocardial ischemia, could not be reliably measured because of the difficulty in delineating the epicardial border of the LV. These measurements provide an assessment of LV function that may be used intraoperatively. However, further studies are needed to determine the relationship between data obtained from TEE with that provided by more conventional monitors of cardiovascular function. On the other hand, TEE provides a means of measuring parameters, previously unobtainable intraoperatively. Thus, measurements of contractility like the end-systolic pressure-volume ratio may now be derived with this technology.

References

- Schlüter M, Langenstein BA, Polster J, Kremer P, Souquet J, Engel S, Hanrath P: Transoesophageal cross-sectional echocardiography with a phased array transducer system: Technique and initial clinical results. *Br Heart J* 48:67-72, 1982
- Pandian NG, Kerber RE: Two-dimensional echocardiography in experimental coronary stenosis. I. Sensitivity and specificity in detecting transient myocardial dyskinesia: Comparison with sonomicrometers. *Circulation* 66:597-602, 1982
- Wyatt HL, Meerbaum S, Heng MK, Rit J, Gueret P, Corday E: Experimental evaluation of the extent of myocardial dyssynergy and infarct size by two-dimensional echocardiography. *Circulation* 63:607-614, 1981
- Lieberman AN, Weiss JL, Jugdutt BI, Becker LC, Bulkley BH, Garrison JG, Hutchins GM, Kallman CA, Weisfeldt ML: Two-dimensional echocardiography and infarct size: Relationship of regional wall motion and thickening to the extent of myocardial infarction in the dog. *Circulation* 63:739-746, 1981
- Smith JS, Cahalan MK, Benefiel DJ, Byrd BF, Lurz FW, Shapiro WA, Roizen MF, Bouchard A, Schiller NB: Intraoperative detection of myocardial ischemia in high-risk patients: Electrocardiography versus two-dimensional transesophageal echocardiography. *Circulation* 72:1015-1021, 1985
- Wyatt HL, Haendchen RV, Meerbaum S, Corday E: Assessment of quantitative methods for 2-dimensional echocardiography. *Am J Cardiol* 52:396-401, 1983
- Folland ED, Parisi AF, Moynihan PF, Jones DR, Feldman CL, Tow DE: Assessment of left ventricular ejection fraction and volumes by real-time, two-dimensional echocardiography. A comparison of cineangiographic and radionuclide techniques. *Circulation* 60:760-766, 1979
- Edwards WD, Tajik AJ, Seward JB: Standardized nomenclature and anatomic basis for regional tomographic analysis of the heart. *Mayo Clin Proc* 56:479-497, 1981
- Topol EJ, Weiss JL, Guzman PA, Dorsey-Lima S, Blanck TJJ, Humphrey LS, Baumgartner WA, Flaherty JT, Reitz BA: Immediate improvement of dysfunctional myocardial segments after coronary revascularization: Detection by intraoperative transesophageal echocardiography. *J Am Coll Cardiol* 4:1123-1134, 1984
- Nishimura RA, Tajik AJ, Shub C, Miller FA Jr, Ilstrup DM, Harrison CE: Role of two-dimensional echocardiography in the prediction of in-hospital complications after acute myocardial infarction. *J Am Coll Cardiol* 4:1080-1087, 1984