

therapy, patients are reportedly able to maintain a near optimal state of analgesia with minimal sedation and few side effects.^{11,12} Based on these studies, opiate-related side effects (e.g., nausea, vomiting, constipation) would be expected to occur in about 10% of patients. Comparisons with conventional im therapy have revealed that most patients would prefer PCA.^{1,12} However, to achieve optimal results with PCA therapy, both the patient and the staff should understand the basic principles upon which the therapy is based. The potential for overdosing patients can be minimized if small bolus doses are used with a mandatory lockout (delay) interval between successive doses. Postoperative analgesic orders should specify the narcotic analgesic concentration, the dosage range in both mg (or µg) and ml, as well as the minimum lockout interval. Finally, special care must be taken to assure that the PCA system is properly set up to avoid potentially life-threatening complications.

REFERENCES

1. White PF: Use of a patient-controlled analgesia infuser for the management of postoperative pain; Patient-controlled Analgesia. Edited by Harmer M, Rosen M, Vickers MD. Oxford, Blackwell Scientific Publications, 1985, pp 140-148
2. Tan S, Cohen SE, White PF: Sufentanil for analgesia after cesarean

- section: Intravenous versus epidural administration. *Anesth Analg* 65:S158, 1986
3. Forrester WH Jr, Smethurst PWR, Kienitz ME: Self-administration of intravenous analgesics. *ANESTHESIOLOGY* 33:363-365, 1970
4. Sechzer PH: Studies in pain with analgesic demand system. *Anesth Analg* 50:1-10, 1971
5. Keeri-Szanto M: Apparatus for demand analgesia. *Can Anaesth Soc J* 18:581-582, 1971
6. Bennett RL, Batenhorst RL, Bivins BA, Bell RM, Graves DA, Foster TS, Wright BD, Griffen WO Jr: Patient-controlled analgesia: A new concept of postoperative pain relief. *Ann Surg* 195:700-705, 1982
7. White DC, Pearce DJ, Norman J: Postoperative analgesia: A comparison of intravenous on-demand fentanyl with epidural bupivacaine. *Br Med J* 2:166-167, 1979
8. Tamsen A, Hartvig P, Fagerlund C, Dahlström B, Bondesson U: Patient-controlled analgesia therapy: clinical experience. *Acta Anaesthesiol Scand* 74:157-160, 1982
9. Rosenberg PH, Heino A, Scheinin B: Comparison of intramuscular analgesia, intercostal block, epidural morphine, and on-demand iv fentanyl in the control of pain after upper abdominal surgery. *Acta Anaesthesiol Scand* 28:603-607, 1984
10. Gibbs MM, Johnson HD, Davis FM: Patient administration of iv buprenorphine for postoperative pain relief using the Cardiff demand analgesia apparatus. *Br J Anaesth* 54:279-284, 1982
11. Graves DA, Foster TS, Batenhorst RL, Bennett RL, Baumann TJ: Patient-controlled analgesia. *Ann Intern Med* 99:360-366, 1983
12. Lehmann KA, Gördes B, Hoeckle W: Postoperative on-demand analgesie mit morphin. *Anaesthesist* 34:494-501, 1985

Anesthesiology
66:83-85, 1987

Failure of Double-lumen Endobronchial Tube Placement: Congenital Tracheal Stenosis in an Adult

SHIGEYUKI SAITO, M.D.,* SHUJI DOHI, M.D.,† KEIICHI TAJIMA, M.D.‡

Because of its large diameter and the limited availability of sizes, there may be some adult patients in whom a double-lumen endobronchial tube (DLEBT) is difficult to insert into their trachea and bronchi. A recent report indicates that a patient with an aortic aneurysm can be such a case.¹ We have experienced a similar case in which a dissecting thoracic aneurysm compressed the trachea and left main bronchus so that the placement of DLEBT could be performed only with the aid of a fiberoptic broncho-

scope. It is possible that patients with narrowing of the vocal cord, tracheal stenosis resulting from thyroid or/and mediastinal tumor or previous tracheostomy may also present difficulties when a double-lumen tube is used in the airway.² In those cases, however, difficulties associated with DLEBT intubation can probably be predicted by routine chest roentgenogram and anticipating the medical and clinical conditions of each patient before anesthesia. Recently, in a patient who needed DLEBT for lung surgery, we were unable to insert a DLEBT into her trachea even though the smallest size was selected. This asymptomatic patient was finally diagnosed as having a congenital tracheal stenosis.

REPORT OF A CASE

A 45-yr-old woman who is a nonsmoker, 160 cm in height, and 59 kg in weight, with adenocarcinoma of the lung was scheduled for right lower lobectomy. Her medical history revealed no respiratory diffi-

* Assistant Professor.

† Associate Professor.

‡ Junior Resident.

Received from the Department of Anesthesiology, Institute of Clinical Medicine, University of Tsukuba, Sakuramura, Ibaraki 305, Japan. Accepted for publication August 18, 1986.

Address reprint requests to Dr. Saito.

Key words: Airways: congenital tracheal stenosis. Equipment: double-lumen endobronchial tube.

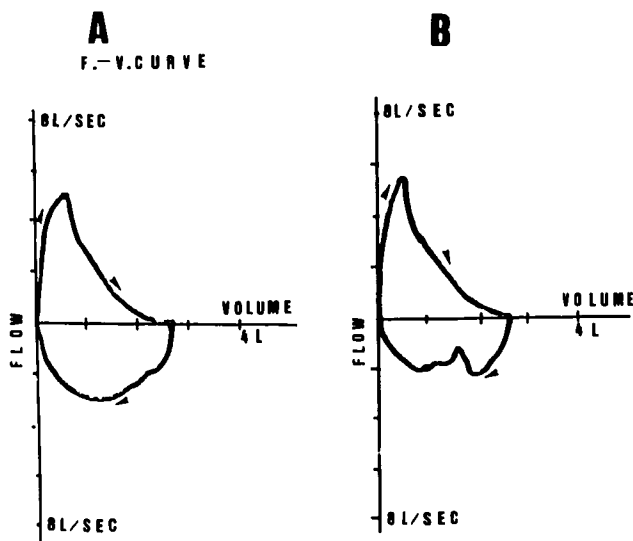


FIG. 1. The flow-volume curve (A) indicates peripheral airway obstruction rather than narrowing of the upper airway. The flow-volume curve was not improved by a bronchodilator (B).

culties, and she was not taking any medications. Pulmonary function studies showed that the flow-volume curve indicated that the presence of a small peripheral airway obstruction (fig. 1) and the forced expiratory volume in 1 s (FEV 1.0%) was reduced to 68% of the predicted volume, which was not improved by a bronchodilator (orciprenaline sulfate); however, bilateral breath sounds were equally clear. Chest radiographic and bronchofiberscopic examinations indicated a coin lesion of the right lower lobe with no abnormalities of the trachea and bronchus. Routine laboratory findings also were unremarkable.

The patient was premedicated with diazepam, 10 mg, orally. In addition to routine monitoring, a catheter was also inserted into the left radial artery for continuous monitoring of arterial blood pressure. Anesthesia was then induced with thiamylal, 4 mg/kg iv, and bronchotracheal intubation was facilitated by succinylcholine, 1.0 mg/kg, iv.

The glottis was exposed by direct laryngoscopy and a 37-Fr left-sided DLEBT (Bronchocath,® National Catheter Co., New York, NY) was inserted through the vocal cords and then rotated to the left, but the tube could not be advanced approximately 6 cm distal from the vocal cord. The tube was withdrawn, and manual ventilation was performed without any difficulty via a face mask. A smaller DLEBT (35-Fr) was then inserted into the trachea. Again this tube could not be advanced beyond 6 cm below the vocal cords. After removal of the tube, manual ventilation was performed without any problem. We then looked at a chest roentgenogram and found that the radiolucent portion related to the trachea was narrow between the 1st and 2nd thoracic vertebra. We then inserted a regular endotracheal tube (Portex,® 7 mm ID) into the trachea, 4 cm from the vocal cord, and manual ventilation was performed adequately without inflation of the cuff. We performed tracheal endoscopy through the tracheal tube using a fiberoptic bronchoscope 4 mm OD (Olympus BF® 3C10); this examination revealed segmental stovepipe-like narrowing of the middle portion of trachea and normal appearance of the lower part of trachea, carina, and both main bronchi.

A right thoracotomy and right lower lobectomy were performed under general anesthesia (using N₂O, O₂, and enflurane) without difficulty. Macroscopic examination of the trachea by a surgeon indicated that the rigid trachea was due to the lack of its membranous portion ranging approximately 3 cm in length 4 cm above the carina. After the operation, there was no respiratory distress immediately following

tracheal extubation. The patient's postoperative course also was uneventful.

Postoperatively, chest anatomic surveillance was performed, including tomography and chest computed tomography. The results indicated that tracheal stenosis was due to segmental membranous portion deficiency (fig. 2).

DISCUSSION

A large DLEBT should be chosen for bronchial intubation to reduce air-flow resistance through the tube, to suction easily, to reduce a chance of inappropriate placement, and not to inflate cuffs excessively in order to minimize damage to the tracheal and bronchial mucosa.³⁻⁵

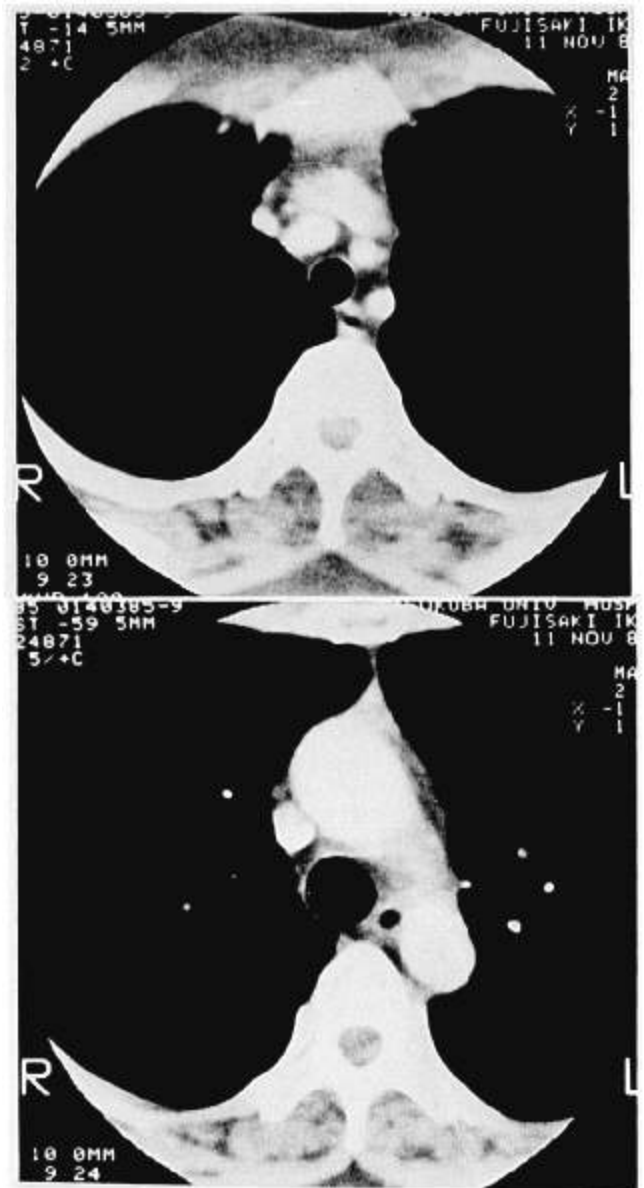


FIG. 2. Tracheal shape as shown by CAT scanning. (Upper) shape was at the 2nd thoracic vertebra level. (Lower) shape at the 4th thoracic vertebra level.

There are several causes for difficult insertion of the DLEBT into the trachea and bronchus, including thoracic aneurysm, peritracheal or intratracheal tumors and post-tracheostomized tracheal stenosis. In those cases, however, the difficulty should be predictable by clinical and radiographic examination.

Congenital tracheal stenosis is extremely rare.⁶⁻⁸ Tracheal stenosis is classified into three types: generalized hypoplasia; funnel-like stenosis; and segmental stenosis.⁷ The present patient had a mild segmental stenosis and thus had no symptoms or signs including stridor, wheezing, respiratory distress, or cyanotic attacks. The stenosis was so mild that no problems appeared during her development; however, her trachea did not have sufficient elasticity to allow passage of the DLEBT.⁹ We do not know the incidence of this abnormality in the general population. Although our patient is the only one in 158 consecutive patients in whom DLEBT was used for their surgery in our institute, this incidence may not reflect the overall incidence of the general population. From the examination of 111 cases of the cross-sectional shape of the adult trachea, Mackenzie *et al.*¹⁰ found that there were two cases of a circular trachea, which is an almost complete ring of cartilage with a small, practically nonexistent membranous portion.¹⁰

Although we accidentally found tracheal stenosis in the present patient, retrospective there were at least three preanesthetic clues. First, careful examination of the chest roentgenogram might have found tracheal stenosis, as we suspected it after failed events of the intubation. Second, a poor pulmonary function test result (low value of FEV 1.0%), which was not improved by a bronchodilator, with the absence of any obstructive lung disease, might have been reason to suspect an obstruction of the large airway.¹¹⁻¹³ The flow-volume loop would have helped in diagnosing the tracheal stenosis^{11,14} in the present case; however, it indicated some abnormalities in the peripheral airways rather than in the upper airway (fig. 1). Finally, after we found the abnormality in the present patient, an internist recalled an episode of marked respiratory distress during bronchofiberscopic examination with this patient. Because we were unable to insert a tracheal tube (7 mm ID, 10 mm OD, with cuff) beyond the stenotic portion of the trachea, the fiberscope of 5 mm OD must have obstructed more than one-half of the orifice of this portion of the trachea, and thus resulted in respiratory distress due to airway narrowing.

Fortunately, in our case, failure to insert the DLEBT into the trachea and bronchus was not detrimental to the safety of the anesthesia and surgery. We managed the airway of this patient with an endotracheal tube without any major difficulty. However, congenital tracheal stenosis may occasionally be present even though a medical history reveals no apparent airway problem. Thus, repeated failure of a recommended size of DLEBT to enter into the trachea and bronchus should be considered to indicate the presence of airway narrowing, probably due to congenital tracheal stenosis. In this situation, fiberoptic bronchoscopic examination is highly recommended.

REFERENCES

1. Cohen JA, Denisco RA, Richards TS, Staples ED, Roberts AJ: Hazardous placement of a Robertshaw-type endobronchial tube. *Anesth Analg* 65:100-101, 1986
2. Blanc VF, Trenblay NAG: The complications of tracheal intubation: A new classification with a review of the literature. *Anesth Analg* 53:202-213, 1974
3. Wilson RS: Endobronchial intubation, *Thoracic Anesthesia*, Edited by Kaplan JA. New York, Churchill Livingstone, 1983, pp 389-402
4. Wagner DL, Gammage GW, Wong ML: Tracheal rupture following the insertion of a disposable double-lumen endotracheal tube. *ANESTHESIOLOGY* 63:698-700, 1985
5. Brodsky JB, Shulman MS, Mark JBD: Malposition of left-sided double-lumen endobronchial tubes. *ANESTHESIOLOGY* 62:667-669, 1985
6. Cantrell JR, Guild HG: Congenital stenosis of the trachea. *Am J Surg* 108:297-305, 1964
7. Benjamin B, Pitkin J, Cohen D: Congenital tracheal stenosis. *Ann Otol* 90:364-371, 1981
8. Landing BH, Dixon LG: Congenital malformations and genetic disorders of the respiratory tract (larynx, trachea, bronchi, and lungs). *Am Rev Resp Dis* 120:151-185, 1979
9. Croteau JR, Cook CD: Volume-pressure and length-tension measurements in human tracheal and bronchial segments. *J Appl Physiol* 16:170-172, 1961
10. Mackenzie CF, McAslan TC, Shin B, Schellinger D, Helrich M: The shape of the human adult trachea. *ANESTHESIOLOGY* 49:48-50, 1978
11. Empey DW: Assessment of upper airways obstruction. *Br Med J* 3:503-505, 1972
12. Gal TJ: Tests of minimal obstruction in the small airways: Interrelationships and physiologic significance. *Anesth Analg* 56:242-254, 1977
13. Hensley MJ, O'Cain CF, McFadden ER, Ingram RH: Distribution of bronchodilatation in normal subjects: Beta agonist *versus* atropine. *J Appl Physiol* 45:778-782, 1978
14. Bergman NA: New tests of pulmonary function: Physiologic basis and interpretation. *ANESTHESIOLOGY* 44:220-229, 1976