

Anesthesiology
66:89-91, 1987

Carcinoid Crisis during Anesthesia: Successful Treatment With a Somatostatin Analogue*

H. MICHAEL MARSH, M.B., B.S.,† J. KIRK MARTIN, JR., M.D.,‡ LARRY K. KVOLS, M.D.,§
DOUGLAS R. GRACEY, M.D.,¶ MARK A. WARNER, M.D.,** MARY E. WARNER, M.D.,**
CHARLES G. MOERTEL, M.D.,††

Carcinoid syndrome, first described in 1954,¹ is classically characterized by episodic flushing of the face and upper body, with telangiectasia, chronic watery diarrhea, wheezing, and evidence of right-sided valvular heart disease. The syndrome results from ectopic hormonal production by carcinoid tumors, arising from epithelial argentaffin cells of entodermal origin. These tumors may, therefore, be seen in structures arising from the foregut (thymus, bronchi, stomach, and pancreas) and midgut or hindgut² and are members of the amine precursor uptake and decarboxylation (APUD) system.³ During anesthesia or operation, or during an attack of flushing, profound hypotension may occur, an event called "carcinoid crisis."⁴ We describe a patient with a carcinoid crisis during anesthesia, in which the crisis was reversed by the administration of a somatostatin analogue.

REPORT OF A CASE

A 53-yr-old woman was seen initially in April 1983 for further evaluation and treatment of metastatic malignant carcinoid. She had first noted symptoms of palpitations, loose watery stool, blotchy erythema, and episodic flushing 14 months previously. At that time, the output of urinary 5-hydroxyindoleacetic acid (5-HIAA) was 123 mg/24 h (normal, <6 mg/24 h). Radiographic wire-guided percutaneous liver biopsy conformed the diagnosis of carcinoid tumor metastatic to liver, and echocardiography revealed a normal heart. Cyproheptadine, 4 mg three times a day, was prescribed. At examination, the patient weighed 90.3 kg and was 166 cm tall.

She was followed until April 1985. During this time, she experienced abdominal cramping with two to four stools and three to four flushing episodes each day. The 24-h urinary excretion rates of 5-HIAA are

shown in table 1. Her symptoms continued to worsen, and she had found it necessary to stop drinking coffee and had given up her job. Her weight had decreased to 82.3 kg, and symptoms and signs of intermittent, partial small-bowel obstruction were noted. Cardiac symptoms had not developed, and her electrocardiogram was unchanged and normal. Heart rate was 88 beats/min and arterial blood pressure 110/80 mmHg. The 24-h urinary 5-HIAA excretion had increased to 417 mg. Radiographic contrast study of the small bowel and mesenteric arteriography revealed a fixed, nondistensible segment of terminal ileum and a 5 × 7 cm vascular mass in the right side of the abdomen supplied by the ileocolic artery. The liver was diffusely enlarged and replaced by multiple large vascular metastatic lesions.

The patient underwent operation for resection of the primary tumor in the terminal ileum, relief of the partial small-bowel obstruction, ligation of the hepatic artery,⁵ and cholecystectomy. For visceral angiography two days previously, she had received 10 mg of diazepam and 100 µg of fentanyl iv in divided doses and had an uneventful course. She had previously undergone uneventful general anesthesia for tubal ligation in 1960, dilatation and curettage of the uterus in 1967, and hysterectomy in 1976.

She was given 10 mg of diazepam orally 1 h before operation, and 375-mg of thiopental iv for induction of anesthesia. Succinylcholine, 80 mg, and atracurium, 25 mg, were given sequentially iv to facilitate endotracheal intubation. Electrocardiographic monitoring (modified lead V₅), precordial stethoscopy, arterial blood pressure monitoring by cuff around the upper arm, and a subclavian catheter for central venous pressure monitoring were used. Anesthesia was maintained with isoflurane (1% inspired) and nitrous oxide (2 l/min) in oxygen (2 l/min), supplemented with fentanyl (50 µg/iv). The systolic blood pressure decreased from 110 to 100 mmHg, but appeared stable. An esophageal stethoscope and a nasogastric tube were placed. Five minutes after induction of anesthesia, the anterior abdominal wall was exposed and scrubbed with povidone-iodine. At this time, a red flushing was seen on the abdominal wall and on the patient's upper body. Her peripheral arterial blood pressure decreased and became unattainable by sphygmomanometer; there were no palpable peripheral pulses, and her heart rate increased to 140 beats/min (fig. 1). During the next 10 min, she was given an iv bolus of 1,000 ml of 5% dextrose in lactated Ringer's solution, 140 µg of phenylephrine, 1 g of calcium chloride, and 1 mg of epinephrine. Despite these efforts, the only palpable pulses were in the carotid vessels. With epinephrine, electrocardiographic evidence of ventricular tachycardia developed (160 beats/min), which responded to 50 mg of lidocaine by returning to normal sinus rhythm. Repeated attempts at percutaneous insertion of an arterial catheter and even *via* a radial artery cutdown failed to result in a functional radial artery catheter. The cutdown site was bloodless, and the patient was showing pronounced peripheral cyanosis.

At this point, the situation appeared to be desperate, although cardiac action persisted and carotid pulsation remained palpable. After obtaining appropriate permission for compassionate use of an experimental drug, we administered two doses of 50 µg of somatostatin analogue iv. Within 40 s, peripheral flow resumed, the radial cutdown site began to bleed, and arterial puncture was accomplished. Arterial blood gas analysis revealed Pa_O₂ 394 mmHg, Pa_{CO}₂ 46 mmHg, and

* Sandoz 201-995. Supplied by Sandoz, Inc., East Hanover, New Jersey.

† Associate Professor of Anesthesiology.

‡ Assistant Professor of Surgery.

§ Assistant Professor of Oncology.

¶ Professor of Medicine.

** Instructor in Anesthesiology.

†† Professor of Oncology.

Received from the Departments of Anesthesiology, Surgery, and Oncology, Mayo Clinic and Mayo Foundation, Rochester, Minnesota 55905. Accepted for publication August 18, 1986. Supported in part by Grant CA-31224 from the National Institutes of Health, Public Health Service.

Address reprint requests to Dr. Marsh: Mayo Clinic, 200 First Street SW, Rochester, Minnesota 55905.

Key words: Sympathetic nervous system; carcinoid syndrome; somatostatin analogue.

TABLE 1. Urinary 5-HIAA* Excretion Rates in Carcinoid Syndrome

Date	5-HIAA (mg/24 h)	Event	Body wt (kg)
1/82	123	Diagnosis Biopsy	90.3
4/83	191		
6/83	205		
8/83	217		
10/83	199		
1/84	173	Small bowel obstruction Surgery	85.9
6/84	258		
11/84	242		
4/85	319, 298, 288		
5/1/85	417		
5/2/85	750	84.0	
5/4/85	187		
5/7/85	24		
5/13/85	10		
			82.0

* 5-Hydroxyindoleacetic acid: normal, <6 mg/24 h.

pH_a 7.13, with a base deficit of -13 mEq/l. Blood sugar was 400 mg/dl (Chemstrip® analysis). She was given NaHCO₃ (100 mEq), and the abdominal operation was begun shortly thereafter, with hepatic artery ligation being done first. Analysis of arterial blood after ligation of the hepatic artery revealed metabolic acidosis.

Systolic arterial blood pressure was sustained above 100 mmHg for the remainder of the operation, and she awoke before being returned to the intensive care unit. Ventilation was controlled initially for 24 h, and then the trachea was extubated. Urinary 5-HIAA excretion was 750 mg/24 h on the first postoperative day. Eight hours after extubation, supraventricular tachycardia developed to 170 beats/min and there was a low cardiac index (1.52 l·min⁻¹·m⁻²), with hypoxemia and roentgenographic evidence of diffuse bilateral pulmonary infiltrates. The trachea was reintubated and a large alveolar-arterial oxygen tension gradient noted.

The infiltrates cleared during the next 24 h. Mechanical ventilation was maintained for 2 days. A catheter was placed in the pulmonary

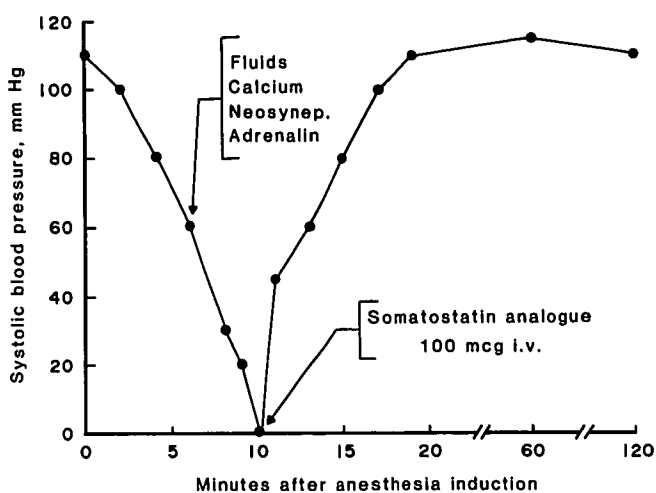


FIG. 1. Diagrammatic anesthesia record showing the period of crisis as a decrease in detectable peripheral blood pressure. Carotid pulsation was palpable at this time, and the electrocardiographic complex in modified lead V₅ was unchanged. Neosynep = phenylephrine; adrenalin = epinephrine.

artery 1 day postoperatively, and initially the pulmonary artery pressure was 39/24 mmHg, with a wedge pressure of 20 mmHg. This elevated pressure returned to normal the next day, and the wedge pressure decreased to 12 mmHg. Pulmonary angiography revealed multiple, small, bilateral pulmonary emboli to the left and right lower lobes. An echocardiogram revealed normal left ventricular size and function. The patient responded well to heparin and general supportive care, and somatostatin therapy was continued for 4 days. The 24-h excretion of 5-HIAA was 187 mg on postoperative day 3, 24 mg on postoperative day 6, and 10 mg on postoperative day 12. When dismissed from the hospital on the 14th day postoperatively, she was receiving sodium warfarin therapy.

DISCUSSION

Carcinoid tumors occur in approximately 8/100,000 persons.^{††} These tumors release any of various substances^{‡‡}: serotonin (5-hydroxytryptamine), 5-hydroxytryptophan, histamine, and pancreatic polypeptide. Release of prostaglandin and kallikrein, with increased synthesis of bradykinin, is also seen, together with release of at least 35 other peptides.⁶ Carcinoid syndrome is usually seen when hepatic metastasis is present, and crisis is a rare event.

The incidence of carcinoid crisis in anesthesia is low. The 410 surgical procedures on patients with carcinoid tumors at the Mayo Clinic from 1975 to 1985, including 24 undergoing ligation of the hepatic artery, there have been six reported reactions (including that of the current patient). Apart from our present reported patient, all others had mild bronchospasm or transient hypotension or both. The suggested management for such patients includes adequate preoperative hydration, possible premedication with an antihistaminic agent (for foregut tumors), use of antiserotonin agents such as cyproheptadine (for midgut tumors), or use of other blocking agents. Aprotinin, an agent that blocks the action of kallikrein, is potentially useful in the treatment of carcinoid crisis, but it is not readily available and its use remains experimental. Ketanserin, a selective 5-HT₂ serotonergic receptor blocking agent, may be of use in carcinoid syndrome and may prevent crisis.⁷ Glucocorticoids also may be given. None of these agents was used. Careful induction of anesthesia with avoidance of succinylcholine-induced fasciculation is also suggested.^{‡‡} In our patient, the use of atracurium and succinylcholine was combined. However, atracurium is potentially a histamine-releasing agent and may be better avoided. The flushing episode in our patient corresponded to vigorous abdominal scrubbing before surgical preparation and draping, and tumor stimulation may have been mechanical.

The initial treatment for the apparent hypotension in our patient was a rapid iv fluid infusion, followed by an

†† Miller JD: Carcinoid syndrome and the APUD concept. *Semin Anesthesiology* 3:228-237, 1984.

intermittent administration of phenylephrine. When this failed to achieve a palpable radial or brachial pulse and carotid pulsation was becoming less distinct, epinephrine and calcium were given. In retrospect, this selection may have been deleterious. Ventricular tachycardia did develop. Theoretically, the use of epinephrine should be avoided, because further mediator release may be produced. The crisis may be a vasoconstrictive event with central aortic hypertension, and vasodilators may be the best first-line drugs. Confirmation of this hypothesis would require measurement of intraaortic pressure.

Somatostatin, a tetradecapeptide growth-hormone-release-inhibiting factor, detected first in 1968 by Krulich *et al.*,⁸ is common among vertebrate and invertebrate organisms and among tissues in humans.⁹ Somatostatin-binding receptors have been identified in pituitary cells, pituitary plasma membrane, brain synaptosome membranes (particularly in cerebral cortex),¹⁰ and pancreatic islet cells.⁹ Somatostatin reduces membrane permeability to calcium, and the somatostatin effect can be blocked by an ionophore such as A23187, which opens calcium channels.⁹ In addition to blocking the pituitary release of growth hormone and thyrotropin, somatostatin has a wide range of actions in the gut, reducing hormonal and exocrine secretions, inhibiting motor activity, and decreasing absorption from the gut and blood flow to the gut.¹¹ Somatostatin also is active in regulating the secretion of the pancreatic islet cells and inhibiting the secretions of insulin, glucagon, and somatostatin itself. Somatostatin is one of the 35 or more peptides that are released from APUD cells, and somatostatinoma has been described.⁹ That somatostatin inhibits the carcinoid flush and promptly reduces the blood levels of serotonin was first suggested by Frölich *et al.*¹²

More recently, a synthetic somatostatin analogue (Sandoz 201-995), an octapeptide that retains the essential biologically active moiety of somatostatin in a conformationally stabilized form, has been found to be effective in relieving both the flushing and the diarrhea in patients with the carcinoid syndrome. The drug also reduces the urinary 5-HIAA levels. §§ As we had hoped, this drug was effective in the treatment of the carcinoid crisis in our

patient. However, the postoperative reduction in urinary 5-HIAA and symptoms was considered to be secondary to hepatic artery ligation.⁵

The rapid and sustained reversal of our patient's carcinoid crisis was dramatic, and the use of the drug was lifesaving, in our opinion. We recommend that the somatostatin analogue be available for emergency use in patients with the malignant carcinoid syndrome who are undergoing operation. Prophylactic use also could be considered.

This patient was previously described in a letter to the *New England Journal of Medicine*.¹³

REFERENCES

1. Thorson Å, Björck G, Björkman G, Waldenström J: Malignant carcinoid of the small intestine with metastases to the liver, valvular disease of the right side of the heart (pulmonary stenosis and tricuspid regurgitation without septal defects), peripheral vasomotor symptoms, bronchoconstriction, and an unusual type of cyanosis: A clinical and pathologic syndrome. *Am Heart J* 47:795-817, 1954
2. Williams ED, Sandler M: The classification of carcinoid tumours. *Lancet* 1:238-239, 1963
3. Pearse AG: APUD: Concept, tumours, molecular markers and amyloid. *Mikroskopie* 36:257-269, 1980
4. Kahil ME, Brown H, Fred HL: The carcinoid crisis. *Arch Intern Med* 114:26-28, 1964
5. Martin JK Jr, Moertel CG, Adson MA, Schutt AJ: Surgical treatment of functioning metastatic carcinoid tumors. *Arch Surg* 118:537-542, 1983
6. Nasjletti A, Malik KU: Relationships between the kallikrein-kinin and prostaglandin systems. *Life Sci* 25:99-109, 1979
7. Vanhoutte PM, Van Nueten JM: Ketanserin—a novel antihypertensive drug. *J Pharm Pharmacol* 35:339-340, 1983
8. Krulich L, Dhariwal APS, McCann SM: Stimulatory and inhibitory effects of purified hypothalamic extracts on growth hormone release from rat pituitary *in vitro*. *Endocrinology* 83:783-790, 1968
9. Reichlin S: Somatostatin. *N Engl J Med* 309:1495-1501; 1556-1563, 1983
10. Maurer R, Reubi J-C: Somatostatin receptors. *JAMA* 253:2741, 1985
11. Gerich JE: Somatostatin, *Handbook of Diabetes Mellitus*, vol. 1. Edited by M Brownlee. New York, Garland STPM Press, 1981, pp 297-354
12. Frölich JC, Blooargarden ZT, Oates JA, McGuigan JE, Rabinowitz D: The carcinoid flush: Provocation by pentagastrin and inhibition by somatostatin. *N Engl J Med* 299:1055-1057, 1978
13. Kvols LK, Martin JK, Marsh HM, Moertel CG: Rapid reversal of carcinoid crisis with a somatostatin analogue (letter to the editor). *N Engl J Med* 313:1229-1230, 1985

§§ Kvols LK, Moertel CG, Schutt AJ, O'Connell MJ: A somatostatin analogue (SOM-AN) (Sandoz 201-995) in therapy of the malignant carcinoid syndrome (abstract). *Proc Am Soc Clin Oncol* 4:89, 1985.