

Anesthesiology  
66:106, 1987

## Bradycardia following Sufentanil-Succinylcholine

To the Editor:—We read with interest the clinical report of Starr *et al.*,<sup>1</sup> which described the occurrence of bradycardia and asystole following administration of sufentanil and vecuronium to patients undergoing coronary artery bypass grafting. The authors raised as possibilities the interactions of these two drugs, their shared interaction with calcium-channel and/or beta-adrenergic blocking drugs given preoperatively, or vagal effects from laryngoscopy or from sufentanil alone, when given rapidly in large doses.

We have also observed sinus bradycardia, second degree heart block, and sinus arrest in patients anesthetized with sufentanil, though in small doses, where no calcium-channel or beta-adrenergic blocking drugs were used. Illustrative is the case of a 43-yr-old 64 kg woman, healthy except for mild hypothyroidism treated with thyroid extract, who presented for lumbar laminectomy (fig. 1). She was premedicated with morphine 8 mg and droperidol 1.25 mg IM 45 min prior to induction. While receiving oxygen by mask, she was given d-tubocurarine 3 mg iv and sufentanil 50 mcg ( $0.8 \text{ mcg} \cdot \text{kg}^{-1}$ ) iv in two divided doses 3 min apart. She was then anesthetized with thiopental 200 mg iv and given succinylcholine 120 mg iv in preparation for intubation. Prior to laryngoscopy, heart rate slowed precipitously from 88/min and asystole ensued. Endotracheal intubation and ventilation with 100% oxygen were quickly accomplished while, simultaneously, atropine 0.8 mg was given iv. Normal sinus rhythm at 54/min returned after approximately 15 s, but second degree heart block with variable conduction ap-

peared intermittently over the next two minutes until sinus rhythm at 88/min occurred. The remainder of the  $\text{N}_2\text{O}-\text{O}_2$ -isoflurane anesthetic was uneventful.

We agree with the authors and others<sup>2</sup> that sufentanil, like fentanyl, tends to slow heart rate, presumably by increasing vagal tone. The authors' assertion that the combination of sufentanil and vecuronium leads to bradycardia is correct, we feel, insofar as sufentanil's rate-slowing tendency is not opposed by vagolysis, as would be the case with pancuronium. The effect upon heart rate of sufentanil in combination with succinylcholine, as occurred in the case cited above, is unknown. Conceivably, the combination of sufentanil-enhanced parasympathetic tone and succinylcholine-induced ganglionic stimulation could result in additive vagal effects.

ELDEN P. SHERMAN, M.D.  
PHILIP W. LEBOWITZ, M.D.  
WILLIAM C. STREET, M.D.  
*Department of Anesthesiology  
Goddard Memorial Hospital  
Stoughton, MA 02072*

## REFERENCES

1. Starr NJ, Sethna DH, Estafanous FG: Bradycardia and asystole following the rapid administration of sufentanil with vecuronium. *ANESTHESIOLOGY* 64:521-523, 1986
2. DeLange S, Boscoe MJ, Stanley TH, Pace N: Comparison of sufentanil- $\text{O}_2$  and fentanyl- $\text{O}_2$  for coronary artery surgery. *ANESTHESIOLOGY* 56:112-118, 1982

(Accepted for publication September 30, 1986.)

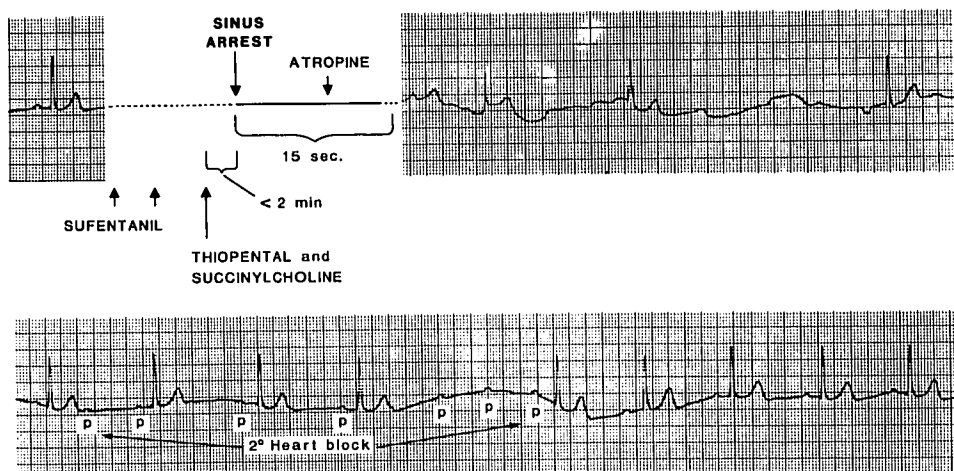


FIG. 1. Electrocardiographic tracing which depicts the development of sinus bradycardia and second degree heart block and the return to normal sinus rhythm following atropine administration in the patient reported.