

Anesthesiology  
66:221-223, 1987

## A Jet-stylet Endotracheal Catheter for Difficult Airway Management

RICHARD C. BEDGER, JR., D.M.D., M.D.,\* JUEI-LING CHANG, M.D.†

### REPORT OF TWO CASES

In providing anesthesia for head and neck surgery, the management of patients with severely compromised upper airways is common. In most instances this situation is secondary to edema and/or tumor of the tongue, pharynx, or glottis. In some cases severe anatomic distortion has occurred due to prior resection of masses involving these structures. To assure the safety and ease of management of patients with these and other anomalies, we have developed a "jet-stylet" endotracheal catheter.

The catheter consists of a 65-cm length of polyethylene tubing with a removable 15-mm adapter for connection to the anesthesia circuit or jet ventilator (fig. 1). This length is chosen to allow easy withdrawal or advancement of a standard endotracheal tube over the catheter while maintaining stable positioning of the catheter in the airway. Three marker rings are placed at 20 cm, 25 cm, and 30 cm from the distal end of the tube to allow determination of depth of placement into the airway. Three side ports are cut into the distal 5 cm of the tube to prevent tissue trauma from whipping of the catheter with jet ventilation or trauma when suction is applied. The external diameter of the tubing is 4.52 mm (0.178 in); thus, it can be used as a stylet for any endotracheal tube of size 5.0 mm internal diameter or greater. It can also be attached to standard suction tubing to evacuate serous secretions.

After institutional review, the jet-stylet endotracheal catheter has been used clinically at our hospital for approximately 2 yr. All attempts at intubation over the catheter have been successful. It has been used for intubation or reintubation of the trachea in 59 patients without complication. In situations where the catheter has been used for insufflation or jet ventilation, it has functioned adequately. In a series of six patients, jet ventilated *via* the catheter, normocarbia was maintained and oxygenation was adequate as determined by analysis of arterial blood gases. The following are summaries of two specific cases where the catheter proved useful.

*Patient 1.* A 40-yr-old woman with a 40 pack-year history of smoking and hypertension was admitted with the complaint of dysphagia. The patient was obese, with a short, thick neck, and was known to have a lesion of the base of the tongue. The patient was scheduled for a panendoscopy. After induction of anesthesia, ventilation could be maintained without difficulty, but when laryngoscopy was attempted the tumor was found to involve the epiglottis and pyriform fossa as well as the tongue base. The glottis could not be visualized with either the MacIntosh or Miller blade and intubation of the trachea could not be accomplished. Exposure of the larynx was only possible with the use of a rigid bronchoscope. The jet-stylet catheter was then advanced through the lumen and the bronchoscope was removed. After a brief period of jet ventilation, the trachea was intubated with a 6-cm endotracheal tube *via* the catheter. Panendoscopy was then performed without difficulty and when spontaneous ventilation was adequate postoperatively, the jet-stylet was placed through the endotracheal tube prior to its removal. Only after 30 min of observation without evidence of respiratory distress and analysis of arterial blood gases was the catheter removed. The patient underwent an extensive surgical procedure for treatment of a squamous cell carcinoma at a later date.

*Patient 2.* A healthy 18-yr-old man was scheduled for maxillary and mandibular reconstruction. Induction of anesthesia was without complication, as was the nasotracheal intubation. The mandibular osteotomies were performed without difficulty; however, near the completion of the maxillary osteotomy the surgeon cut the endotracheal tube, resulting in deflation of the cuff and an intolerable airway leak. The surgical field was covered with sterile drapes and the jet-stylet was placed through the orifice of the damaged tube prior to its removal. After a brief period of jet ventilation, the nasotracheal tube was replaced over the jet-stylet without disturbance of the osteotomy segments or the surgical field. The remainder of the procedure went without difficulty.

### DISCUSSION

The "jet-stylet" endotracheal catheter is of benefit in numerous difficult clinical situations. Even when there are no other abnormalities but the larynx is positioned anteriorly and the glottic opening can not be visualized directly, a 5.0-mm or 6.0-mm uncuffed tube can often be passed blindly; however, this tube would be inadequate with regard to resistance to ventilation and airway protection for a case of any significant duration. Therefore, after the initial intubation an exchange of tubes can be performed over the stylet. This is similar to the technique described by Salem *et al.*<sup>1</sup> and Tahir and Renegar.<sup>2</sup> Finucane and Kupshik<sup>3</sup> described a technique similar to that used for patient 2 in a patient with a cervical spine injury. However, they did not modify their catheter for airway maintenance or ventilation. When the airway is severely distorted by previous radical head and neck surgery, a

\* Assistant Professor of Anesthesiology/CCM.

† Associate Professor of Anesthesiology/CCM.

Received from the Department of Anesthesiology, University of Pittsburgh, Pittsburgh, Pennsylvania. Accepted for publication September 4, 1986.

Address reprint requests to Dr. Bedger: Eye and Ear Hospital, Department of Anesthesiology, 230 Lothrop Street, Pittsburgh, Pennsylvania 15213.

Key words: Intubation, endotracheal: technique.

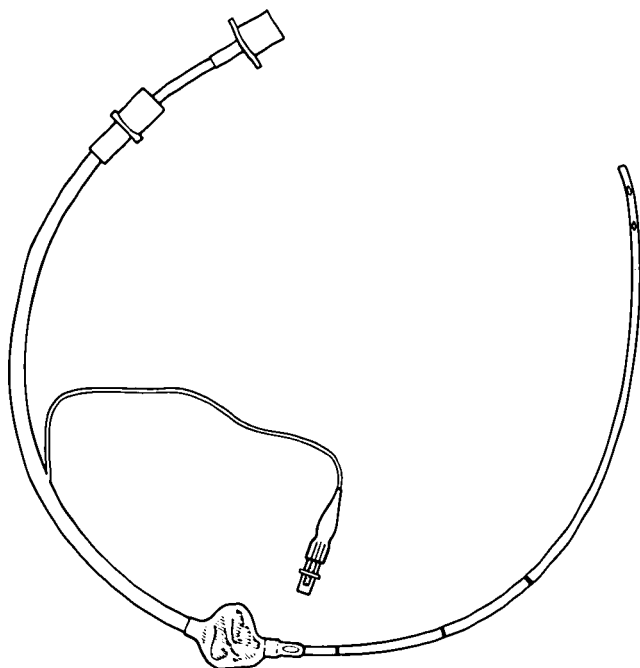


FIG. 1. Jet-stylet catheter placed through a 5.0-mm endotracheal tube demonstrating distal side ports and circumferential marks at 20, 25, and 30 cm to assist in positioning. The proximal 15-mm adapter is detachable for advancing and removing the endotracheal tube.

similar technique may be valuable. If problems arise, the patient can be ventilated by intermittent positive-pressure ventilation (IPPV) or Jet technique at any point after the catheter is in place. As noted earlier, we have also found ourselves in situations where the only way to find and/or visualize the glottic opening was *via* the surgeon's bronchoscope, anterior commissure, or Jackson laryngoscope. In this case the stylet catheter was inserted into the trachea through the scope, the scope withdrawn, and the endotracheal tube placed over the stylet. In the past a wire stylet<sup>4</sup> or a pediatric endotracheal tube<sup>5</sup> has been used in a similar manner.

If a retrograde intubation technique becomes necessary, the usual procedure is to use an epidural catheter as a stylet.<sup>6</sup> Unfortunately, passing a reasonably sized endotracheal tube over the small diameter, very flexible epidural catheter may be difficult because the tube tends to "hang up" on irregular tissue masses or at the glottic opening. We have found it is far easier to pass the jet-stylet over the epidural catheter, remove the catheter, then follow with the endotracheal tube; thus, we have accomplished the objective with two successive smooth cannulations similar to the Seldinger iv technique.

The clinical situation where we have found the catheter most valuable is in the postlaryngoscopy/bronchoscopy recovery period of patients with pharyngeal/glottic tumors with associated edema, some degree of bleeding,

and trauma from the procedure and biopsy. Most frequently these procedures are done with a 5.0-mm cuffed endotracheal tube in place. Our surgeons seldom perform tracheostomy at the time of panendoscopy; therefore, we are often faced with the question of whether we can safely extubate the trachea postoperatively. If there is no significant bleeding in the airway and the patient is breathing spontaneously, our routine has been to deflate the endotracheal tube cuff. This decreases the resistance of breathing by allowing the patient to breathe around the small-diameter tube, provided the airway is not severely constricted and is being maintained only by the presence of the endotracheal tube. This can be determined by examining for air flow from the nose and/or mouth during exhalation. The real problem arises when the patient is not breathing around the tube. In the past, this situation was dealt with by a "trial-by-fire" approach. All appropriate instruments, tubes, and equipment were made ready, and the trachea was extubated. Several near disasters and a few true disasters occurred. One of these near disasters was the stimulus for the design of the jet-stylet catheter. Now, the tracheas of such patients are extubated only after the catheter has been placed through the endotracheal tube. Air may be insufflated through the tube. A face mask can also be positioned if desired with the catheter passing through the side port. If stridor or edema are present, nebulized racemic epinephrine can be administered around the catheter. Nebulized lidocaine can also be given if the airway is irritable. If the patient begins to demonstrate fatigue and respiratory distress, assistance can be given by jet ventilation or IPPV. When the patient is well oxygenated, the proximal adapter is removed and reintubation is performed over the stylet. If, however, the patient shows no distress and has adequate blood gas values after an appropriate trial period, the catheter can be used to suction any secretions and removed.

Another circumstance where this device can be of benefit is the safe tracheal extubation of patients with elaborate, bulky, or occlusive head and neck dressings. These dressings often restrict mouth opening, neck extension, and/or compress the airway. Competence of the airway postextubation can be assessed during a brief trial period with the catheter in place. If necessary, reintubation can be easily accomplished in spite of the above-mentioned restrictions.

The catheter can also be of value in intensive care units. It can be of benefit to clinicians not comfortable with their intubation skills when called on to change an endotracheal tube for any reason, such as cuff rupture. Even for the most skilled intensivists, the catheter may be helpful when dealing with a compromised airway in a patient with a critical respiratory status. Assurance of a patent airway, ease of endotracheal tube exchange, and a mech-

anism for continued ventilation/oxygenation using the catheter is beneficial in such patients.

The jet-styler endotracheal catheter can be a valuable tool in intubation or reintubation of patients with severely compromised airways while maintaining a pathway for positive pressure or jet ventilation.

#### REFERENCES

1. Salem MR, Mathrubhutham M, Bennett EJ: Difficult intubation. *N Engl J Med* 295:879-881, 1976
2. Tahir AH, Renegar OJ: A styler for difficult orotracheal intubation. *ANESTHESIOLOGY* 39:337-339, 1973
3. Finucane BT, Kupshik HL: A flexible stilette for replacing damaged tracheal tubes. *Can Anaesth Soc J* 25:153-154, 1978
4. Aro L, Takki S, Aromaa U: Technique for difficult intubation. *Br J Anaesth* 43:1081-1083, 1971
5. Handler SD, Keon TP: Difficult laryngoscopy/intubation: The child with mandibular hypoplasia. *Ann Otol Rhinol Laryngol* 92:401-404, 1983
6. Powell WF, Oxdil T: A translaryngeal guide for tracheal intubation. *Anesth Analg* 46:231-234, 1967

Anesthesiology  
66:223-226, 1987

## Effects of Fluid Therapy on Serum Glucose Levels in Fasted Outpatients

VAN A. DOZE, B.S.,\* PAUL F. WHITE, PH.D., M.D.†

Conventional preoperative management of outpatients involves fasting for 8-16 h prior to their scheduled operation. Whether these patients should be given glucose-containing fluids intravenously during surgery is controversial.<sup>1</sup> Although studies have determined serum glucose concentrations in fasted volunteers, diabetics, and inpatients undergoing major operations,<sup>1-5</sup> the incidence of hypoglycemia in a healthy adult outpatient surgery population after a prolonged fast is unknown. Furthermore, serum glucose concentrations have not been determined when fasted outpatients are not given glucose perioperatively. While glucose-containing fluids are often given during the perioperative period, the stress of surgery and anesthesia may produce a state of glucose "intolerance" (secondary to decreased glucose uptake and utilization).<sup>1,2,6</sup> Thus, the administration of an exogenous glucose load perioperatively may predispose the patient to developing hyperglycemia and glucosuria, enhancing fluid loss secondary to the osmotic diuresis.<sup>7,8</sup>

This study was designed to: (1) determine preoperative serum glucose levels in fasted young women undergoing elective outpatient surgery; (2) assess the effect of administering glucose-containing fluids intraoperatively (*vs* withholding glucose-containing fluid) on the postoperative serum glucose concentration; and (3) evaluate the effect

of orally administered glucose-containing solutions on the serum glucose level at the time of discharge.

#### MATERIALS AND METHODS

Fifty healthy, ASA physical status I or II, young women presenting for minor gynecological procedures were randomly assigned to one of two fluid treatment groups. All patients entered into this study had fasted for a period of at least 12 h (table 1). The control group (n = 25) received lactated Ringer's solution (LR) and the study group (n = 25) received dextrose 5% in lactated Ringer's solution (D<sub>5</sub>LR) intravenously during and immediately following outpatient surgery. The study was approved by the Committee on Human Research at Stanford University, and informed consent was obtained from each patient. Demographic data included age, weight, type of surgical procedure, duration of fasting (*i.e.*, the time from their last oral intake until their arrival in the operating room), and volume of intravenous (iv) fluid administered perioperatively. Patients with a history of glucose intolerance (*e.g.*, diabetes) or reactive hypoglycemia were excluded. Other exclusionary criteria included: pregnant women (where the surgery was not intended to terminate the pregnancy), morbid obesity (>30% of ideal body weight), and evidence of hepatic, renal, or metabolic disease.

The day prior to the operation, each patient underwent a routine physical examination and urinalysis. Patients were instructed to abstain from eating or drinking after midnight. On the day of surgery, the patients were taken to the operating room where an 18-g iv cannula was inserted into an arm vein. At that time, a fasting blood sample was obtained and an infusion of either LR or D<sub>5</sub>LR was started at a rate of 5-10 ml/min. All patients received meperidine, 1 mg/kg, iv, 3-5 min prior to induction of

\* Medical Student, Research Assistant in Anesthesia.

† Associate Professor, Chief of Outpatient Anesthesia Service.

Received from the Department of Anesthesia, Stanford University School of Medicine, Stanford, California 94305.

This paper was presented at the Annual Meeting of the American Society of Anesthesiologists in San Francisco, 1985.

Address reprint requests to Dr. Paul F. White, Department of Anesthesia, S-268C, Stanford University Medical Center, Stanford, CA 94305.

Key words: Blood: glucose. Surgery: outpatients. Urine: glucose.