

CLINICAL REPORTS

Ronald D. Miller, M.D., Editor

Anesthesiology
66:386-389, 1987

The Influence of Periaortic Collateral Vessels on the Intraoperative Hemodynamic Effects of Acute Aortic Occlusion in Patients with Aorto-occlusive Disease or Abdominal Aortic Aneurysm

WILLIAM E. JOHNSTON, M.D.,* FRANCIS J. BALESTRIERI, M.D., D.D.S.,* GEORGE PLONK, M.D.,†
VINCENT D'SOUZA, M.D.,‡ GEORGE HOWARD, M.S.P.H.§

During surgery on the abdominal aorta, acute aortic occlusion produces significant increases in vascular resistance and ventricular afterload.^{1-6,¶} Several studies have implied that patients with aorto-occlusive disease (AOD) have less hemodynamic derangements from aortic cross-clamping than patients with abdominal aortic aneurysm (AAA).^{3,4} However, whether the magnitude of this change is related to the extent of periaortic collateral vascularization present has not been examined in these patient groups.

We hypothesized that the development of periaortic collateral vessels to bypass the diseased aorta may lessen the hemodynamic stress from aortic cross-clamping. To test this hypothesis, we examined the hemodynamic changes at the time of acute aortic occlusion in patients with AAA and AOD, and correlated these intraoperative findings with the degree of periaortic collateral vascularization seen on preoperative aortograms.

METHODS

We prospectively studied 17 male and 5 female patients undergoing elective abdominal aortic surgery for abdominal aortic aneurysm (AAA) (mean age 58.3 ± 4.0 yr; $n=13$) and aorto-occlusive disease (AOD) (mean age 58.7 ± 3.5 yr; $n=9$). Catheters were inserted into the radial artery and pulmonary artery for intraoperative monitoring of the systolic and diastolic arterial pressures (SAP, DAP), pulmonary systolic and diastolic pressures (PSAP, PDAP), pulmonary artery wedge pressure (PAWP), central venous pressure (CVP), and mean cardiac output (Q_t), from triplicate injections of iced saline. Leads 2 and V_5 of the electrocardiogram (ECG) were monitored for intraoperative dysrhythmias and myocardial ischemia. Stroke volume (SV), mean arterial pressure (MAP), and systemic vascular resistance (SVR) were calculated using standard formulae.

All patients were premedicated with lorazepam 0.025 mg/kg po and morphine sulfate 0.1 mg/kg im; all patients received their routine cardiac medications (see "Results"). Anesthesia was induced with diazepam 0.15 mg/kg iv, metocurine iodine 20 mg iv, and N_2O-O_2 with 0.5-1.0% isoflurane as necessary, using controlled ventilation. Intraoperative fluid management before cross-clamping consisted of lactated Ringer's solution given at a rate to maintain PAWP at or slightly above baseline values. Parenteral fluid warmers and heat-moisture exchangers were used to maintain esophageal temperatures above 35° C.

Measurements of hemodynamic variables were limited to 1 min before and 1 min after the aorta was cross-clamped. Hemodynamic variables thereafter were altered by vasodilator therapy using nitroprusside or nitroglycerin infusions as deemed necessary by the attending anesthesiologist to maintain pre-clamp values of SVR.

Periaortic collateral vessels seen on preoperative aortograms were assessed by a vascular radiologist who did not know the outcome of the intraoperative study. The degree of periaortic collateral vascularization was quantitated as 0 = none, 1 = ilio-lumbar collateral vessels, 2

* Assistant Professor, Department of Anesthesia.

† Assistant Professor, Department of Surgery.

‡ Assistant Professor, Department of Radiology.

§ Assistant Professor, Center for Prevention Research and Biometry.

Received from the Departments of Anesthesia, Surgery, and Radiology, and the Center for Prevention Research and Biometry of the Wake Forest University Medical Center, Bowman Gray School of Medicine, Winston-Salem, North Carolina. Accepted for publication July 21, 1986. Presented at the 1985 Annual Meeting of the American Society of Anesthesiologists, San Francisco, October 12-19, 1985.

Address reprint requests to Dr. Johnston: Department of Anesthesia, Bowman Gray School of Medicine, 300 S. Hawthorne Road, Winston-Salem, North Carolina 27103.

Key words: Aorta: aneurysm; cross-clamp. Heart: afterload; stroke volume.

¶Roizen MF, Beaupre PN, Alpert RA, Kremer P, Cahalan MK, Shiller N, Sohn YJ, Cronnelly R, Lurz FW, Ehrenfeld WK, Stoney RJ: Monitoring with two-dimensional transesophageal echocardiography: Comparison of myocardial functions in patients undergoing suprarenal, suprarenal-infraceliac, or infrarenal aortic occlusion. *J Vasc Surg* 1: 300-305, 1984.

TABLE 1. Hemodynamic Effects from Acute Aorta Occlusion (mean ± SE)

	AAA (n = 13)		AOD (n = 9)	
	Before Clamp	After Clamp	Before Clamp	After Clamp
SAP (mmHg)	140 ± 7	159 ± 6*	131 ± 4	150 ± 8
DAP (mmHg)	76 ± 4	81 ± 4	66 ± 4	69 ± 4
CVP (mmHg)	9 ± 1	9 ± 1	10 ± 1	11 ± 1
PAWP (mmHg)	13 ± 1	14 ± 2	12 ± 2	14 ± 2*
SV (ml/beat)	73 ± 4	66 ± 4*†	64 ± 6	69 ± 6†
SVR (dyne · sec · cm ⁻⁵)	1403 ± 96	1777 ± 177*†	1507 ± 199	1563 ± 237†

* *P* < 0.05 compared to pre-clamp value.

† *P* < 0.05 comparing the change between groups.

= iliolumbar and superior hemorrhoidal collateral vessels, 3 = iliolumbar, superior hemorrhoidal, and internal mammary collateral vessels, and 4 = iliolumbar, superior hemorrhoidal, internal mammary, and lower intercostal collateral vessels. Periaortic collateral vascularization was then averaged for AAA and for AOD patients.

This study required patient consent and met the approval of the institution's clinical research practices committee. Data, expressed as mean ± standard error (SE), were analyzed between patient groups using paired *t* tests and within each group using a multivariate analysis of variance (MANOVA) for repeated measures, with *P* ≤ 0.05 being considered significant.

RESULTS

Preexisting cardiovascular disease as determined by history was present in both groups. In AAA and AOD patients respectively, the incidences of previous myocardial infarction were 15% and 33%; of angina, 23% and 56%; of hypertension, 38% and 67%; and of congestive heart failure, 15% and 11%. An abnormal ECG, defined as evidence of an old myocardial infarction or subendocardial ischemia, was found preoperatively in 25% of AAA patients and in 29% of AOD patients. Preoperative cardiac medications in AAA and AOD groups, respectively, consisted of nitrates in 38% and 31%, diuretics in 54% and 38%, beta adrenergic blockers in 38% and 25%, and calcium channel blockers in 8% and 0%. The anesthetic management and doses were similar in both groups of patients.

Before cross-clamping, there were no significant differences in any of the hemodynamic values measured between the two groups (table 1). At the time of aortic cross-clamping, MAP increased a similar amount in both the AAA (10 ± 5 mmHg) and the AOD (9 ± 5 mmHg) groups. SV decreased 7 ± 3 ml/beat in AAA patients (*P* ≤ 0.03), but increased 5 ± 4 ml/beat in the AOD group (*P* = 0.21) (table 1). The change in SV between the AAA and the AOD patients was significant (*P* ≤ 0.02). SVR increased

in AAA patients by 374 ± 143 dyne · sec · cm⁻⁵ (*P* ≤ 0.02), but remained unchanged with the AOD group. That difference between the two groups was also significant (*P* < 0.04). A similar number of patients in each group (5 AAA, 4 AOD) required vasodilator therapy 5-15 min after application of the clamp.

The degree of periaortic collateral vascularization seen on preoperative aortograms was 0.5 ± 0.2 for the AAA group and 2.6 ± 0.5 for the AOD group (*P* ≤ 0.001). Figure 1 shows the relationship between percent change in SVR and the degree of periaortic collateral vessels in both the AAA and the AOD patients. We found a strong relationship between the diagnosis (AAA or AOD) and the degree of collateral vascularization (*P* < 0.01), with the diagnosis explaining 49% of the variation in the degree of collateral vascularization (fig. 2). Both the diagnosis and the number of collaterals were related to the percent change in SVR (*P* = 0.05 and *P* = 0.04, respectively),

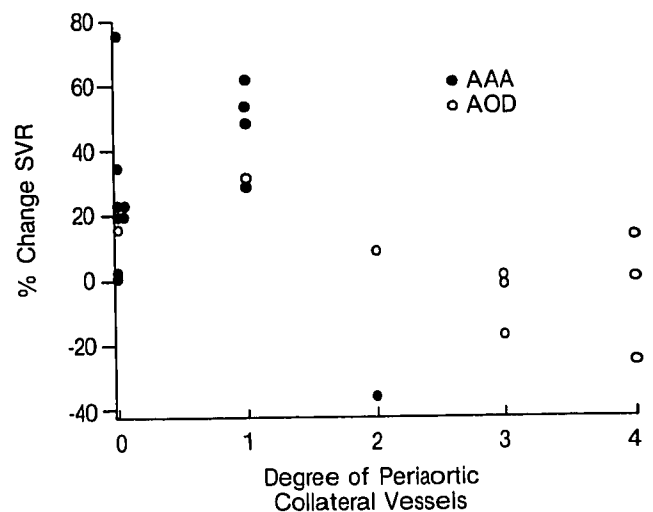


FIG. 1. Correlation between the percent change in SVR at aortic cross-clamping and the degree of periaortic collateral vascularization seen preoperatively for every AAA (n = 13) and AOD (n = 9) patients.

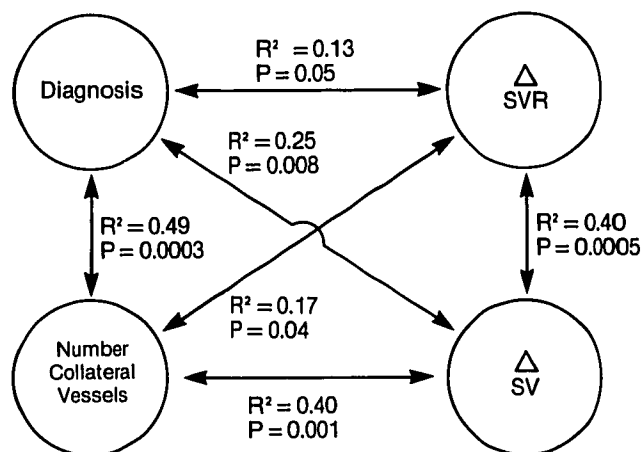


FIG. 2. Univariate relationships between the presenting diagnosis (AAA or AOD) and degree of preoperative collateral vascularization with the change in SVR and SV immediately after cross-clamping the aorta.

explaining 13% and 17% of the variation in SVR, respectively (fig. 2).

Both the diagnosis and the degree of collateral vascularization were related to SV ($P \leq 0.008$ and $P \leq 0.001$, respectively), explaining 25% and 40% of the variation in SV with cross-clamping, respectively. Combining the diagnosis with the number of collateral vessels failed to account for greater variability in the changes in SVR or SV.

All patients survived the operation, except one with AAA who died in the operating room of uncontrollable bleeding following repair. No patient had ECG evidence of a perioperative myocardial infarction; one patient from each group had new ECG evidence of subendocardial ischemia in the early postoperative period.

DISCUSSION

Patients presenting for abdominal aortic surgery commonly have underlying CAD, and myocardial infarction remains the most common cause of postoperative mortality.^{7,8} On the basis of coronary arteriography, the incidence of significant coronary stenosis varies from 33–47% of AOD patients and from 53–75% of AAA patients.^{7,9}

Infrarenal aortic cross-clamping imposes a stress on the myocardium by increasing SVR. During the period of cross-clamping, myocardial ischemia can be precipitated in 14–30% of AAA patients with CAD, as assessed by a change in ECG or an increase in PAWP.^{1,2} An even higher incidence has been found with transesophageal echocardiography when the aorta is clamped above the celiac axis.¹¹

Many studies examining the hemodynamic effects of aortic cross-clamping have not differentiated between AAA and AOD patients.^{2,5,10} Studies that do compare AAA patients with AOD patients show inconclusive results, with the suggestion that AOD patients may have less hemodynamic alterations with cross-clamping.^{3,4,6} Using a dye dilution technique to measure Q_1 , Meloche *et al.*⁵ and Dunn *et al.*⁴ found no significant differences in the increases in SAP and SVR and the decrease in Q_1 and SV between AOD and AAA groups studied 1–3 min after aortic cross-clamping. AAA patients, but not AOD patients, demonstrated persistent alterations in myocardial function at that stage during cross-clamping, alterations that the authors attributed to the presence of periaortic collateral vessels in the latter group, but mentioned no radiographic verification of such vessels.

Gooding *et al.*⁶ found that the magnitude of myocardial stress during cross-clamping of the abdominal aorta depended on the severity of CAD. In patients with known CAD, cross-clamping increased left ventricular stroke work index and increased PAWP from 13 ± 1 mmHg to 15 ± 1 mmHg ($P \leq 0.01$). Comparing AAA patients with AOD patients, Gooding *et al.* found a significant increase in SVR only in the AAA patients who were without CAD. The increases in SVR in AOD patients without CAD and in both groups with CAD were not significant. The authors did not comment on those differences in SVR within groups, nor attempt to correlate the number of periaortic collateral vessels with changes in SVR.

PAWP increased in the AOD patients with CAD in the study by Gooding *et al.*,⁶ as well as in the AOD patients in our study. This change might be interpreted as representing depressed myocardial function, except that all values for myocardial function remained within a clinically acceptable range. In addition, this subset of patients, compared to other patients, showed depressed myocardial function before, as well as after, aortic cross-clamping.⁶ Although an increase in left ventricular end-diastolic pressure can impede coronary blood flow,¹¹ DAP increased more than PAWP in our study in both patient groups. Consequently, without a change in heart rate, coronary perfusion pressure and blood flow to the left ventricular endocardium should be maintained. In our study, there was no evidence of myocardial ischemia manifested by intraoperative ECGs, by a change in PAWP waveform, or by postoperative infarction.

Using transesophageal two-dimensional echocardiography, Roizen *et al.*¹¹ found that cross-clamping the aorta above the celiac axis caused an increase in left ventricular end-diastolic volume, which was frequently not manifested by a similar change in PAWP. Intraoperative echocardiography may, then, represent a more sensitive indicator of ischemic myocardial dysfunction than ECG or changes

in hemodynamic variables. Further study is warranted, comparing AAA with AOD patients using intraoperative echocardiography and cross-clamping below the celiac axis.

On the basis of the changes in SVR and SV, less intraoperative hemodynamic stress from aortic occlusion was seen in the AOD patients in this study than in the AAA patients. We attribute this protective effect to the greater degree of periaortic collateral vascularization seen by preoperative aortography in the AOD group, and we believe that the amount of collateral vascularization seen on preoperative aortograms can selectively predict the magnitude of change in SV and SVR that will occur intraoperatively with cross-clamp application. However, since both groups of patients in our study subsequently required afterload reduction, invasive hemodynamic monitoring remains useful in CAD patients undergoing infrarenal aortic surgery.

REFERENCES

1. Attia RR, Murphy JD, Snider M, Lappas DG, Darling RC, Lowenstein E: Myocardial ischemia due to infrarenal aortic cross-clamping during aortic surgery in patients with severe coronary artery disease. *Circulation* 53:961-965, 1976
2. Carroll RM, Laravuso RB, Schauble JF: Left ventricular function during aortic surgery. *Arch Surg* 111:740-743, 1976
3. Meloche R, Pottecher T, Audet J, Dufresne O, LePage C: Haemodynamic changes due to clamping of the abdominal aorta. *Can Anaesth Soc J* 24:20-34, 1977
4. Dunn E, Prager RL, Fry W, Kirsh MM: The effect of abdominal aortic cross-clamping on myocardial function. *J Surg Res* 22: 463-468, 1977
5. Silverstein PR, Caldera DL, Cullen DJ, Davison JK, Darling RC, Emerson CW: Avoiding the hemodynamic consequences of aortic cross-clamping and unclamping. *ANESTHESIOLOGY* 50: 462-466, 1979
6. Gooding JM, Archie JP Jr, McDowell H: Hemodynamic response to infrarenal aortic cross-clamping in patients with and without coronary artery disease. *Crit Care Med* 8:382-385, 1980
7. Hertzner NR, Beven EG, Young JR, O'Hara PJ, Ruschhaupt WF III, Graor RA, DeWolfe VG, Maljovec LC: Coronary artery disease in peripheral vascular patients: A classification of 1000 coronary angiograms and results of surgical management. *Ann Surg* 199:223-233, 1984
8. Diehl JT, Cali RF, Hertzner NR, Beven EG: Complications of abdominal aortic reconstruction: An analysis of perioperative risk factors in 557 patients. *Ann Surg* 197:49-56, 1983
9. Tomatis LA, Fierens EE, Verbrugge GP: Evaluation of surgical risk in peripheral vascular disease by coronary arteriography: A series of 100 cases. *Surgery* 71:429-435, 1972
10. Cohen JL, Wender R, Maginot A, Cossman D, Treiman R, Foran R, Levin P, De Angelis J, Treiman G: Hemodynamic monitoring of patients undergoing abdominal aortic surgery. *Am J Surg* 146:174-177, 1983
11. Archie JP Jr: Transmural distribution of intrinsic and transmitted left ventricular diastolic intramyocardial pressure in dogs. *Cardiovasc Res* 12:255-262, 1978

Anesthesiology
66:389-391, 1987

Accidental Hyperthermia as a Complication of Extracorporeal Shock-wave Lithotripsy under General Anesthesia

THOMAS L. HIGGINS, M.D.,* ELLIOTT V. MILLER, M.D.,† JAMES ROBERTS M.D.‡

Extracorporeal shock-wave lithotripsy (ESWL) is a new treatment for renal calculi.^{1,2} We report an unusual and potentially dangerous hyperthermic complication.

* Clinical Fellow in Anesthesia, Harvard Medical School; Chief Resident in Anesthesia, Massachusetts General Hospital.

† Assistant Professor, Harvard Medical School; Anesthetist, Massachusetts General Hospital.

‡ Assistant Professor, Harvard Medical School; Associate Anesthetist, Massachusetts General Hospital.

Received from the Department of Anesthesia, Massachusetts General Hospital, Boston, Massachusetts 02114. Accepted for publication August 26, 1986.

Address reprint requests to Dr. Miller.

Key words: Anesthesia: complications. Extracorporeal Shock-Wave Lithotripsy (ESWL). Hyperthermia: accidental.

CASE REPORT

A 25-yr-old woman presented for ESWL treatment of a left lower pole renal calculus. The patient was allergic to codeine, meperidine, and oxycodone, but was otherwise healthy. She took no medication except for intermittent courses of trimethoprim-sulfamethoxazole. General anesthesia was induced with thiopental 5 mg/kg iv and the trachea was intubated after succinylcholine 1 mg/kg iv. No trismus was noted during intubation. Anesthesia was maintained with oxygen 1.0 l/min, nitrous oxide 2.0 l/min, and enflurane 1.5%. Anesthesia depth was judged as adequate by a stable arterial blood pressure and heart rate, and by lack of movement. After 30 min, treatment was interrupted for a routine electrode change. Despite the lack of stimulation, the heart rate gradually increased from a baseline of 80 to 95 bpm, with systolic arterial blood pressure decreasing slightly from 105 to 95 mmHg. The enflurane was decreased to 0.5% and the patient coughed. Fentanyl 50 µg was administered, and the enflurane increased to 2% when shock-wave treatment resumed. Despite increasing the concentration of enflurane, the heart rate continued to increase. The