

Thoracopagus Conjoined Twins: Management of Anesthetic Induction and Postoperative Chest Wall Defect

HARUMI HOSHINA, M.D.,* OSAMU TANAKA, M.D.,† HIDEFUMI OBARA, M.D.,‡ SEIZO IWAI, M.D.§

There are now numerous accounts of the separation of conjoined twins, and many aspects of anesthesia management have been discussed.¹⁻⁶ This report describes our experience with a set of thoracopagus twins, including a problem during induction of anesthesia and the management of postoperative chest wall defects in each twin.

REPORT OF A CASE

Female thoracopagus twins were born by Cesarean section at 38 weeks gestation. The Apgar scores at 1 min were 7. The twins' combined weight was 6100 gm, and both were in good condition. They were joined from the level of the 4th rib to the umbilicus by a large tissue mass, which measured 16 cm in length and 43.5 cm circumference. They had shared a single umbilical cord.

A gastrointestinal series revealed a normal alimentary tract in each infant with no communication. This, together with the fact that the stools of each infant contained bile pigment, suggested that each had separate alimentary and biliary system. A CT scan demonstrated fused livers in normal position. Intravenous pyelography and renogram on each infant showed normal kidneys and bladder. However, the contrast media which was given to one infant appeared in the other after a short delay, suggesting that there was some cross circulation. The twins revealed asynchronous pulses and two ventricular complexes on ECG, indicating that each twin had a separate individual heart. One twin had a heart murmur. Cineangiography and CT scan showed two separate hearts in a common pericardial sac. Hormone function tests suggested independent and normal function in the thyroid and adrenal cortex.

In summary, these preoperative examinations showed that the twins had a conjoined liver with separate biliary systems and separate hearts in a single pericardial sac.

The operation was performed when the twins were 2 months of age. The combined weight of the twins was 8500 gm on the day of surgery. An iv cannula and arterial line were inserted on the day before surgery. Atropine sulfate 0.08 mg im was given to each baby for premedication. ECG, rectal temperature, and direct arterial blood pressure were monitored during surgery.

An awake orotracheal intubation was performed on "twin B." However, coughing occurred with this intubation, resulting in "twin A"

becoming flushed and moving. Tachycardia and hypertension was noted in "twin A," and "twin B" then became pale and hypotensive. This state persisted until both babies were anesthetized with 50% nitrous oxide and given pancuronium iv. The trachea of "twin A," who was larger, but had a heart murmur and small chin, was intubated orally without any difficulty. Anesthesia was maintained with nitrous oxide and oxygen, plus intermittent low concentrations of enflurane. CVP was measured *via* an external jugular vein cannula in each twin.

The incision was made in the midline of the conjunction. A common pericardial sac in the thoracic cavities and independent intestines, and fused liver in the peritoneal cavities, were seen. The fused liver was carefully separated with cuser and electric cautery. Most of the total blood loss of both babies occurred during this procedure. Blood replacement was infused to maintain the CVP and hematocrit of each baby.

Following division of the liver, the pericardial sac was opened. The two hearts were completely independent, and "twin B's" heart lay superior to the other. The pericardial sac and diaphragms were incised, and the babies were completely separated. The vital signs and arterial blood gases were quite stable during separation. Hydrocortisone 50 mgs iv was given to each twin, in case one had inadequate adrenal function.

In "twin A," the defect of the pericardial sac was sutured, and the heart assumed a normal position within the chest cavity. A malrotation of the bowel was found, and a Ladd's procedure was performed. The abdominal wall was closed without difficulty. However, closure of the large chest wall defect, 13 × 9 cm in size to provide for the adequate respiratory movement, was impossible. We, therefore, used a thin Resin plate (polymerized methyl methacrylate: GC Co., Japan) which was sutured to the costal cartilages and diaphragm. This procedure was uneventful, and "twin A" continued in good condition with adequate peripheral circulation, but poor urine output. An increased iv infusion rate and 4 mg of furosemide iv were effective treatment.

"Twin B" was hypotensive, with an elevated CVP and a low PaO₂ (48 mmHg) just before transport to the second operating table. This was probably due to reduced cardiac output secondary to dislocation of the heart during movement. Dopamine and blood transfusion successfully sustained her circulatory condition. Dopamine infusion was required for a period of 1 h, after which her circulatory status became stable. Her heart showed almost 90° clockwise rotation, and the apex protruded out of her chest cage. The abdominal wall was closed without any difficulty; however, any attempt to move her heart into normal position precipitated bradycardia and hypotension. Since there was not enough pericardium to cover the heart, we used silicon rubber sheet to cover the mediastinum and a Resin plate 7 × 6 × 0.3 cm on top of this to close the chest wall defect (fig. 1).

When the operation was completed, the neuromuscular blockade from pancuronium was antagonized in both babies in order to evaluate thoracic cage movement during spontaneous ventilation. Both babies showed quite good movement of the thorax, and no retraction was seen. Nasotracheal intubation was performed, and the twins were transferred to ICU with controlled ventilation.

The postoperative chest roentgenogram in "twin A" was almost

* Assistant Professor.

† Staff Anesthesiologist

‡ Associate Professor.

§ Professor and Chairman.

Received from the Department of Anesthesiology, Kobe University, School of Medicine, Kusunoki-cho-7, Chuo-ku, Kobe, Japan 650. Accepted for publication October 8, 1986.

Address reprint requests to Dr. Hoshina.

Key words: Anesthesia: pediatric. Surgery: Thoracopagus conjoined twins.

normal (fig. 2), but "twin B" showed a deformed right thoracic cage with a shifted mediastinum (fig. 3). However, the general postoperative condition of both babies was satisfactory. Tube feeding was started on the 4th postoperative day.

Weaning from ventilatory support was started from the 5th postoperative day, and extubation of the trachea was performed on the 8th day in "twin A" and the 10th day in "twin B." The ventilatory performance of each baby at the time of extubation assessed by esophageal pressure measurement revealed adequate intrathoracic pressure, both in sleep and in crying phase. The respiratory rates remained high, but no signs of exhaustion were seen, and arterial blood gases were quite stable.

The twins progressed well, and steadily gained weight. The chest wall prostheses functioned well, and permitted adequate spontaneous ventilation during all normal activities. We were unsure how long the resin plates and silicon rubber sheet should be left implanted. Neither material formed an adhesive fusion with adjacent tissue. After 2 months, in one twin, a part of the resin plate became exposed through a skin defect. We then found that dense scar tissue had developed under these materials. When a CT scan suggested that this scar tissue was strong and thick enough to sustain chest wall movement, the resin and silicon rubber was removed. This was at 11 months of age in "twin A" and 10 months of age in "twin B."

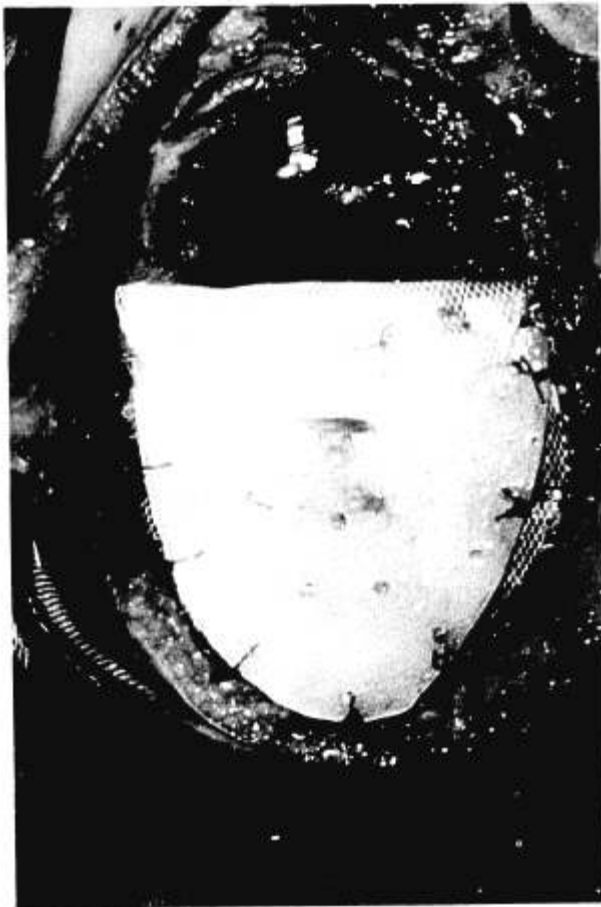

FIG. 1. This Resin plate was sutured to costal cartilage and diaphragm in "twin B." The edge of the silicon rubber sheet used to cover the mediastinum is seen beneath the Resin plate.

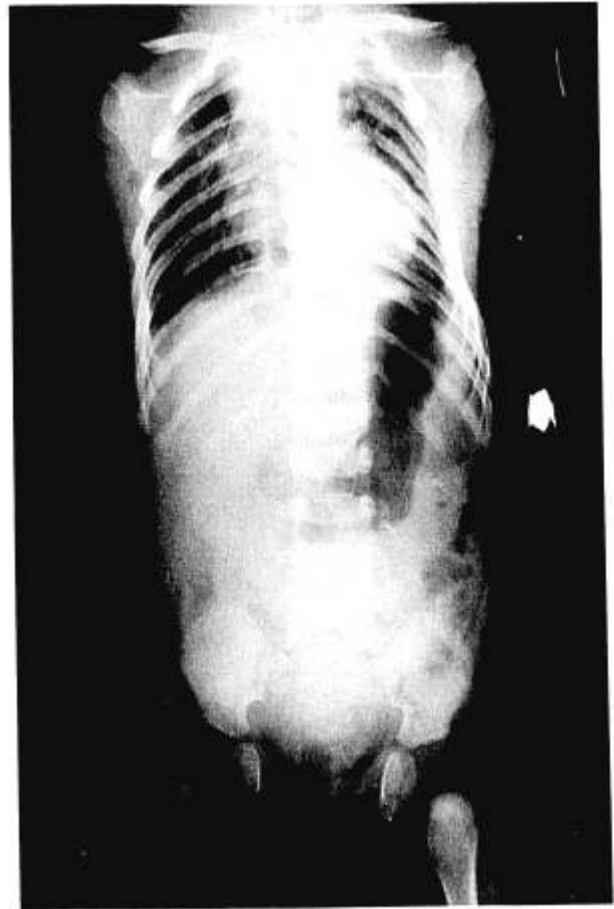


FIG. 2. Whole body radiograph immediately after the operation in "twin A."

DISCUSSION

We describe the successful separation of thoracopagus conjoined twins with fused liver and common pericardial sac. The perioperative management was uneventful, except during awake endotracheal intubation of the first twin. Previous reports have recommended establishment of each airway before muscle relaxants are given to either infant, because the effect on each infant may not be predictable. This is because the direction of cross circulation may vary minute by minute.^{1,2} In addition the trachea may be difficult to intubate, due to the conjunction of the chest. However, in our patients, the cardiopulmonary changes with coughing in one twin adversely influenced the hemodynamic state of the other. With the elevation of CVP following the coughing in "twin B," the blood shift from "twin B" through their cross circulation or the one-directional siphoning of blood to "twin A" from the fused liver, which contains large blood volume, might have occurred. The mechanism, however, is not all clear. Awake endotracheal intubation, therefore, may not be

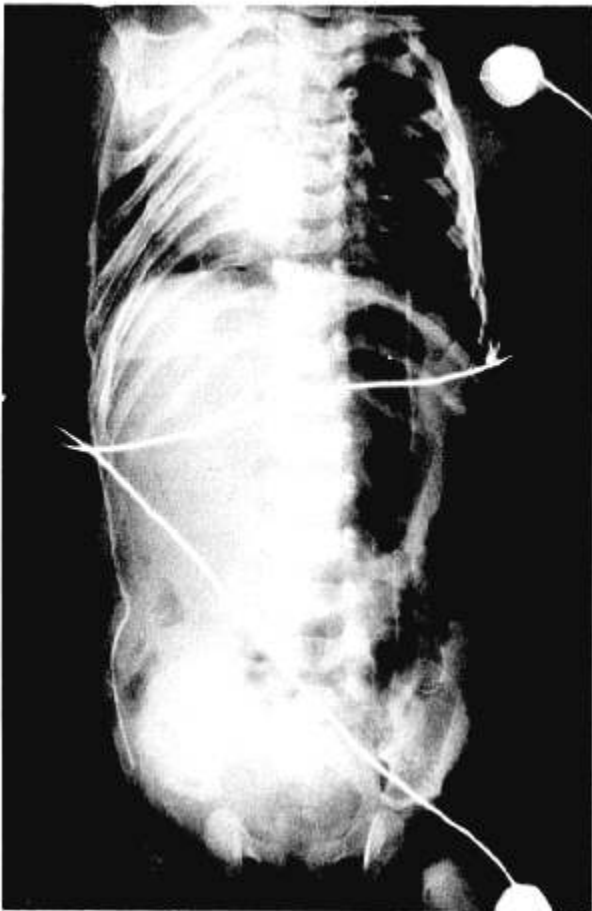


FIG. 3. Whole body radiograph immediately after the operation in "twin B."

always the safest procedure. Smooth induction of anesthesia and intubation of the trachea following inhaled anesthesia and muscle relaxants are suitable if airways in both babies can certainly be maintained with a mask.

The thoracopagus twins we described fortunately had two separate hearts without serious cardiac anomalies which might interfere with separation procedures.³ However, we had anticipated problems with "twin B's" heart, which protruded out of her chest. Any attempts to move her heart back to normal position precipitated bradycardia and hypotension. Since there was not enough pericardial sac to cover the heart, a siliconized rubber sheet was used. In a similar case, Simpson *et al.*⁴ used an acrylic cup fused to a sheet of polypropylene mesh. However, this infant did not survive, due to severe complex cardiac anomalies. In the patients described herein, each twin had a very large defect of the anterior chest wall after separation. The mediastinum was covered with siliconized rubber sheet temporarily. This did not adhere to adjacent tissue, and prevented cardiac wall damage against the Resin plate

which we placed to maintain chest wall rigidity. Other materials, such as horse xenograft or postmortem human dura, might be indicated for permanent use as a pericardium.

The closure of the large defect of chest wall, 13 × 9 cm from the level of the 4th rib down to the umbilicus without sternum, was another crucial problem. It is most important in small infants to stabilize the chest wall and prevent paradoxical movement during spontaneous ventilation. Skin flaps or other synthetic membranes, such as Teflon gauze,⁵ cannot provide rigidity for the thorax. In this case, ventilatory efficiency would be impaired, probably requiring long-term respiratory support in the postoperative period. We, therefore, attempted to use a thin Resin plate sutured to the costal cartilages. Both babies showed adequate thoracic movement immediately after the operation, and completed weaning from the ventilator early in the postoperative period. Early extubation of the trachea is desirable to prevent infection and broncho-pulmonary injury.

The best timing for the separation operation will vary.⁶ We performed the surgery at approximately 2 months of age, to attempt to repair the abnormally developed thorax and improve symmetry and in the longitudinal axis. Concerns about their growth of the thorax and respiratory function still remain.

In conclusion, cardiovascular changes during awake trachea intubation adversely influenced the hemodynamic state of the conjoined baby. This suggests that awake endotracheal intubation is not always the safest procedure. Smooth induction of anesthesia and intubation of the trachea following inhaled anesthesia and muscle relaxants is preferable, if airways in both babies can certainly be maintained *via* a mask. When there is a large anterior chest wall defect, it is essential to stabilize chest wall movement for spontaneous ventilation to be effective and permit early extubation of the trachea.

REFERENCES

1. Furman EB, Roman DG, Hairabet J, Jokoyama M: Management of anesthesia for surgical separation of newborn conjoined twins. *ANESTHESIOLOGY* 34:95-101, 1971
2. Bloch ED and Karis JH: Cardiopagus in neonatal thoracopagus twins: Anesthetic management. *Anesth Analg* 59:304-307, 1980
3. Patel R, Fox K, Dawson JF, Taylon JFN, Graham GR: Cardiovascular anomalies in thoracopagus twins and the importance of preoperative cardiac evaluation. *Br Heart J* 39:1254-1258, 1977
4. Simpson JS: Separation of conjoined thoracopagus twins, with the report and additional case. *Can J Surg* 12:89-96, 1969
5. Towey RM, Kisia AKL, Jacobacci S, Muoki M: Anaesthesia for the separation of conjoined twins. *Anaesthesia*. 34:187-192, 1979
6. Mulcare RJ, Bhokakul P, Potitong P, Wheeler B: The surgical separation of the thoracopagus conjoined twins of Korate, Thailand. *Ann Surg* 172:91-97, 1970