

CORRESPONDENCE

Anesthesiology
66:436-437, 1987

Using an Ureteral Catheter as a Guide in Difficult Neonatal Fiberoptic Intubation

To the Editor:—We recently were confronted by a difficult intubation in a 2-week-old neonate (2,800 g) who needed a ventriculo-peritoneal shunting procedure for symptomatic hydrocephalus. Radiologic and ultrasound data were consistent with the diagnosis of Dandy-Walker syndrome (posterior fossa cyst communicating with the fourth ventricle) associated with an occipital meningocele and the Klippel-Feil anomaly. Microretrognathia, hypoplasia of the soft palate, and anteversion of the uvula were also present.

We therefore planned a fiberoptic intubation, the baby breathing spontaneously a halothane and oxygen mixture. Monitoring included an ECG, a precordial stethoscope, and a pulse oxymeter (Nellcor™). An intravenous dose of atropine (0.125 mg) was given, and induction by mask was carried out with a non-rebreathing circuit.

Because our pediatric fiberoptic laryngoscope (F.L.) (4 mm Fujinon NAP-F) was too large to pass through the endotracheal tube (E.T.), we proceeded as described by Alfery *et al.* for a neonate with fusion of the jaws:¹ the F.L. was passed through the left nostril, and a 3 mm ID Portex tube through the right one; the E.T. was used as a nasopharyngeal airway to provide oxygen and halothane during the procedure. The glottis was seen through the F.L. when an assistant pulled the baby's tongue out, but every attempt to direct the E.T. into the larynx was unsuccessful; the occipito-vertebral anomalies precluded any degree of neck extension, and the pharyngeal space was too small to allow the use of a Magill's forceps without losing visual control.

Looking for a small, atraumatic, but sufficiently rigid guide, we used an ureteral catheter fitted with a central guide wire (Ureteric Catheter Ch. 4 No 223606 RÜSH, W. Germany) (fig. 1). The catheter was bent anteriorly at its distal tip and passed alongside the E.T., through the right nostril. It went quite easily through the vocal cords; the E.T. was then removed and threaded over the catheter into the trachea under direct visual control. The baby was uneventfully extubated at the end of surgery.

We agree with others² that difficult pediatric intubation is a good indication for fiberoptic laryngoscopy. When the F.L. is too large to be passed through the E.T., the use of another guide is mandatory, and two techniques have been described: the guide is either passed through the suction channel of the F.L.³ or through a small rubber catheter attached to its tip.⁴ With both techniques, the F.L. has to be removed before threading the E.T. blindly

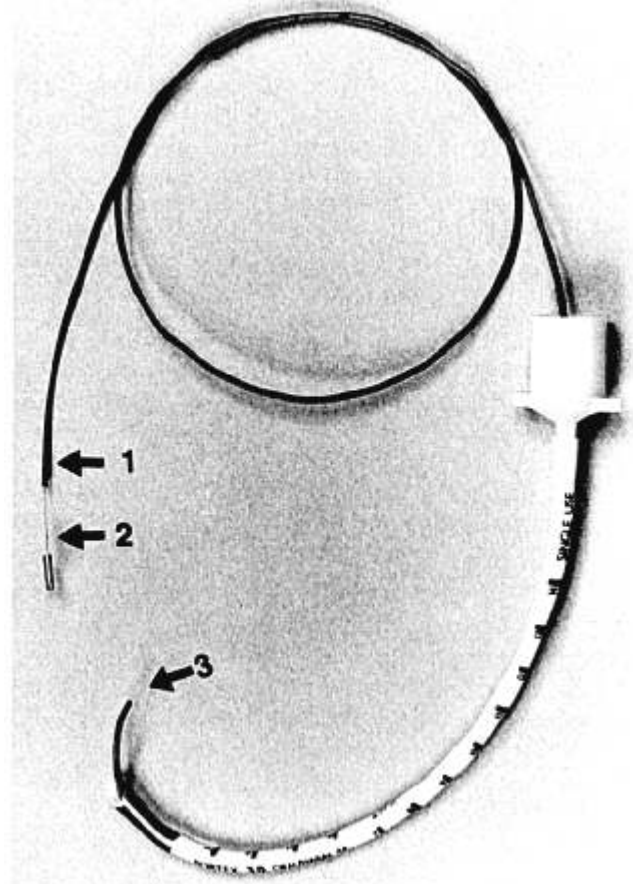


FIG. 1. The ureteral catheter threaded through the endotracheal tube. 1 = ureteral catheter; 2 = inner wire; 3 = bended malleable tip.

over the guide. Our approach allowed us to introduce the E.T. over the catheter under continuous visual control, with minimal risks of laryngeal trauma, or curling of or dislodging of the catheter.

The ureteral catheter we used presents several advantages: it is atraumatic (rounded tip) and pliable, but rigid enough to both keep the chosen shape during the procedure and to be directed by twisting its proximal end. These useful characteristics are mainly due to the catheter's inner wire.

JEAN-MARIE GOUVERNEUR, M.D.
Associate Chief of Anesthesiology

FRANÇOIS VEYCKEMANS, M.D.
Staff Anesthesiologist

MARC LICKER, M.D.
Registrar in Anesthesiology

GASTON VERELLEN, M.D.
Head, Department of Neonatology

BERNARD F. GRIBOMONT, M.D.
Professor, Department of Anesthesiology

*Catholic University of Louvain Medical School
101 1821, Av. Hippocrate. B 1200-Brussels
Belgium*

REFERENCES

1. Alfery DD, Ward CF, Harwood IR, Mannino FL: Airway management for a neonate with congenital fusion of the jaws. *ANESTHESIOLOGY* 51:340-342, 1979
2. Ovassapian A, Dykes MHM: Difficult pediatric intubation: An indication for the fiberoptic bronchoscope. *ANESTHESIOLOGY* 56:412, 1982
3. Stiles CM: A flexible bronchoscope for endotracheal intubation of infants. *Anesth Analg* 53:1017-1019, 1974
4. Ford RWY: Adaptation of the fiberoptic laryngoscope for tracheal intubation with small diameter tubes. *Can Anaesth Soc J* 28: 479-480, 1981

(Accepted for publication November 3, 1986.)

Anesthesiology
66:437, 1987

Dental Rolls for Eye Operations

To the Editor:—During general anesthesia, it is common to see secretions accumulate in the back of the throat and the nose, which are routinely suctioned out during, or at the end of, a case. The face of a patient scheduled for ophthalmic surgery under general anesthesia is usually physically inaccessible to the anesthetist. It is difficult to detect secretions accumulating in the nose or mouth once the patients are fully draped. Also, reaching under the drapes and suctioning the secretions may be cumbersome and may disturb the operative field. We recently administered general anesthesia to a child undergoing eye muscle surgery in whom the surgeon, during the procedure, noticed secretions from the nose flowing under the drapes and into the eye. This led to a break in sterility necessitating a repeat sterile prep and drape. This also necessitated the use of prophylactic antibiotics.

Since then, we have begun using Rhode Island dissectors (fig. 1), commonly known as Dental Rolls, to plug the nostrils of ophthalmic surgery cases undergoing general anesthesia. Following intubation, they can be easily placed into the nostrils to block any nasal secretions. Also, we have been suctioning the nose and the throat just prior to the draping of the patient.

BIDESHWAR KATARIA, M.D.
Instructor in Anesthesia

Anesthesiology
66:437-438, 1987



FIG. 1. Volunteer shown with dental rolls in nostril. Package containing rolls is also seen.

NEAL FLEMING, M.D.
Instructor in Anesthesia
Department of Anesthesia
Georgetown University Hospital

(Accepted for publication November 3, 1986.)

An Easily Assembled Device for Transtracheal Oxygenation

To the Editor:—It is well established that placement of a large-bore intravenous cannula through the cricothyroid membrane is an effective method of oxygenating the patient with supraglottic airway obstruction.¹⁻⁴ Several de-

VICES have been proposed for connecting the hub of the intravenous cannula to a source of positive-pressure oxygen.⁵⁻⁸ Unfortunately, in the situation where airway difficulty is not anticipated, these devices may not be readily