

justed lidocaine is slowly injected intradermally via a 27-gauge needle using the technique of gently scratching the skin to minimize the discomfort of needle placement.<sup>2</sup> The actual injection of pH-adjusted lidocaine is painless.

GREGG A. KORBON, M.D.  
Assistant Professor of Anesthesiology

DAVID P. HURLEY, M.D.  
Chief Resident  
Department of Plastic Surgery

GAYLORD S. WILLIAMS, M.D.  
Professor of Plastic Surgery

University of Virginia  
Charlottesville, Virginia 22908

#### REFERENCES

1. DiFazio CA, Carron H, Grosslight KR, Moscicki JC, Bolding WR, Johns RA: Comparison of pH-adjusted lidocaine solutions for epidural anesthesia. *Anesth Analg* 65:760-764, 1986
2. Bourke DL: Counter-irritation reduces pain during needle insertion (letter). *Anesth Analg* 64:377-382, 1985

(Accepted for publication March 3, 1987.)

Anesthesiology  
66:856-857, 1987

### A Tracheal Divider for Differential Lung Ventilation in Dogs

*To the Editor:*—Many investigators are aware of technical difficulties inherent in the differential lung ventilation in dogs.<sup>1-2</sup>

In a previous report,<sup>3</sup> we used a right-sided Robertshaw tube which was passed into, and seated in, the left main bronchus for differential lung ventilation. However, at autopsy, only 55% (22 cases among a total of 40) of the tubes were confirmed to be in the proper location. In the remaining cases, there was partial obstruction of the left upper lobe bronchus.

TABLE 1. Distance from the Carina to Proximal Edge of Each Lobe Orifice (Mean  $\pm$  SD) (fig. 1, a-d) in mm

	Mean $\pm$ SD (mm) (n = 18)
a	-4.4 $\pm$ 3.3
b	12.4 $\pm$ 7.0
c	24.4 $\pm$ 6.5
d	17.9 $\pm$ 1.9

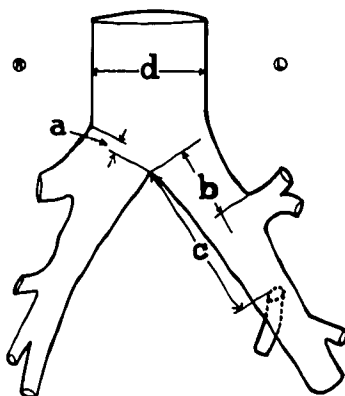


FIG. 1. Diagram of trachea and major bronchial divisions in dogs, showing the measured positions and distances from the carina to the origin of the right upper lobe orifice (a), to the left upper lobe orifice (b), to the left middle lobe (lingula) orifice (c), and the diameter of the trachea (d).

To develop a tube which would more reliably separate the lungs in studies requiring differential ventilation, measurements of the tracheo-bronchial tree near the carina were performed in 18 dogs. Mean distances ( $\pm$ SD) in mm from the carina to right upper lobe orifice (a), to left upper lobe orifice (b), and to left middle lobe orifice (c) are shown in table 1 and figure 1. A striking anatomical feature of the canine tracheal bifurcation is that the mean

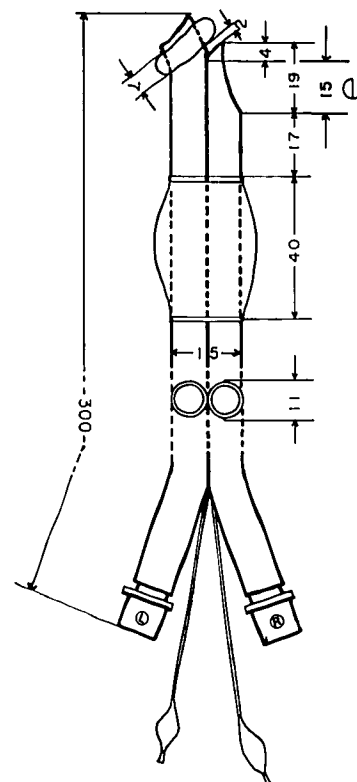


FIG. 2. A scale drawing of the tube (MKP-divider). The tube is made of polyvinyl chloride (PVC) of medical grade, and is soft and pliable, yet has sufficient stiffness to allow manipulation and control during placement. To prevent the tube from being displaced laterally and passing too far into the tracheobronchial tree, a carinal crotch, which is formed by the distal end of the right side of the tube and the projection to the left, is indispensable. The larger balloon separates the right lung from the outside, while the left main-stem bronchial balloon separates the left lung from the right. The length of the right lung ventilation slot (e) is 15 mm (table 1, mean value of a plus  $3 \times$  SD), to prevent partial obstruction of the right upper lobe orifice.

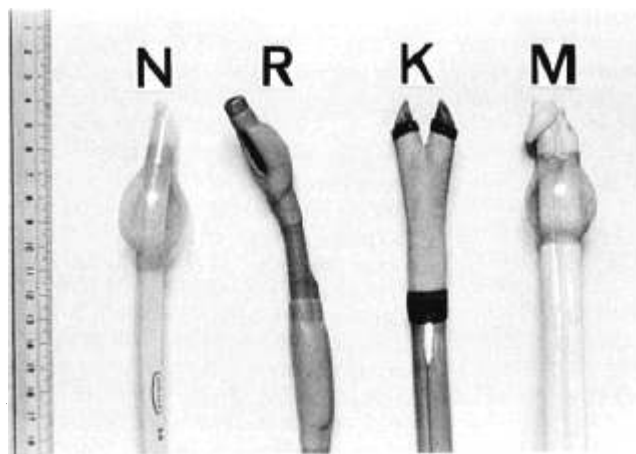


FIG. 3. Standard normal tube (N), Robertshaw double-lumen tube (R), Kottmeier endobronchial double-lumen tube (K), and MKP-divider (M), from left to right, respectively. The short balloon of the MKP-divider on the projection for the left main-stem bronchus is inflated.

distance from the carina to the proximal edge of the right upper lobe orifice (a) is minus 4.4 mm with a SD of 3.3 mm, indicating that the orifice of the right upper lobe bronchus originates above the level of the carina.

This indicates the likelihood for partial obstruction of the right upper lobe orifice by the tip of the right projection of the double lumen tubes which have been widely used.

Using these data (table 1, fig. 1), a double-lumen tube (MKP-divider) was hand fabricated (fig. 2) and is shown in figure 3, along with other available tubes, *i.e.*, normal tube (N), Robertshaw double lumen tube (R), and Kottmeier endobronchial tube (K).

In six dogs, the trachea was intubated with a normal tube and with an MKP-divider, alternately, and values for  $Pa_{O_2}$  were compared. Changes in  $Pa_{O_2}$  were small and insignificant, suggesting that the MKP-divider was inserted with little risk of lobar obstruction.

MANNOSUKE MUNEYUKI, M.D.  
*Professor*

KUNIHICO KONISHI, M.D.  
*Associate Professor*

KAZUHIKO YADA, M.D.  
*Assistant Professor*

*Department of Anesthesiology  
School of Medicine, Mie University  
Tsu, Mie, Japan 514*

HISAO KINOSHITA  
*Technical Manager and Clinical Engineer  
Japan Medico Co., Ltd.*

#### REFERENCES

1. Lategola MT, Schilling JA: Modifications of "George Wright" canine tracheal divider. *Proc Soc Exp Biol Med* 99:507-508, 1958
2. Benfield JR, Coon R, Cree EM: Canine bronchosprometry: The development of a reliable catheter. *J Thorac Cardiovasc Surg* 52:882-892, 1966
3. Munevuki M, Konishi K, Horiguchi R, Tsujimoto S, Saito M, Sakakura S, Konishi A: Effects of alternating lung ventilation on cardiopulmonary functions in dogs. *ANESTHESIOLOGY* 58:353-356, 1983

(Accepted for publication March 6, 1987.)