

TABLE 2. Mean Plasma Bupivacaine Concentrations and Total Body Clearance

Patient	Css (mean \pm SD) mcg \cdot ml ⁻¹	CL, ml \cdot min ⁻¹ \cdot kg ⁻¹
1	.47 \pm .07	7.09
2	.45 \pm .12	7.40
3	.73 \pm .07	4.56
4	0.30 \pm .11	11.11
5	.69 \pm .14	4.83
6	.84 \pm .29	3.96

clearance of bupivacaine exhibited no significant change throughout the course of long-term infusion.

We conclude that continuous epidural infusion of bupivacaine is a safe and effective method of pain relief in children undergoing major lower extremity and genitourinary operations. It requires an anesthesiologist trained in regional anesthesia in children, repeated examination of the child, dependable infusion pumps and attention to measures which prevent infection.

The authors gratefully acknowledge the help of Roger Bellon Laboratories for bupivacaine plasma level measurements and G. Rosine and E. Schmitt for secretarial assistance.

Anesthesiology
67:110-115, 1987

Influence of Balloon Inflation and Deflation on Location of Pulmonary Artery Catheter Tip

WILLIAM E. JOHNSTON, M.D.,* ROGER L. ROYSTER, M.D.,* JAKOB VINTEN-JOHANSEN, PH.D.,†
GLENN P. GRAVLEE, M.D.,* GEORGE HOWARD, M.S.P.H.,‡ STEPHEN A. MILLS, M.D.,†
WILLIAM Y. TUCKER, M.D.†

Catheter perforation of the pulmonary artery represents a serious and sometimes lethal complication of invasive hemodynamic monitoring; it is seen predomi-

REFERENCES

1. Ecoffey C, Dubousset AM, Samii K: Lumbar and thoracic epidural anesthesia for urologic and upper abdominal surgery in infants and children. *ANESTHESIOLOGY* 65:87-90, 1986
2. Meigner M, Souron R, Leneel JC: Postoperative dorsal epidural analgesia in the child with respiratory disabilities. *ANESTHESIOLOGY* 59:473-475, 1983
3. Brown TCK: Local and regional anesthesia in children. *Anaesthesia* 40:407-408, 1985
4. Raj PP, Knarr D, Hartrick CT, Pither CP, Denson DD, Hopson CN: Efficacy of continuous epidural bupivacaine infusion for postoperative pain relief. *ANESTHESIOLOGY* 61:A186, 1984
5. Hanson AL, Hanson B: Continuous mini-infusion of bupivacaine into the epidural space during labor: Experience from 1000 deliveries. *Reg Anaesth* 10:139-144, 1985
6. Gibaldi M, Perrier D: *Pharmacokinetics*. New York, Marcel Dekker, 1975, pp 289-294
7. Denson D, Raj P, Saldahna F, Finnsson R, Ritschel W, Joyce III T, Turner J: Continuous perineural infusion of bupivacaine for prolonged analgesia: Pharmacokinetic considerations. *Int J Clin Pharmacol Ther Toxicol* 21:591-597, 1983
8. Ecoffey C, Desparmet J, Maury M, Berdeaux A, Giudicelli JF, Saint-Maurice C: Bupivacaine in children: Pharmacokinetics following caudal anesthesia. *ANESTHESIOLOGY* 63:447-448, 1985

* Associate Professor in Anesthesiology.

† Assistant Professor in Surgery (Section on Cardiothoracic Surgery).

‡ Assistant Professor, Center for Prevention Research and Biometry.

Received from the Departments of Anesthesia and Surgery (Section on Cardiothoracic Surgery) and the Center for Prevention Research and Biometry, Wake Forest University Medical Center, Winston-Salem, North Carolina. Accepted for publication January 22, 1987. Presented in part at the 37th Annual Meeting of the American Society of Anesthesiologists, October 18-22, 1986, Las Vegas, Nevada.

Address reprint requests to Dr. Johnston: Department of Anesthesia, Bowman Gray School of Medicine, 300 South Hawthorne Road, Winston-Salem, North Carolina 27103.

Key words: Complications: pulmonary artery perforation. Monitoring: pulmonary artery. Surgery: cardiac.

nantly in patients with pulmonary hypertension.^{1,2} Two initiating mechanisms have been proposed: 1) eccentric balloon inflation, causing impingement of the catheter tip into the vessel wall,³⁻⁵ and 2) high intraballoon pressures, causing direct vessel disruption during balloon inflation.^{4,6,7} We believe that other forces acting on the catheter tip may contribute to causing this complication.

Several reports have described catheter-induced rupture through the pulmonary artery, with extension into the pleural cavity, causing massive hemothoraces.^{1,4,8,9} One possible explanation of the hemothorax is the formation of a dissecting hematoma by the catheter perforating the pulmonary artery, with dissection into the pulmonary parenchyma and extension into the pleural space. Another explanation is direct penetration of the catheter tip through the pulmonary artery and parenchyma into the pleural space.⁸ In the latter circumstance, the hemodynamic forces causing this excessive

amount of catheter tip movement have not been explained.

Patients with pulmonary hypertension appear at risk for catheter-induced pulmonary artery rupture, due, in part, to structural differences in the vessel wall and to a larger pressure gradient across the inflated balloon which may force the tip to perforate the vessel.^{4,10} However, another factor causing the catheter tip to migrate distally may be the size of the catheter balloon.

Although the characteristics of catheter balloon inflation have been described,¹¹ the properties of balloon deflation and the relationship between balloon deflation and catheter tip movement, particularly in the presence of pulmonary hypertension, have not been studied. We have observed that balloon deflation differs from inflation, and believe the smallest balloon volume occurs during deflation. Consequently, the most distal catheter migration may occur during deflation, rather than during inflation. In support of this theory, Haapaniemi *et al.* reported a case where distal tip migration occurred during balloon deflation.⁷ For these reasons, we tested three hypotheses: 1) that distal migration of the catheter tip is greater during balloon deflation than during balloon inflation, 2) that the amount of tip migration during deflation is greater in the presence of elevated mean pulmonary artery pressure (PAP) than when PAP is normal, and 3) that characteristics of balloon deflation differ from those of balloon inflation.

METHODS

To test the first two hypotheses, we studied catheter migration in 14 men and four women scheduled for elective coronary artery bypass surgery. Patients were excluded from the study if emergency surgery was required or if they had any form of cardiac dysrhythmia. Eleven of the 18 patients (group 1) had PAP < 20 mmHg; seven patients (group 2) had pulmonary hypertension (PAP ≥ 20 mmHg). The study was approved by the Institutional Research Practices Committee and required patient consent, which was obtained.

By the Seldinger technique, we advanced a 7.5 F quadruple-lumen pulmonary artery catheter (American Edwards Laboratories, Santa Ana, CA) from the right internal jugular vein into the pulmonary artery until a pulmonary artery occlusion pressure tracing was obtained. The catheter was positioned so that inflating the balloon with 1.5 ml air, the volume recommended by the manufacturer, caused the catheter to wedge within two cardiac cycles. We noted the catheter length at the point of insertion into the introducer sheath, and secured the end of the catheter to the patient's forehead to prevent accidental catheter migration. Anesthesia consisted of diazepam, fentanyl, and pancuronium iv.

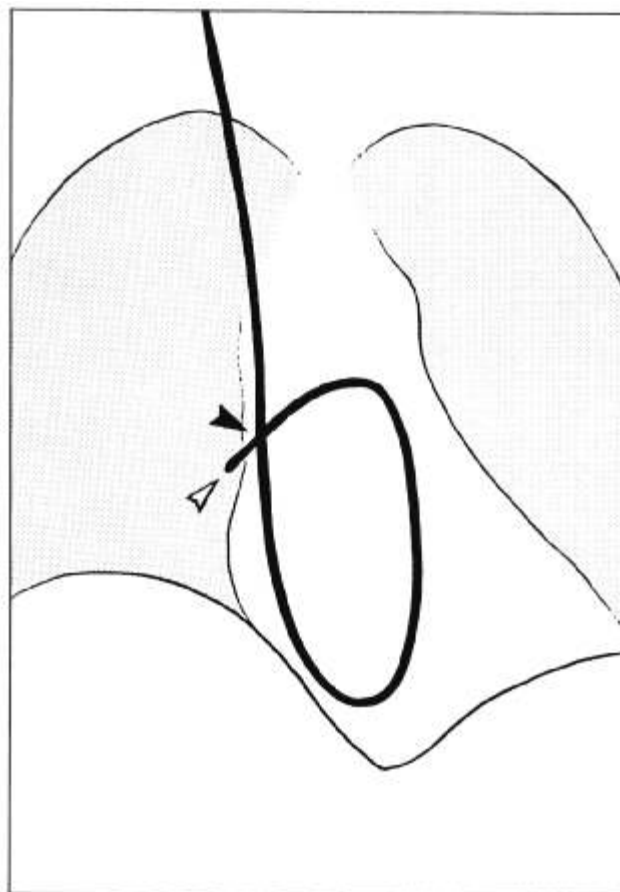


FIG. 1. This schematic diagram of a chest radiograph illustrates location of the catheter tip (open arrow) relative to the zero point (closed arrow) at the intersection of the catheter's location in the superior vena cava and its location in the pulmonary artery.

An intravenous infusion of nitroglycerin at 50 μ g/min was started before induction and maintained throughout the study period.

Following induction of anesthesia and endotracheal intubation, we used fluoroscopy to determine the location of the catheter tip and recorded that location relative to a zero point defined as the radiographic intersection of the catheter in the pulmonary artery with the catheter in the superior vena cava (fig. 1).¹² Catheter tip location to the patient's right of the zero point was designated positive (forward) migration; to the left as negative (backward) migration. A coin placed on the chest wall served as a reference standard to correct for image magnification.

Under fluoroscopy, after temporarily disconnecting the endotracheal tube from the ventilator, we inflated the catheter balloon with 1.5 ml of air from the syringe, identifying the wedge position by the appearance of a typical pulmonary artery occlusion pressure tracing. We

TABLE 1. Hemodynamic Variables in Group 1 and 2 Patients

Variable	Group 1 (n = 11)	Group 2 (n = 7)
Mean arterial pressure (mmHg)	82 ± 4	85 ± 7
Heart rate (beats/min)	65 ± 3	75 ± 7
Pulmonary artery pressure (mmHg)	16.2 ± 0.7	25.1 ± 2.2*
Pulmonary artery occlusion pressure (mmHg)	10.2 ± 0.7	16.7 ± 1.4*
Central venous pressure (mmHg)	8.3 ± 0.9	11.7 ± 1.3*
Cardiac output (l/min)	5.7 ± 0.6	5.3 ± 0.7
Catheter insertion distance (cm)	50.2 ± 0.6	54.7 ± 0.8*

* $P < 0.05$ compared to group 1.

then released the pressure on the syringe plunger without detaching the syringe and allowed the balloon to deflate passively. This maneuver was performed three times and catheter tip locations were averaged for each of four intervals: baseline during diastole, baseline during systole, following balloon inflation, and the greatest forward point during passive balloon deflation. Together, all three inflation-deflation cycles were completed within 20–30 s.

During these maneuvers, we recorded phasic systemic arterial and pulmonary arterial pressures, central venous pressure (CVP), and pulmonary artery occlusion pressure. We calculated mean arterial pressure and PAP using standard formulae and measured arterial blood gases and temperature (pulmonary artery catheter thermistor).

To test the third hypothesis, we examined six unused 7.5 F catheters (American Edwards Laboratories, Santa

Ana, CA) to quantitate catheter balloon inflation and deflation characteristics *in vitro*. We tested each catheter by injecting 1.5 ml of air before the study to insure that inflation was symmetrical by visual inspection. We measured intraballoon pressure with a transducer and intraballoon volume by water displacement in a 37° C water bath. Using the 1.5 ml syringe, we slowly injected 0.1 ml increments into the balloon until it was fully inflated; the balloon was then deflated in 0.1-ml decrements. At each 0.1-ml interval, we waited 20–30 s for the pressure to stabilize and then measured intraballoon volume. The inflation-deflation procedure was performed three times, and the respective values were averaged.

We analyzed the data, expressed as mean ± standard error (SE), by paired *t* test for intragroup comparisons and the *in vitro* study, and by *t* test for independent samples for intergroup comparisons. A P value ≤ 0.05 was considered significant.

RESULTS

All patients were well oxygenated, with Pa_{O_2} s between 349 and 516 mmHg and Pa_{CO_2} s between 32 and 43 mmHg. Their temperatures varied from 35.3–36.6° C. PAP averaged 16.2 ± 0.7 mmHg (range 11.3–18.7 mmHg) in group 1 and 25.1 ± 2.2 mmHg (range 20.0–36.0 mmHg) in group 2 ($P < 0.01$). Pulmonary artery occlusion pressure and CVP were higher in group 2 than in group 1 patients (table 1). Other hemodynamic variables were not significantly different between the groups.

In all patients, the catheter tips lay in the right pulmonary artery. The catheters required a greater insertion distance before a satisfactory wedge position was obtained in group 2 patients than in group 1 patients ($P < 0.05$, table 1). No patient in either group had evidence of pulmonary artery perforation during the study period.

At baseline, group 1 catheter tips were located 1.0 ± 0.6 cm to the right of the zero point in diastole and 1.9 ± 0.6 cm to the right of the zero point in systole ($P < 0.01$ comparing systole with diastole, fig. 2). Balloon inflation caused the catheter tips to migrate 1.4 ± 0.3 cm toward the periphery of the lung from systolic baseline values ($P < 0.01$). With passive balloon deflation, catheter tips migrated an additional 0.4 ± 0.2 cm over a range of 0–1.8 cm ($P < 0.05$ compared to inflation values). The total excursion distance of the catheter tip in group 1 patients from baseline at diastole through balloon deflation was 2.6 ± 0.5 cm ($P < 0.001$).

In group 2 patients, catheter tips were located to the patient's right of the zero point by 2.1 ± 0.7 cm during diastole and 3.3 ± 0.6 cm during systole ($P < 0.02$, fig.

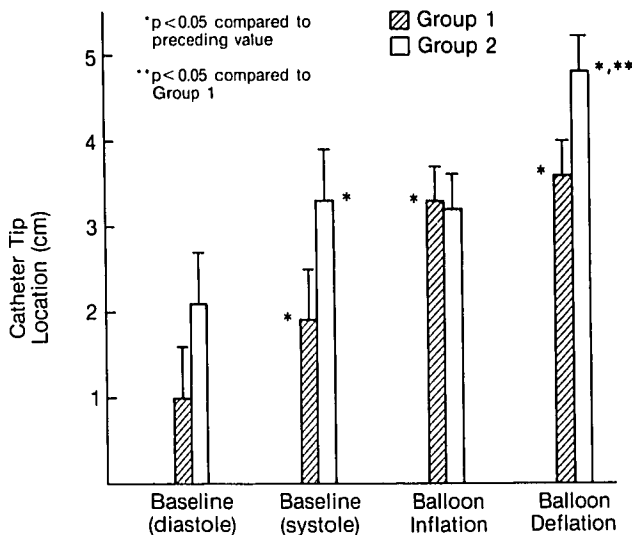


FIG. 2. Catheter tip locations at the four measurement intervals in group 1 patients with PAP < 20 mmHg and in group 2 patients with PAP ≥ 20 mmHg. All distances are referenced to the zero point (see text).

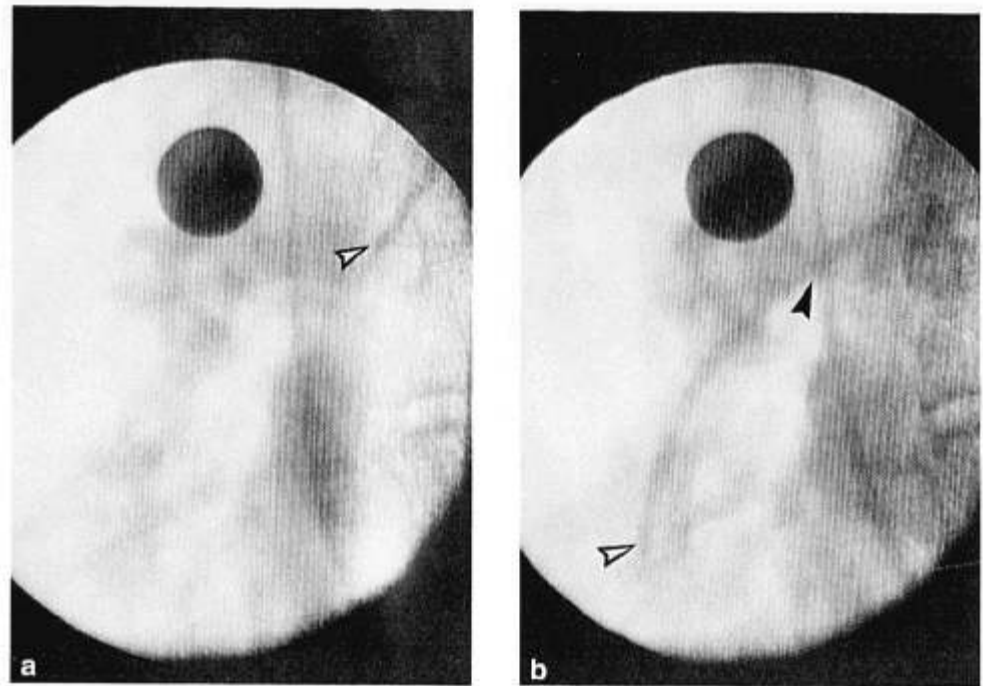


FIG. 3. Radiographs from a group 2 patient with mean pulmonary artery pressure of 36 mmHg, illustrating the degree of catheter tip migration (open arrow) from baseline at diastole (a) and during balloon deflation (b). The respective catheter tip locations were -1.5 and $+5.9$ cm from the zero point. Closed arrow in b indicates the zero point.

2). Balloon inflation caused the catheter tips to move minimally to 3.2 ± 0.4 cm, a location very similar to that in group 1 patients (3.3 ± 0.4 cm). With balloon deflation, catheter tips in group 2 patients migrated an additional 1.6 ± 0.3 cm toward the lung periphery over a range of 0.3–2.6 cm ($P < 0.01$ compared to inflation values). The total excursion distance of the catheter tip from baseline at diastole through balloon deflation was 2.7 ± 0.7 cm ($P < 0.01$), a distance similar to group 1. However, during balloon deflation alone, the amount of catheter tip migration was greater and the actual tip location was more distal in group 2 than in group 1 patients ($P < 0.05$, respectively, fig. 2). The proportion of tip migration occurring during balloon deflation relative to the overall excursion distance was 13% in group 1 patients in contrast to 62% in group 2 patients. Catheter tips in both patient groups spontaneously returned to baseline position following each inflation-deflation sequence. Anteroposterior radiographs from a group 2 patient taken at baseline during diastole and during balloon deflation are shown in figure 3. The actual distances of catheter tip migration during inflation and deflation for each patient are shown in figure 4.

In the *in vitro* studies of six catheters, instantaneous balloon inflation from zero to 0.41 ± 0.1 ml occurred after injecting 1.1 ± 0.1 ml of air. Intraballoon pressure was 294 ± 34 mmHg at this point; it decreased slightly with further inflation, indicating balloon expansion, as previously noted by McDonald *et al.*¹¹ On the other hand, incremental deflation appeared to be more grad-

ual, with the smallest balloon volume before zero being 0.22 ± 0.03 ml ($P < 0.001$ compared with the initial inflating volume). A representative pressure-volume tracing of one catheter balloon is shown in figure 5.

DISCUSSION

We believe our technique of measuring catheter tip distance¹² is accurate and justified. As assessed by computed tomographic examinations of the thorax, the distance between the superior vena cava and right pulmonary artery is small. For that reason, and because there was no rotation of the patient's body and no ventilation during fluoroscopy, we believe that parallax was so minimal that it did not influence our results (R. H. Choplin, personal communication). Although a bony landmark could have been used, the catheter intersec-

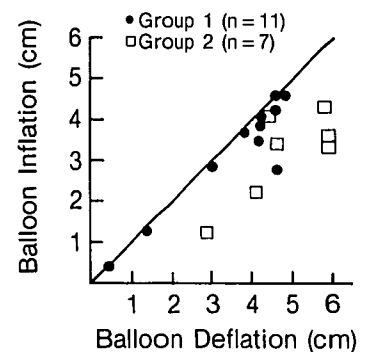


FIG. 4. Peripheral movement of the catheter tip during balloon inflation and deflation. Group 1 patients tended to center near the solid line (line of identity). In contrast, group 2 patients were shifted rightward, indicating greater tip movement during balloon deflation than inflation.

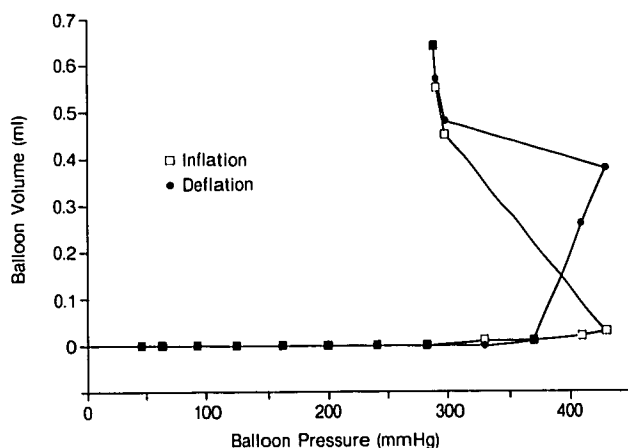


FIG. 5. Catheter balloon volumes during inflation (open square) and deflation (closed square) produced by incremental 0.1-ml injections. During inflation, the catheter balloon volume rapidly expanded as intraballoon pressure decreased (by the law of Laplace). Conversely, during deflation, progressively smaller balloon volumes were found.

tion was readily visible in all patients and allowed the size of the area to be coned down to include the zero point and catheter tip. This minimized radiation exposure to the patient. In addition, any lateral movement of the catheter in the superior vena cava or pulmonary artery which could affect the zero point should be the same for both patient groups.

The actual distance of tip migration can only be defined if simultaneous anteroposterior and lateral views are obtained. For this study, we recognized that, by using only the anteroposterior projection, we would quantitate anterior or posterior movement less accurately than lateral movement. For that reason, we disqualified any patient in whom the catheter tip was located in the left main pulmonary artery, since that artery tends to course more posteriorly than the right main pulmonary artery. With that disqualification, we believe that the two groups of patients were comparable, since any tendency for the catheter tip to move in an anterior or posterior direction would then be similar in both groups. Potentially, catheter tip movement might have been greater on lateral views.

Balloon deflation can be accomplished by 1) active aspiration of air, or 2) passive balloon deflation with or without the syringe attached. Because the former technique may cause excessive balloon trauma, passive deflation was used in this study. However, since the syringe remained attached to the catheter, balloon deflation depended on intrinsic balloon characteristics as well as the resistance of the plunger in the syringe. Whether disconnecting the syringe from the catheter would affect our findings is not known.

Most suggested causes of catheter tip perforation of the pulmonary artery have implicated balloon inflation.⁶ According to one theory, eccentric inflation of the balloon forces the catheter tip into the vessel wall, damaging the wall and causing eventual perforation.^{3,5,10} However, it is more likely that the location of the catheter tip influences the configuration of the balloon during inflation. Shin *et al.* found that the greatest incidence of eccentric balloon inflation occurred when the catheter tip was located in the lung periphery, while concentric balloon inflation occurred if the tip was more proximally placed.¹³ Further studies are needed to determine whether catheter balloons tend to inflate concentrically or eccentrically in patients with pulmonary hypertension.

Pulmonary hypertension is thought to play a primary causative role in catheter-induced pulmonary artery perforation.¹⁻⁴ In the present study, we found that catheters in patients with elevated PAP required a 4.5 ± 0.7 cm greater insertion distance to obtain a pulmonary artery occlusion pressure, and that they tended to have a more peripheral location at baseline than catheters in patients with normal PAP. The effect of severe pulmonary hypertension on catheter tip migration during balloon deflation with respect to vessel caliber remains unknown. The role of pulmonary hypertension as an etiologic mechanism of catheter-induced pulmonary artery perforation may be one of causing the catheter tip to be located in the lung periphery, as suggested by Lemen *et al.*³

We believe that the characteristics of balloon inflation and deflation represent a primary factor causing distal tip migration into the pulmonary artery. We found that the most distal catheter tip location occurs during balloon deflation in all patients. Of greater significance is the observation that the catheter tip migrates further toward the lung periphery during deflation in patients with elevated PAP. However, since our group 2 patients had only moderate pulmonary hypertension, and since catheter-induced perforation of the pulmonary artery was not seen in any patient, our comments remain speculative.

Observing that, during rapid balloon inflation, the catheter tip acted like a "spear" against the vessel wall, Haapaniemi *et al.* recommended gradual balloon inflation to eliminate this problem.⁷ However, since both a study by McDonald and Zaidan¹¹ and the *in vitro* portion of our study showed instantaneous balloon inflation despite the gradual incremental injection of air, we do not regard slow balloon inflation as protective against catheter perforation of the pulmonary artery.

Because the discrepancies between instantaneous inflation and gradual deflation of the catheter balloon are

most likely to occur *in vivo*, we believe these discrepancies account for the distal catheter tip migration found during passive balloon deflation. Gradual balloon deflation would cause smaller balloon volumes and allow the catheter tip to be propelled into the lung periphery. The sparring effect discussed by Haapaniemi *et al.*⁷ may occur more often with balloon deflation rather than inflation, and appears more likely to occur when PAP is elevated. Since the balloon no longer covers the catheter tip during deflation, the exposed tip could directly traumatize smaller pulmonary vessels. As can be seen in figure 3A, in a patient with pulmonary hypertension, the catheter tip seen on a radiograph obtained before balloon inflation may be located medially. However, as can be seen in figure 3B, the catheter tip protrudes into the lung periphery during deflation, which we believe enhances the risk for perforation.

The size of the right ventricular cavity represents another potential influence upon the extent of distal tip migration during balloon deflation. It seems likely that, despite similar baseline locations of the catheter tips in both groups, patients in group 2 had larger catheter loops in the right ventricle, since they required greater catheter insertion lengths. In addition, right atrial pressure was higher in group 2 than in group 1 patients. Consequently, we do not know whether distal tip migration in group 2 patients during balloon deflation depended solely on pulmonary artery pressure, or on shortening of a large right ventricular catheter loop, or both. Nevertheless, the catheter tips in both groups returned to baseline position with respect to the zero point following balloon deflation. If shortening of the ventricular catheter loop is important, maintaining the smallest possible catheter loop in the right ventricle may minimize the amount of tip migration during deflation. Catheter repositioning may be required before obtaining a wedge pressure recording. This could be accomplished in a sterile fashion using a plastic protective shield.¹⁴ In addition, active deflation of the balloon or disconnecting the syringe may affect the amount of tip migration. Rapid deflation could minimize the time of smaller balloon volumes and allow equilibration of pressures on either side of the balloon to occur as quickly as possible. Both suggestions remain speculative and warrant further study. It should be kept in mind that rapid balloon deflation might cause excessive balloon trauma and rupture.

To summarize, we found that the pulmonary artery catheter tip locates more distally in the lung periphery during balloon deflation than during balloon inflation.

Moreover, the distal tip migrates further during deflation in patients with elevated PAP than in patients with normal PAP. These findings may be important to an understanding of the cause of catheter perforation of the pulmonary artery.

The authors express their appreciation to Robert H. Choplin, M.D., for the use of fluoroscopic and radiographic equipment; to Ellen Tommasi, B.A., for her technical assistance; and to Betty McDonald for her secretarial skills.

REFERENCES

1. Pape LA, Haffajee CI, Markis JE, Ockene IS, Paraskos JA, Dalen JE, Alpert JS: Fatal pulmonary hemorrhage after use of the flow-directed balloon-tipped catheter. *Ann Intern Med* 90:344-347, 1979
2. Hannan AT, Brown M, Bigman O: Pulmonary artery catheter-induced hemorrhage. *Chest* 85:128-131, 1984
3. Lemen R: A mechanism of pulmonary-artery perforation by Swan-Ganz catheters. *N Engl J Med* 292:211-212, 1975
4. Barash PG, Nardi D, Hammond G, Walker-Smith G, Capuano D, Laks H, Kopriva CJ, Baue AE, Geha AS: Catheter-induced pulmonary artery perforation. *J Thorac Cardiovasc Surg* 82:5-12, 1981
5. Lozman J, Powers SR Jr, Older T, Dutton RE, Roy RJ, English M, Arco D, Eckert C: Correlation of pulmonary wedge and left atrial pressures. A study in the patient receiving positive end expiratory pressure ventilation. *Arch Surg* 109:270-277, 1974
6. Hardy JF, Morissette M, Taillefer J, Vauclair R: Pathophysiology of rupture of the pulmonary artery by pulmonary artery balloon-tipped catheters. *Anesth Analg* 62:925-930, 1983
7. Haapaniemi J, Gadowski R, Naini M, Green H, MacKenzie D, Rubenfire M: Massive hemoptysis secondary to flow-directed thermodilution catheters. *Cathet Cardiovasc Diagn* 5:151-157, 1979
8. Kelly TF Jr, Morris GC Jr, Crawford ES, Espada R, Howell JF: Perforation of the pulmonary artery with Swan-Ganz catheters. Diagnosis and surgical management. *Ann Surg* 193:686-692, 1981
9. McDaniel DD, Stone JG, Faltas AN, Khambatta HJ, Thys DM, Antunes AM, Bregman D: Catheter-induced pulmonary artery hemorrhage. Diagnosis and management in cardiac operations. *J Thorac Cardiovasc Surg* 82:1-4, 1981
10. Lapin ES, Murray JA: Hemoptysis with flow-directed cardiac catheterization (letter to the editor). *JAMA* 220:1246, 1972
11. McDonald DH, Zaidan JR: Pressure-volume relationships of the pulmonary artery catheter balloon. *ANESTHESIOLOGY* 59:240-243, 1983
12. Johnston WE, Royster RL, Choplin RH, Howard G, Mills SA, Tucker WY: Pulmonary artery catheter migration during cardiac surgery. *ANESTHESIOLOGY* 64:258-262, 1986
13. Shin B, Ayella RJ, McAslan TC: Pitfalls of Swan-Ganz catheterization. *Crit Care Med* 5:125-127, 1977
14. Johnston WE, Prough DS, Royster RL, Peacock JE, Gravlee GP, Mills SA, Cordell AR: Short-term sterility of the pulmonary artery catheter inserted through an external plastic shield. *ANESTHESIOLOGY* 61:461-464, 1984