

dysfunction, and hydrocephalus. One series of 60 patients¹¹ cites only two patients with torticollis among 19 categories of preoperative neurologic findings. Congenital cerebellar herniation can be viewed as a type of extrinsic cervical cord "tumor." Seven pediatric patients with intrinsic cervical cord tumor discussed by Visudhiphan *et al.*⁴ and Kiwak *et al.*² presented with torticollis.

The mechanism that promotes torticollis is unknown. Perhaps the spinal nerve that exits along C₁-C₂-C₃ nerve roots is irritated by compression, causing an imbalance of muscle tone to the sternocleidomastoid and trapezius muscles. In this patient, the hyperextended position of the atlanto-occipital junction during tonsillectomy probably accentuated the irritative compression and precipitated symptoms. Theoretically, a previously asymptomatic patient with ACM type I might suddenly manifest symptoms after whiplash injury.

In conclusion, acquired persistent torticollis is not necessarily a benign condition of muscle spasm. As this case illustrates, a thorough evaluation is indicated to uncover and treat the underlying disorder. Unrelated elective surgery probably should be postponed in a patient with persistent acquired torticollis pending a thorough neurologic examination. Sustained hyperextension of the neck under anesthesia, especially when muscle relaxants are used, may be hazardous to any patient who may be harboring a yet undiagnosed cervical instability or congenital anomaly.

Anesthesiology
67:122-125, 1987

Histamine Release by Vancomycin: A Mechanism for Hypotension in Man

JERROLD H. LEVY, M.D.,* NANCY KETTLEKAMP, B.A.,† PETER GOERTZ, M.D.,‡ JEANNE HERMENS, M.D.,‡
CAROL A. HIRSHMAN, M.D.§

Vancomycin, a glycopeptide antibiotic, produces hypotension and flushing during rapid administration in individuals without previous exposure.^{1,2} Primary myocardial depression has been suggested as the mechanism

REFERENCES

1. Clark RN: Diagnosis and management of torticollis. *Pediatr Ann* 5:231-239, 1976
2. Kiwak KJ, Deray MJ, Shields WD: Torticollis in three children with syringomyelia and spinal cord tumor. *Neurology* 33:946-948, 1983
3. McDaniel A, Hirsch BE, Kornblut AD, Armbrustmacher VM: Torticollis in infancy and adolescence. *Ear Nose Throat J* 63:478-487, 1984
4. Visudhiphan P, Chiemchanya S, Somburanasin R, Dheandhanoo D: Torticollis as the presenting sign in cervical spine infection and tumor. *Clin Pediatr (Phila)* 21(2):71-76, 1982
5. Ballenger JJ: *Diseases of the Nose, Throat, Ear, Head and Neck*, 13th edition. Philadelphia, Lea and Febiger, 1985, p 267
6. Mercer RD: Atlas-axis dislocation following cervical adenitis. *Cleve Clin Q* 11:161-165, 1952
7. Gilles FH, Bina M, Sotrel A: Infantile atlanto-occipital instability. The potential danger of extreme extension. *Am J Dis Child* 133:30-37, 1979
8. Appleby A, Foster JB, Hankinson J, Hudgson P: The diagnosis and management of the Chiari anomalies in adult life. *Brain* 91:131-140, 1968
9. Banerji NK, Millar JHD: Chiari malformation presenting in adult life. *Brain* 97:157-168, 1974
10. Gardner WJ, Goodall RJ: The surgical treatment of Arnold-Chiari malformation in adults. *J Neurosurg* 7:199-206, 1950
11. Saez RJ, Onofrio M, Yanagihara T: Experience with Arnold-Chiari malformation, 1960 to 1970. *J Neurosurg* 45:416-422, 1976
12. Mohr PD, Strang FA, Sambrook MA, Boddie HG: The clinical and surgical features in 40 patients with primary cerebellar ectopia (adult Chiari malformation). *Q J Med* 181:85-96, 1977

* Assistant Professor of Anesthesiology, Emory University School of Medicine.

† Research Assistant, Oregon Health Sciences University School of Medicine.

‡ Resident in Anesthesiology, Oregon Health Sciences University School of Medicine.

§ Professor of Anesthesiology and Pharmacology, Oregon Health Sciences University School of Medicine.

Received from the Division of Cardiothoracic Anesthesia, Emory Clinic, Department of Anesthesiology, Emory University School of

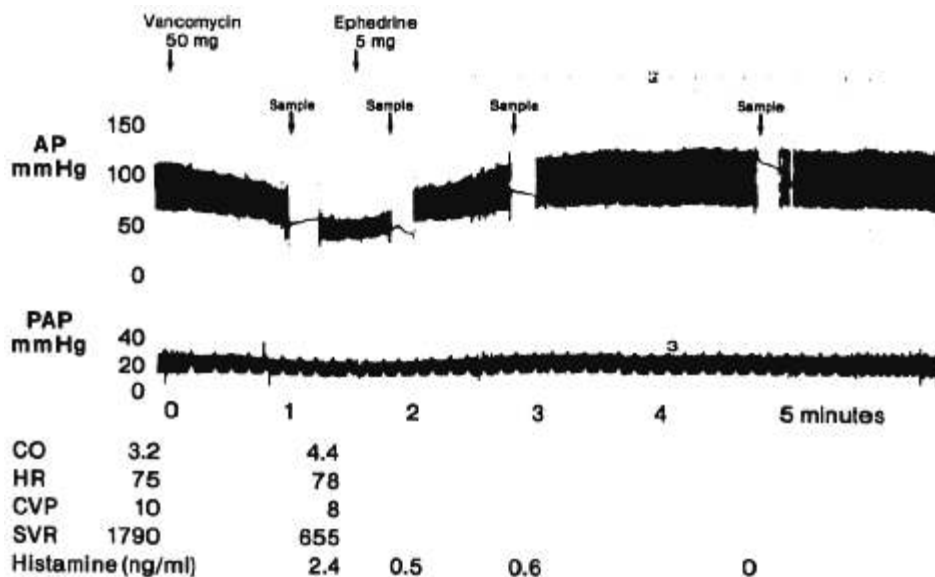
responsible for the hypotension.^{3,4} However, in this report, we found elevated plasma histamine levels in two patients who became hypotensive following vancomycin administration, and histamine release by vancomycin in dispersed human cutaneous mast cells. We now believe that nonimmunologic histamine release by vancomycin, not the vancomycin *per se*, is the mechanism responsible

Medicine; and the Department of Anesthesiology, Oregon Health Sciences University School of Medicine. Accepted for publication January 30, 1987.

Address reprint requests to Dr. Levy: Department of Anesthesiology, Emory University Hospital, 1364 Clifton Road NE, Atlanta, Georgia 30322.

Key words: Complications: hypotension. Histamine. Pharmacology: vancomycin.

FIG. 1. Hemodynamic parameters and histamine levels following rapid vancomycin administration in a patient. Hypotension was associated with an increased cardiac output and decreased calculated systemic vascular resistance. Plasma histamine levels 1 min after the vancomycin administration were 2.4 ng/ml, and subsequently decreased to zero. The patient was given ephedrine, 5 mg, and blood pressure returned to baseline values.



for hypotension following rapid vancomycin administration.

REPORT OF TWO CASES

A 61-year-old man with a history of penicillin allergy and exertional angina was scheduled for a thoracotomy for left upper lobe resection of a squamous cell carcinoma. Preoperative monitors included radial and pulmonary artery catheters, lead II and V5 electrocardiogram. Prior to induction of anesthesia, 50 mg of vancomycin was accidentally administered as a rapid iv bolus. Arterial blood pressure precipitously decreased to 68/35 mmHg, cardiac output increased to 4.4 l/min, the calculated systemic vascular resistance decreased to 450 dyne \cdot sec⁻¹ \cdot cm⁵, and the calculated stroke volume increased to 56 ml/beat (fig. 1). Ephedrine, 5 mg, was given iv, and arterial blood pressure rapidly returned to baseline values. Blood samples were obtained in sodium heparin syringes at 1, 2, 3, and 5 min after the initial vancomycin bolus and placed immediately on ice for histamine determination. The plasma histamine concentration during the initial hypotensive episode (1 min) was 2.4 ng/ml.

A 57-year-old woman was admitted for a right carotid endarterectomy. Past medical history included a prior myocardial infarction, a tomato and penicillin allergy, and hives following renografin. An arterial cannula was inserted, and anesthesia was induced with 300 mg thiopental, 0.5 mg pancuronium, and 100 mg succinylcholine iv. The trachea was easily intubated and anesthesia was maintained with isoflurane 1% and 60% nitrous oxide. The systolic arterial blood pressure was 110 mmHg, and 1 gm of vancomycin and 80 mg of tobramycin were administered iv over 10 min. Slight wheezing was noted 5 min later with a simultaneous decrease in arterial blood pressure to 30 mmHg systolic. EKG showed multifocal PVCs. Blood was drawn for histamine determination, anesthetic agents were discontinued, and ventilation was controlled with a FI_{O_2} of 1.0. The patient was placed in the Trendelenburg position, and 100 mg of lidocaine and three 10-mg boluses of ephedrine were administered iv. EKG returned to normal sinus rhythm, but the arterial blood pressure slowly returned to 110/60 mmHg after 30 min following phenylephrine and dopamine iv infusions and 3 l of lactated Ringer's solution administration. The trachea was extubated, and the patient was transferred to the intensive care unit where a dopamine infusion and iv crystalloid administration

were required over the next 24 h to maintain a normal arterial blood pressure and urine output. The lungs were clear, but upper body angioedema required 3 days to resolve. The patient fully recovered and underwent carotid endarterectomy 7 days later without complication in the absence of antibiotic administration. The blood sample obtained during the initial hypotension revealed a histamine level of 20 ng/ml.

IN VITRO STUDIES

Sixteen foreskin tissue samples were collected from local hospitals in Dulbecco's modified eagle medium (Gibco Laboratories, Grand Island, NY), supplemented with 1% antibiotic-antimycotic solution (Gibco Laboratories).

The subcutaneous fat was excised and the tissue chopped finely with a razor blade. The cells were dispersed according to the method of Benyon *et al.*⁵ The tissue was incubated in a solution of 1.5 mg/ml collagenase (Sigma, St. Louis, MO) in 2.8 mM Ca²⁺-Hank's balanced salt solution (BSS) at 37° C with mechanical agitation for 2 h. The solution was filtered through a double layer of surgical gauze. The solution containing the dispersed cells was centrifuged at 300 \times g for 10 min. The cells were resuspended in 10 ml of Hanks-BSS-CMF and refrigerated 12–18 h. The cells were washed twice with Hanks-BSS.

The total cells recovered were resuspended in 1.0 ml BSS, to which was added 2.8 mM Ca²⁺. Cell numbers were determined on a Coulter Counter (Coulter Electronics, Hialeah, FL). Two hundred μ l aliquots of cell suspension at 10 million cells/ml (*i.e.*, 2 \times 10⁶ cells) were incubated in buffer alone for 30 min to determine spontaneous release. An equal number of cells from the same pool were incubated in buffer, to which was added

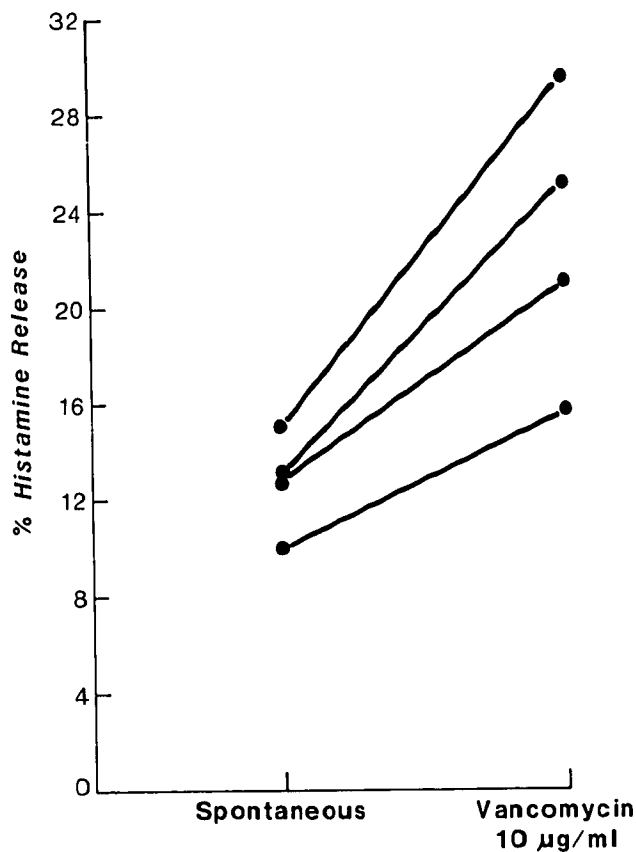


FIG. 2. Per cent histamine release from dispersed human cutaneous mast cells following the administration of vancomycin. Spontaneous release averaged $12.9 \pm 1\%$ (mean \pm SEM) and increased to $22.9 \pm 2.3\%$ ($P < .025$) following the administration of $10 \mu\text{g/ml}$ vancomycin (3×10^{-3} M).

vancomycin 3×10^{-3} M (Lilly, Indianapolis, IN) for 30 min to determine drug-induced histamine release. A similar aliquot of cells from the same pool were boiled for 10 min and sonicated to determine total histamine release. Spontaneous release was compared to vancomycin-induced release in cells obtained from the same pool by paired *t* tests, with a $P < 0.05$ level considered significant.

HISTAMINE MEASUREMENTS

Histamine was measured in the plasma of the two patients using the single isotope radioenzyme assay of Faraj,⁶ or using the double isotope radioenzyme assay of Shaff and Bevin⁷ and in the *in vitro* studies by the automated fluorometric method of Siraganian.⁸

RESULTS

Spontaneous histamine release averaged $12.9 \pm 1.0\%$ (mean \pm SEM) in the dispersed human skin cells (fig. 2).

In the cells incubated with vancomycin, histamine release increased to $22.9 \pm 2.3\%$ ($P < .025$).

DISCUSSION

Vancomycin, the only glycopeptide antibiotic in clinical use, often produces hypotension and flushing following administration in man.^{1,2} Administration of 1 gm of vancomycin in 10 ml of crystalloid over 10 min was associated with a 25–50% decrease in systolic arterial blood pressure lasting 2–3 min in 11/56 patients.⁹ In patients receiving the drug over 30 min, hypotension was not observed.⁹

Cohen *et al.* demonstrated dose-related depression of left ventricular dp/dt, right ventricular contractile force, and mean arterial blood pressure in two dogs receiving vancomycin and in the Langendorff cat heart preparation.³ In addition, they demonstrated decreased vascular resistance in the isolated dog hind limb preparation after intra-arterial injection of vancomycin. Histamine levels were not measured from either the plasma of the intact dogs or from the effluent of the isolated cat heart.³ Our study extends this work by suggesting that histamine release by vancomycin can explain their results. Although drug-induced histamine release initially causes increases in cardiac contractility, this effect is rapidly followed by a venodilatation, a sudden decrease in left ventricular filling, and decreased contractility.¹⁰ Histamine produces hypotension in man¹¹ by directly dilating peripheral blood vessels.¹²

We demonstrated histamine release in two patients following vancomycin-related hypotension. In addition, we observed increased cardiac output, increased stroke volume, and decreased systemic vascular resistance in one of these patients (fig. 1) in association with flushing. Histamine, when infused to volunteers, produces flushing, increased cardiac output, increased stroke volume, and decreased systemic vascular resistance.¹³ We also demonstrated histamine release from isolated human cutaneous mast cells following the addition of vancomycin at a concentration very close to that seen in the vascular system as the drug is being given.

Our data suggest that direct histamine release occurs following vancomycin administration. We believe histamine release probably represents the mechanism responsible for hypotension following vancomycin administration in man.

REFERENCES

1. Cook FV, Farrar WE: Vancomycin revisited. *Ann Intern Med* 88:813–818, 1978
2. Miller R, Tausk HC: Anaphylactoid reaction to vancomycin during anesthesia. A case report. *Anesth Analg* 56:870–872, 1977
3. Cohen LS, Wechsler AS, Mitchell JH, Glick G: Depression of

- cardiac function by streptomycin and other antimicrobial agents. *Am J Cardiol* 26:505-511, 1970
4. Dajee H, Laks H, Miller J, Oren R: Profound hypotension from rapid vancomycin administration during cardiac operation. *J Thorac Cardiovasc Surg* 87:145-146, 1984
 5. Benyon RC, Church MK, Clegg LS, Holgate ST: Dispersion and characterization of mast cell from human skin. *Int Arch Allergy Appl Immunol* (in press)
 6. Faraj BA, Gottlieb GR, Camp VM, Kutner M, Lollies P: Development of a sensitive radioassay of histamine for in vitro allergy testing. *J Nucl Med* 25:56-63, 1984
 7. Shaff RE, Beaven MA: Increased sensitivity of the enzymatic isotopic assay of histamine: Measurement of histamine in plasma and serum. *Anal Biochem* 94:425-430, 1979
 8. Siraganian RP: Refinements in the automated fluorometric histamine analyses system. *J Immunol Methods* 7:283-289, 1975
 9. Newfield P, Roizen MF: Hazards of rapid administration of vancomycin. *Ann Intern Med* 91:581, 1979
 10. Bristow MR, Sageman WS, Scott RH, Billingham ME, Bowden RE, Kernoff RS, Snidow GH, Daniels JE: Acute and chronic cardiovascular effects of doxorubicin in the dog: The cardiovascular pharmacology of drug-induced histamine release. *J Cardiovasc Pharmacol* 2:487-515, 1980
 11. Kaliner M, Sigler R, Summers R, Shelhamer JH: Effects of infused histamine: Analysis of the effects of H-1 and H-2 histamine receptor antagonists on cardiovascular and pulmonary responses. *J Allergy Clin Immunol* 68:365-371, 1981
 12. Owens DAA: Histamine receptors in the cardiovascular system. *Gen Pharmacol* 8:141-156, 1977
 13. Vigorito C, Russo P, Picotti GB, Chiariello M, Poto S, Marone G: Cardiovascular effects of histamine infusion in man. *J Cardiovasc Pharmacol* 5:531-537, 1983

Anesthesiology
67:125-127, 1987

Assessing the Level of Spinal Anesthesia Using a Neuromuscular Stimulator

RONALD M. MEYER, M.D.,* WILLIAM J. McCUNE, M.D.†

The response to pinprick is commonly used for defining the area of anesthesia achieved by a subarachnoid blockade (SAB). Unfortunately, there are patients who might benefit from the safety of SAB anesthetic, but are noncommunicative, making it difficult to determine accurately the level of SAB without causing trauma from vigorous needle punctures.

During 2 yr of providing anesthesia for a general hospital with a large group of nursing home patients, we have been routinely using a hand-held neuromuscular stimulator (NMS) to test the level of SAB. The stimulator has been designed to pass a short burst of current through the skin to stimulate motor nerve fibers and activate the neuromuscular junction. The device also produces the sensation of a mild electric shock at the site of application.

* Assistant Professor of Clinical Anesthesia, Northwestern University School of Medicine.

† Resident in Anesthesia, McGaw Medical Center and Northwestern University School of Medicine.

Received from the McGaw Medical Center and the Northwestern University School of Medicine, Chicago, Illinois. Accepted for publication January 30, 1987. Work was performed at Columbus Hospital, Chicago, Illinois, affiliated with the Northwestern University Medical School.

Address reprint requests to Dr. Meyer: Department of Anesthesia, Columbus Hospital, 2520 North Lakeview Avenue, Chicago, Illinois 60614.

Key words: Anesthetic technique: spinal. Monitoring: nerve; stimulator.

A prospective, non-blinded, non-randomized study was undertaken to assess the degree of correlation between SAB levels as determined by NMS, with the pinprick method as a standard for comparison. Unable to elicit useful responses to sensory examinations in non-communicative nursing home patients, we chose to study a model population of more cooperative patients.

METHODS

Fourteen consecutive, cooperative, English-speaking adult patients, who consented to receive SAB for surgical anesthesia, were examined. The male/female ratio was 4/10, and ages ranged from 19-80 yr. Surgical procedures undertaken included the obstetric (5), gynecologic (4), orthopedic (2), closed urologic (2), and general surgical (1). All SABs were injected with the patient in the lateral position using 5% lidocaine with 7.5% dextrose, or 0.5% tetracaine with 5% dextrose. Patients were then placed in the supine position. Tests of the level of SAB were performed using a sterile hypodermic needle and a "Sparkie" NMS [Dupaco, Oceanside, CA] within 1 min of each other, 5-10 min after the injection of the drug into the cerebrospinal fluid. Patients were instructed to look away from the site of sensory testing. In alternate patients, pinprick was tested first, while, in the other patients, NMS stimulation was first performed.

The patient's deltoid area was touched with the hub and then the point of the hypodermic needle, and the patient was instructed, "This is sharp. Say 'Now!' when