

Title: CONTRAST ECHOCARDIOGRAPHY - A NEW TECHNIQUE FOR INTRAOPERATIVE QUANTITATION OF MYOCARDIAL PERFUSION

Author: L.J. Segil, M.D., C. Dick, M.D., S.B. Feinstein, MD, P. Silverman

Affiliation: Dept. of Anesthesiology, Michael Reese Medical Center, Chicago, IL 60616  
Dept. of Cardiology, University of Chicago, Chicago, IL 60637

Transesophageal two-dimensional echocardiography (2DE) is now established as a sensitive tool for detecting myocardial ischemia. Contrast echocardiography (CE) uses conventional 2DE to detect enhanced ultrasound backscatter from sonicated microbubbles ( $4.5 \pm 2.3$  microns) which behave as an intravascular indicator. We have previously reported on the safety and feasibility of qualitative assessment of myocardial perfusion in humans during CABG surgery.<sup>6</sup> The current study was designed to provide a theoretical and empirical foundation for quantitation of myocardial perfusion using CE. A combination of quantitative myocardial perfusion imaging with sensitive detection of myocardial ischemia, using the same imaging technique, will eventually enable us to better understand the etiology and appropriate therapy of intraoperative ischemia.

**Methods:** We studied open chest, halothane anesthetized mongrel dogs, 20-30 kg wt, instrumented for continuous recording of cardiac output, EKG, arterial, left atrial and right atrial pressures, with a catheter in the proximal circumflex coronary artery (CCA) for drug infusion. Regional myocardial blood flow (RMBF) was measured using radiolabeled microspheres. CE was done using a commercially available unit with a 5 megahertz transducer placed on the surface of the heart. Images of the short axis of the left ventricle were recorded on videotape and later analyzed using an offline videodensitometer. 6 cc of sonicated renograffin 76, used as the echocontrast agent, was injected into the left atrium over 1/2 seconds using a programmable injector. Measurements were made with microspheres and CE under control conditions, infusion of adenosine into the CCA, and global, normocapnic hypoxia. After sacrifice, the heart was sectioned for microsphere RMBF determinations from the regions of the CCA and LAD circulation. CE videointensity curves from the LAD and CCA regions were analyzed for peak height (Hi) and curve area (Ai). Indicator dilution theory suggests that Ai for an intravascular indicator should measure regional blood volume (RMBV) and not necessarily RMBF.<sup>3</sup> This important limitation of an indicator dilution curve for an intravascular tracer has not been previously recognized in any published studies attempting to quantitate RMBF with CE.

**Results:** There were no significant hemodynamic changes as a result of CE or intracoronary adenosine. Ai correlated weakly ( $p < 0.05$ ,  $r^2 = 0.53$ ) with RMBF (fig 1). If values for Ai are grouped by intervention, adenosine increased Ai significantly less than hypoxia ( $p < 0.05$ ), although RMBF values were similar (fig. 2).

**Discussion** Our result agrees with known effects of adenosine and hypoxia on RMBF and RMBV. Hypoxia maximally recruits the myocardial capillary bed and increases RMBV and RMBF, while adenosine does not recruit capillaries and therefore increase RMBF without changing RMBV to as great an extent as hypoxia.<sup>4</sup> We therefore conclude that CE directly measures RMBV. A covariance between RMBV and RMBF is not unexpected, although they will not vary exactly under all conditions. As RMBV is an indicator of open capillary density, while RMBF is not, measurement of RMBV may prove to be very

important in the understanding of ischemia. We conclude that CE can provide a quantitative assessment of an important component of myocardial perfusion, RMBV, and will enhance our ability to study ischemia in laboratory and clinical settings.

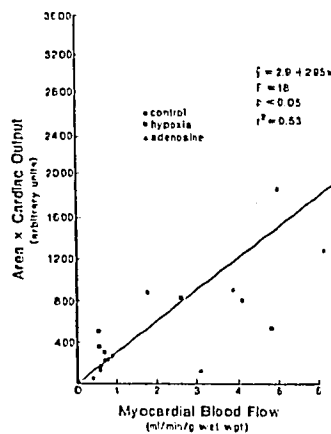


Fig. 1

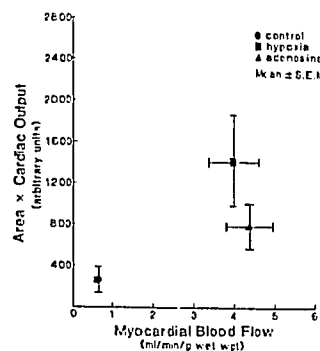


Fig. 2

#### References:

- 1) Feinstein S et al: J Physiol Imaging, 1:12-18, 1986.
- 2) Smith JS, Feinstein SB, Kapelanski D, Karp RB, Gevertz B, Keamy MF, Segil L, Borow KM, Roizen MF: Intraoperative determination of myocardial perfusion using contrast echocardiography. Anesthesiology 65:A27, 1986.
- 3) Lassen NA: Cerebral transit of an intravascular tracer may allow measurement of regional blood volume but not regional blood flow. J Cereb Blood Flow & Metab, 4:633-634, 1984.
- 4) Crystal GH, Downey HF, Bashour FA: Small vessel and total coronary blood volume during intracoronary adenosine. Am J Physiol 241:H194-H201, 1981.