

Title: INTRAOPERATIVE CARDIAC OUTPUT DETERMINATION FROM TRANSMITRAL AND PULMONARY BLOOD FLOW MEASUREMENTS USING TRANSESOPHAGEAL PULSED DOPPLER ECHOCARDIOGRAPHY

Authors: N. Roewer, M.D., F. Bednarz, M.D., A. Dziadzka, M.D., J. Schulte am Esch, M.D.

Affiliation: Department of Anesthesiology, University Hospital Eppendorf, Hamburg, West Germany

**Introduction:** Doppler ultrasound applied in either the pulsed or continuous mode, has established itself as a powerful adjunct to the conventional echocardiography in cardiac diagnosis. While Doppler ultrasound has been used mainly in the pulsed mode to measure blood flow velocities in specified locations of the heart, the M-mode or, more frequently, two-dimensional (2D) echocardiography has been employed to localize the sampling site. By combining the pulsed Doppler technique to measure blood flow velocities in a localized region of the heart or a neighboring great vessel with 2D-echocardiographic imaging to assess the diameters of vessels or valve orifices, cardiac output (CO) can be determined noninvasively.<sup>1</sup> Recently, the pulsed Doppler technique was introduced as an enhancement when integrated into the conventional transesophageal 2D-echocardiography (TEE).<sup>2,3</sup> In the present study with transesophageal pulsed Doppler echocardiography (TDE) we used transmitral and pulmonary flow measurements to determine CO during surgery and compared both methods to the thermodilution technique.

**Methods:** 27 patients (mean age 54±22 years, range 17-91 years) undergoing a variety of surgical procedures in general anaesthesia and requiring a Swan-Ganz catheter for cardiac monitoring were studied. All patients gave written informed consent and were free of valvular diseases and chronic rhythm disturbances. TDE was performed using a Hewlett Packard echo-Doppler unit (model 77020). A Doppler analysis software package integrated in the system enabled calculation of cross-sectional area, stroke volume and CO from the computer-assisted measurement of diameter, time-velocity integral and heart rate. For the transesophageal approach we used the prototype of a new, commercially available (Hewlett Packard) 5 MHz phased array transducer with 64 elements (focal zone depth 15-80 mm) fixed at the distal end of a 9.8 mm gastroscope. After insertion of the gastroscope into the esophagus of the patients, the transducer position was identified by the 2D-echo. The mitral valve flow method combined the velocity of transmitral flow at the mitral anulus with the cross-sectional area of the anulus calculated from its diameter at mid-diastole, while the pulmonary flow method combined the velocity of the pulmonary artery flow with the cross-sectional area of the vessel calculated from its diameter during early systole. These results, based on the average of 3 consecutive cycles, were compared with those derived from simultaneously performed thermodilution measurements (TD). Each CO determination represents the mean value of three single measurements.

**Results:** Flow measurements with the mitral and pulmonary methods were possible in all 27 (100%) and 16 of 27 (59,3%) patients, respectively. High-resolution 2D-echocardiograms of the mitral valve allowed accurate diameter measurements of the mitral valve orifice in all subjects, while echocardiographic imaging of the pulmonary artery for cross-sectional area determination was inadequate in 11 of 27 (40,7%) patients. A fixed intraesophageal transducer position enabled continuous transmitral and pulmonary Doppler recordings of invariable high quality. Good correlations were observed between TD-CO and TDE-CO for both the mitral anulus method (fig. 1) and the pulmonary method (fig. 2). The regression equations indicated no significant over- or underestimation of TD-CO by both Doppler methods.

**Discussion:** This study shows that intraoperative cardiac output determinations obtained with the relatively noninvasive TDE technique are as reliable as the thermodilution measurements. Both the mitral valve and the pulmonary artery provide optimal sites for continuous TDE measurements of high quality due to the short

distance between esophageal transducer and these areas and the parallel alignment between the ultrasonic beam and blood stream. The mitral method offers conditions optimal for routine use of the technique due to the prompt and accurate echocardiographic imaging of the mitral valve in all patients, while the pulmonary method is limited in its routine clinical application since the transesophageal images needed for the cross-sectional area determination are only adequate in about 50% of the patients. Because this new technique enables prompt and simple CO determinations it may increase the value of TEE to clinicians in the perioperative period.

**References:**

1. Lewis JF, Kuo LC, Nelson JG, Limacher MC, Quinones MA: Pulsed Doppler echocardiographic determination of stroke volume and cardiac output: clinical validation of two new methods using the apical window. *Circulation* 70:425, 1984
2. Roewer N, Langenstein B, Hanrath P, Schulte am Esch J: Transesophageal pulsed Doppler echocardiography: Initial clinical experience with the new technique for the continuous measurement of cardiac and pulmonary blood flow velocities. *Beitr Anästhes Intensivmed* 18: 214, 1986
3. Langenstein B, Roewer N, Schulte am Esch J, Hanrath P: Cardiac output measurement by transesophageal pulsed Doppler echocardiography. *Circulation* 74 (Suppl II):710, 1986

Figure 1

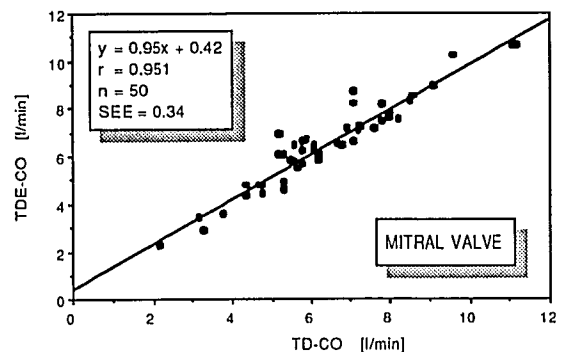
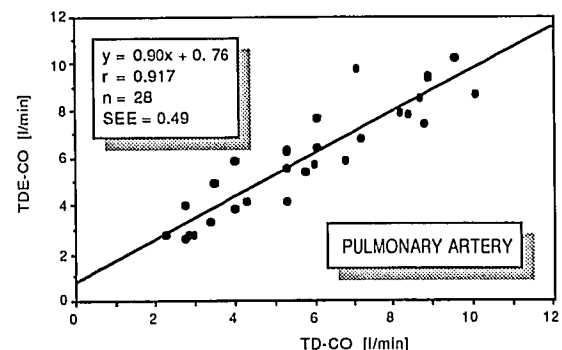


Figure 2



Supported by the B. Braun-Foundation, Melsungen, West Germany